



The American College of
Obstetricians and Gynecologists
WOMEN'S HEALTH CARE PHYSICIANS



Pelvic Organ Prolapse

The American College of Obstetricians and Gynecologists and the American Urogynecologic Society

INTERIM UPDATE: This Practice Bulletin is updated as highlighted to reflect the US Food and Drug Administration order to stop the sale of transvaginal synthetic mesh products for the repair of pelvic organ prolapse.

Abstract: Pelvic organ prolapse (POP) is a common, benign condition in women. For many women, it can cause vaginal bulge and pressure, voiding dysfunction, defecatory dysfunction, and sexual dysfunction, which may adversely affect quality of life. Women in the United States have a 13% lifetime risk of undergoing surgery for POP¹. Although POP can occur in younger women, the peak incidence of POP symptoms is in women aged 70 to 79 years². Given the aging population in the United States, it is anticipated that by 2050 the number of women experiencing POP will increase by approximately 50%³. The purpose of this joint document of the American College of Obstetricians and Gynecologists and the American Urogynecologic Society is to review information on the current understanding of POP in women and to outline guidelines for diagnosis and management that are consistent with the best available scientific evidence.

Key Words: American Urogynecologic Society, guidelines, pelvic organ prolapse

(*Female Pelvic Med Reconstr Surg* 2019;25:397–408)

Background

Definition

Pelvic organ prolapse is the descent of 1 or more aspects of the vagina and uterus: the anterior vaginal wall, posterior vaginal wall, the uterus (cervix), or the apex of the vagina (vaginal vault or cuff scar after hysterectomy).⁴ This allows nearby organs to herniate into the vaginal space, which is commonly referred to as cystocele, rectocele, or enterocele. Mild descent of the pelvic organs is common and should not be considered pathologic. Pelvic organ prolapse should only be considered a problem if it is

causing prolapse symptoms (ie, pressure with or without a bulge) or sexual dysfunction or if it is disrupting normal lower urinary tract or bowel function. Pelvic organ prolapse can be defined using patient-reported symptoms or physical examination findings (ie, vaginal bulge protruding to or beyond the hymen). Most women feel symptoms of POP when the leading edge reaches 0.5 cm distal to the hymenal ring.⁵

Epidemiology

According to the National Health and Nutrition Examination Survey, approximately 3% of women in the United States report symptoms of vaginal bulging.³ In 1 review, the prevalence of POP based on reported symptoms was much lower (3%–6%) than the prevalence identified by examination (41%–50%).⁶ This discrepancy likely occurs because many women with POP are asymptomatic. Pelvic organ prolapse usually is due to global pelvic floor dysfunction, so most women will present with POP in multiple compartments (anterior, apical, and posterior vaginal wall).⁷

There are few studies of the natural history of POP. In one study that monitored women with symptomatic, untreated POP for an average of 16 months, 78% of the women had no change in the leading edge of the prolapse.⁸ Most of the women had stage II–IV POP (Box 1). In women who do not want treatment for their POP, most will have no change or only a small increase in the size of the POP over the next year.⁹

The incidence of POP surgery is 1.5 to 1.8 surgeries per 1000 women-years.^{10,11} There are approximately 300,000 POP surgeries each year in the United States.¹²

Risk Factors

Risk factors for developing symptomatic POP include parity, vaginal delivery, age, obesity, connective tissue disorders, menopausal status, and chronic constipation.^{13–17} Modifiable risk factors (obesity and constipation) should be addressed in patients at wellness visits because improvement in these factors may reduce the risk of developing POP.

It is not clear if hysterectomy for non-POP conditions is a risk factor for developing POP. In a subanalysis of a cohort study from the United Kingdom, patients who underwent a hysterectomy had a 5% cumulative risk of undergoing prolapse surgery within the next 15 years.¹³ A more recent study found no increased risk of POP in women who underwent prior hysterectomy for non-POP indications.¹⁸

Older studies reported that women who underwent primary POP surgery had an approximate 30% to 50% chance of needing a second prolapse surgery.¹⁹ More recent studies show a lower reoperation rate of approximately 6% to 30%, with most estimates consistent with the lower end of this range.^{19–22} This lower reoperation rate may reflect improvement in surgical technique as well

From the American Urogynecologic Society, Silver Spring, MD.
(Replaces Practice Bulletin Number 185, November 2017).
Committee on Practice Bulletins—Gynecology.

American Urogynecologic Society.
This Practice Bulletin was developed by the Committee on Practice
Bulletins—Gynecology and the American Urogynecologic Society in
collaboration with Paul Tullikangas, MD.

Published online on October 24, 2019.
Requests for authorization to make photocopies should be directed to Copyright
Clearance Center, 222 Rosewood Dr, Danvers, MA 01923 [(978)
750-8400].

American College of Obstetricians and Gynecologists, 409 12th St, SW, PO
Box 96920, Washington, DC 20090.
Pelvic organ prolapse. ACOG Practice Bulletin No. 214. American College of
Obstetricians and Gynecologists. *Obstet Gynecol* 2019;134:e126–42.

(Literature search dates: January 2000–October 2016).
Copyright © 2019 by the American College of Obstetricians and Gynecologists.
All rights reserved. No part of this publication may be reproduced, stored in
a retrieval system, posted on the Internet, or transmitted, in any form or by
any means, electronic, mechanical, photocopying, recording, or otherwise,
without prior written permission from the publisher.
DOI: 10.1097/SPV.0000000000000794

BOX 1. Stages of Pelvic Organ Prolapse.**Stages are based on the maximal extent of prolapse relative to the hymen, in one or more compartments.**

Stage 0: No prolapse; anterior and posterior points are all -3 cm, and C or D is between $-TVL$ and $-(TVL - 2)$ cm.

Stage I: The criteria for stage 0 are not met, and the most distal prolapse is more than 1 cm above the level of the hymen (less than -1 cm).

Stage II: The most distal prolapse is between 1 cm above and 1 cm below the hymen (at least one point is -1 , 0 , or $+1$).

Stage III: The most distal prolapse is more than 1 cm below the hymen but no further than 2 cm less than TVL.

Stage IV: Represents complete procidentia or vault eversion; the most distal prolapse protrudes to at least $(TVL - 2)$ cm.

Abbreviations: C, cervix; D, posterior fornix; TVL, total vaginal length. Data from Bump et al.²⁸

as stratification of urinary incontinence as a separate risk in the outcomes data.¹⁹ Pelvic organ prolapse surgery that includes suspension of the vaginal apex is associated with a decreased reoperation rate.²³ Risk factors for recurrent prolapse include age younger than 60 years for patients who underwent vaginal surgery for POP, obesity, and preoperative stage III or stage IV prolapse.²⁴⁻²⁶

Clinical Considerations and Recommendations

What is the recommended initial evaluation for a woman with suspected POP?

The recommended initial evaluation for a woman with suspected POP includes a thorough history, assessment of symptom severity, physical examination, and goals for treatment. Symptom assessment is the most important part of the evaluation of a woman with POP.

History

In addition to a complete medical, surgical, obstetric, and gynecologic history, the nature of vaginal bulge symptoms and the degree of bother associated with the bulge should be recorded. Key information to elicit from the patient includes whether the protrusion is limiting physical activities or sexual function or becoming progressively worse or bothersome. Many women with POP on physical examination do not report symptoms of POP. Treatment is indicated only if prolapse is causing bothersome bulge and pressure symptoms, sexual dysfunction, lower urinary tract dysfunction, or defecatory dysfunction.²⁷

Lower urinary tract function should be assessed. This includes an evaluation for urine loss and type (stress or urgency urinary incontinence) and adequacy of bladder emptying. The relationship between urinary symptoms and prolapse can be inferred if voiding becomes more difficult when the effects of gravity are more pronounced, such as after long periods of standing.⁴ In addition, splinting (ie, the need to push on or support the bulging tissue) may be required to initiate or complete voiding.

Assessment of bowel function should be undertaken to determine if there is a history of straining with bowel movements, laxative use, fecal incontinence, and incomplete rectal emptying. The symptom of splinting often is correlated with the presence of a posterior compartment defect (eg, rectocele). Each patient should be assessed for symptoms of dyspareunia, coital incontinence (of urine or stool), and sexual dysfunction that is related to the prolapse.

Physical Examination

Physical examination should include an abdominal and pelvic examination to rule out pelvic masses. The external genitalia

and vaginal epithelium should be evaluated for vaginal atrophy, skin irritation, or ulceration.²⁷ Simply spreading the labia while examining the patient in a supine position can be helpful to assess the maximum descent of the prolapse. A detailed examination of the POP should be performed with a split speculum (ie, separate a bivalve speculum and use only the posterior blade to examine the apex and anterior vaginal wall and then turn the blade over and use it to hold the anterior wall while examining the postvaginal wall and perineal body as the patient performs the Valsalva maneuver, repetitive coughing, or both). Performance of a Pelvic Organ Prolapse Quantification (POP-Q) examination is recommended before treatment for the objective evaluation and documentation of the extent of prolapse (see *Is the POP-Q examination necessary before treatment for POP?*) If a patient's prolapse symptoms are not confirmed by the extent of prolapse observed during supine pelvic examination, repeating the pelvic examination in the standing position may reveal the greatest descent of POP.

Pelvic floor muscle tone should be assessed.²⁷ It should be noted if the pelvic floor muscles can contract and relax voluntarily. The strength of the contraction should be described as "absent," "weak," "normal," or "strong."⁴

Is additional testing beyond history and physical examination needed to evaluate women with POP?

In general, no additional testing beyond a complete gynecologic, urologic, and defecatory history and physical examination is needed before treatment. However, if the prolapse is beyond the hymen or the patient has voiding symptoms, a postvoid residual urine volume should be recorded either with a catheter or ultrasonography.²⁷ If there is urinary urgency or other lower urinary tract symptoms, minimum assessment involves a urinalysis, with culture and microscopy performed if indicated. Urodynamic testing may help inform patient counseling and may be considered if there is bothersome incontinence with stage II or greater prolapse or voiding dysfunction. If findings on initial assessment do not concur with symptoms, more specific imaging or referral to a specialist in urogynecologic care may be needed.

Is the POP-Q examination necessary before treatment of POP?

A POP-Q examination is recommended before treatment of POP to objectively evaluate and document the extent of prolapse. Evaluation and documentation of the extent of the prolapse are important before treatment so that the surgeon has a preoperative comparator by which to measure postoperative anatomic success. The POP-Q system is the only validated method for objective measurement of prolapse in the 3 pelvic compartments: (1) anterior, (2) apical, and (3) posterior (Fig. 1).²⁸⁻³⁰ The POP-Q system is recommended by the major national and international urogynecologic health organizations, including the American Urogynecologic Society, the Society of Gynecologic Surgeons, and the International Continence Society.³¹ In addition, POP-Q is used in most scientific publications on POP.³² Although the Baden-Walker system clinically describes prolapse findings, the POP-Q system is more precise and has been shown to be reproducible.

The POP-Q system does not use the terms "cystocele" and "rectocele" but instead uses terms for each "prolapsed segment" because the exact organ that lies behind the prolapsed vaginal epithelium may not be clear from the clinical examination. It incorporates measurements of the vaginal length, genital hiatus, and perineal body. The POP-Q measurements can be converted to stages based on the most severely prolapsed vaginal segment (Box 1).²⁸

A validated examination allows for consistency in reporting and facilitates communication between gynecologic care providers. It is particularly important if a patient has a recurrent prolapse because it will allow a new gynecologic care provider to

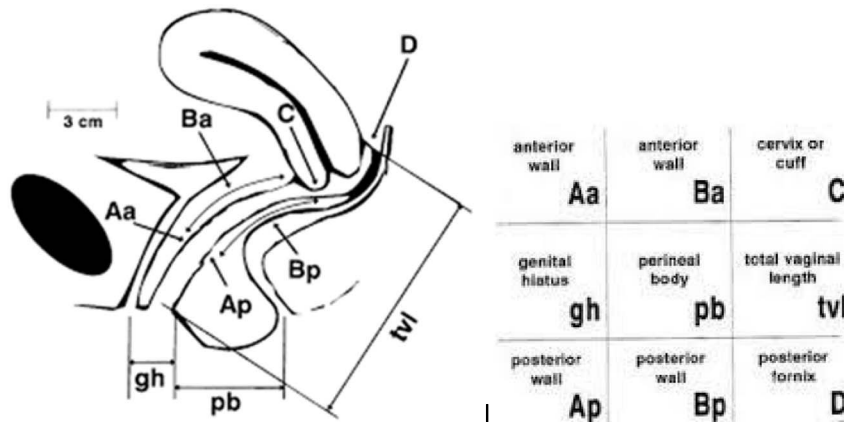


FIGURE 1. Pelvic Organ Prolapse Quantification system. Nine defined points measured in the midline and relative to the hymen assessed during maximal Valsalva except for TVL: Aa, 3 cm proximal to the external urethral meatus; Ba, most prolapsed portion of the anterior vaginal wall; C, leading edge of the cervix or vaginal cuff; gh, middle of the urethral meatus to the midline of the posterior hymen; pb, middle of the posterior hymen to the middle of the anal opening; tvl, maximum depth of the vagina with prolapse reduced; Ap, 3 cm proximal to the posterior hymen; Bp, most prolapsed portion of the posterior vaginal wall; D, posterior fornix in a woman who has a cervix. Reprinted with permission from Bump et al.²⁸

understand the patient’s POP history. Outcomes can be evaluated only if pretreatment POP measurements are recorded accurately.

For patients desiring expectant management, documentation of the prolapse with the POP-Q allows an objective, validated, baseline measurement that can be referred to if symptoms change over time. Although recording a POP-Q examination is not necessary for these patients, it may be helpful to determine if there is an anatomic change over time.

Are effective nonsurgical treatments available for women with POP?

For women with asymptomatic prolapse, education and reassurance are appropriate. Women may not realize that symptoms of voiding or defecatory dysfunction are related to prolapse, so education about how prolapse symptoms manifest can be helpful.

Some symptoms related to POP may be managed with lifestyle modifications. For example, defecatory dysfunction may improve with fiber supplementation and use of an osmotic laxative.³³ Sitting with feet elevated may decrease bulge symptoms. Pelvic muscle exercises, performed either independently or under professional supervision, may improve symptoms or slow the progression of POP.^{34,35}

There is limited evidence for the treatment or prevention of POP with local or systemic estrogen.³⁶ However, some clinicians believe that local estrogen may help with the vaginal irritation associated with POP.

Women considering treatment of POP should be offered a vaginal pessary as an alternative to surgery. A pessary should be considered for a woman with symptomatic POP who wishes to become pregnant in the future. A vaginal pessary is an effective nonsurgical treatment for women with POP, and up to 92% of women can be fitted successfully with a pessary.³⁷ In a study protocol, a ring pessary was inserted first, followed by a Gellhorn pessary if the ring did not stay in place. Ring pessaries were used more successfully with stage II (100%) and stage III (71%) prolapse, and stage IV prolapse more frequently required Gellhorn pessaries (64%).³⁸ If possible, women should be taught to change their pessaries independently. If a woman is unable to remove and replace her pessary, regular follow-up (such as every 3–4 months) is necessary. Annual follow-up is recommended for patients who are able to maintain pessary hygiene on their own.

Pressure on the vaginal wall from the pessary may result in local devascularization or erosion in 2% to 9% of patients.³⁹

Therapy should consist of removing the pessary for 2 to 4 weeks and local estrogen therapy. Resolution may occur without local estrogen therapy. If the problems persist, more frequent pessary changes or a different pessary may be required.³⁹ Caregivers to patients with dementia should be made aware of the regular pessary changes needed to avoid complications. Although rare complications such as fistula can occur, pessary use is a low-risk intervention that can be offered to all women who are considering treatment of POP.⁴⁰

When is surgery indicated for the management of POP, and what are the primary approaches?

Surgery is indicated for the treatment of POP in women who are bothered by their POP and have failed or declined nonsurgical treatments. There are various vaginal and abdominal surgical approaches for the treatment of POP (Table 1). Important considerations for deciding the type and route of surgery include the location and severity of prolapse, the nature of the symptoms (eg, presence of urinary, bowel, or sexual dysfunction), the patient’s general health, patient preference, and the surgeon’s expertise.⁴¹

Are vaginal surgical approaches effective for the management of POP?

Vaginal hysterectomy and vaginal apex suspension with vaginal repair of anterior and posterior vaginal wall prolapse as needed are effective treatments for most women with uterovaginal and anterior and posterior vaginal wall prolapse.^{21,22,42,43} Vaginal native tissue repairs are performed without the use of synthetic mesh or graft materials. These are relatively low-risk surgeries that may be considered as surgical options for most women with primary POP.

If a patient has uterine prolapse, vaginal hysterectomy alone is not adequate treatment. Vaginal apex suspension should be performed at the time of hysterectomy for uterine prolapse to reduce the risk of recurrent POP.^{23,44} Vaginal apex suspension involves attachment of the vaginal apex to the uterosacral ligaments or sacrospinous ligaments. Uterosacral ligament suspension and sacrospinous ligament suspension for apical POP with native tissue are equally effective surgical treatments of POP, with comparable anatomic, functional, and adverse outcomes.²¹ In the Operations and Pelvic Muscle Training in the Management of Apical Support Loss trial, the 2-year follow-up surgical success rate was 64.5% for uterosacral ligament suspension compared with 63.1% for sacrospinous ligament fixation (adjusted odds

TABLE 1. Types of POP Surgery

Surgical Technique	Aim	Indication
Abdominal sacral colpopexy	To correct upper vaginal prolapse	Most commonly used in women with recurrent cystocele, vault, or enterocele
Uterosacral ligament suspension	To correct upper vaginal prolapse	Performed at the time of hysterectomy or in patients with posthysterectomy vaginal vault prolapse
Sacrospinous fixation	To correct upper vaginal prolapse	Performed at the time of hysterectomy or in patients with posthysterectomy vaginal vault prolapse
Anterior vaginal repair (anterior colporrhaphy)	To correct anterior wall prolapse	May be used for the treatment of prolapse of the bladder or urethra (bladder, urethra, or both, herniates downward into the vagina)
Posterior vaginal repair (posterior colporrhaphy) and perineorrhaphy	To correct posterior wall prolapse	May be used for the treatment of rectocele (rectum bulges or herniates forward into the vagina), defects of the perineum, or both
Vaginal repair with synthetic mesh or biologic graft augmentation	To correct anterior wall prolapse, apical vaginal prolapse, or both	Depending on the specific defect, the mesh augmentation can either be anterior, apical, or both. This repair is not routinely recommended

Adapted from Maher et al.⁴¹

ratio [OR], 1.1; 95% confidence interval [CI], 0.7–1.7).²¹ The serious adverse event rate at 2-year follow-up was 16.5% for uterosacral ligament suspension compared with 16.7% for sacrospinous ligament fixation (adjusted OR, 0.9; 95% CI, 0.5–1.6).²¹ Uterosacral ligament suspension can be performed by attaching the vaginal apex bilaterally to the ipsilateral uterosacral ligament or by attaching the vaginal apex to uterosacral ligament complex that is plicated in the midline.^{42,43,45} It is important that an adequate segment of uterosacral ligament is secured to the vagina. This often requires attachment to the midportion of the uterosacral ligament close to the ischial spine. Alternatively, the sacrospinous ligament can be used to support the vaginal apex. A unilateral right sacrospinous ligament fixation usually is used for the attachment point to avoid dissection around the colon.⁴⁶

Anterior colporrhaphy is an effective treatment for most anterior vaginal wall prolapse.⁴⁷ Many women with anterior vaginal wall prolapse also have an apical prolapse.⁴⁸ In these women, surgery should correct the apical prolapse and the anterior vaginal wall prolapse. Resupport of the vaginal apex concurrently with repair of the anterior vaginal wall defect reduces the risk of recurrent POP surgery.²³ Paravaginal defects are lateral detachments of the vaginal wall from the fascial condensations over the levator ani muscles.^{49,50} Diagnosis of paravaginal defects by physical examination is unreliable.^{51,52} Moreover, if a paravaginal defect is suspected, there usually is apical loss of support.⁵⁰ Apical support procedures may address most anterior vaginal wall defects, including paravaginal defects.⁵³

Posterior vaginal wall repair traditionally has been performed through a midline plication of the posterior vaginal wall fibromuscular connective tissue.⁵⁴ The repair should be performed without placing tension on the levator ani muscles because this may lead to dyspareunia.⁵⁵ Perineorrhaphy that results in reattachment of the perineal muscles to the rectovaginal septum can be performed as needed if a perineal defect is present. An alternative technique for performing posterior vaginal wall repair is site-specific repair, which involves dissection of the vaginal epithelium off the underlying fibromuscular connective tissue and repair of localized tissue defects with sutures. A finger often is placed in the rectum and directed anteriorly to identify various tissue defects of the posterior vaginal wall.⁵⁶ Although a retrospective comparison

of site-specific repair and midline colporrhaphy found that site-specific repair was associated with a higher rate of recurrence of a symptomatic bulge (11% vs 4%, $P = 0.02$),⁵⁷ a prospective study showed comparable outcomes for the 2 techniques.³⁸

When is abdominal sacrocolpopexy indicated for the management of POP?

Abdominal sacrocolpopexy is a proven and effective surgery for the treatment of POP.^{20,59} This procedure involves placement of a synthetic mesh or biologic graft from the apex of the vagina to the anterior longitudinal ligament of the sacrum. Women who may be candidates for abdominal sacrocolpopexy include those who have a shortened vaginal length, intra-abdominal pathology, or risk factors for recurrent POP (eg, age < 60 years, stage 3 or 4 prolapse, and body mass index > 26 kg/m²).^{24–26} In women who are at increased risk of synthetic mesh-related complications (eg, chronic steroid use, current smoker), sacrocolpopexy with a biologic graft or alternatives to a sacrocolpopexy could be considered.

Studies evaluating abdominal sacrocolpopexy with biologic grafts show conflicting results. Abdominal sacrocolpopexy with porcine dermis xenograft had efficacy similar to that of abdominal sacrocolpopexy with synthetic polypropylene mesh. However, the porcine dermal xenograft used in this study is no longer available.⁶⁰ In a study that evaluated the 5-year surgical outcomes of abdominal sacrocolpopexy among patients randomized to receive polypropylene mesh or cadaveric fascia lata, use of synthetic mesh resulted in better anatomic cure than use of cadaveric fascia lata grafts (93% [27 of 29] vs 62% [18 of 29], $P = 0.02$).⁶¹

Abdominal sacrocolpopexy with synthetic mesh has a lower risk of recurrent POP but is associated with more complications than vaginal apex repair with native tissue. Data from randomized controlled trials also show a significantly greater likelihood of anatomic success with mesh abdominal sacrocolpopexy compared with vaginal apex repair with native tissue (pooled OR, 2.04; 95% CI, 1.12–3.72).⁶² Surgical complications that are more common after abdominal sacrocolpopexy with mesh include ileus or small-bowel obstruction (2.7% vs 0.2%, $P < 0.01$), thromboembolic phenomena (0.6% vs 0.1%, $P = 0.03$), and mesh or suture complications (4.2% vs 0.04%, $P < 0.01$).⁶² In addition, sacrocolpopexy with mesh is associated with a significant reoperation rate due to mesh-related complications. Long-term (ie, 7-year) follow-up of participants of the Colpopexy

and Urinary Reduction Efforts (CARE) trial found that the estimated rate of mesh complications (erosion into the vagina, visceral erosions, and sacral osteitis) was 10.5% (95% CI, 6.8%–16.1%), with a significant number of reoperations.²⁰ Many of the CARE trial sacrocolpopexies, however, were performed with non-type 1 mesh, which may have increased the mesh complication rate. Because of complications attributed to multifilament and small-pore-size synthetic mesh, type 1 synthetic meshes (monofilament with large pore size) currently are used in the United States.

Do patients benefit from a minimally invasive approach to POP surgery?

Sacrocolpopexy with or without supracervical hysterectomy or total hysterectomy can be performed laparoscopically with or without robotic assistance.⁶³ Although open abdominal sacrocolpopexy is associated with shorter operative times (222 vs 296 minutes; $P < 0.02$), minimally invasive sacrocolpopexy is associated with less blood loss (122 ± 146 vs 187 ± 142 mL; $P < 0.01$) and shorter hospitalization (1.3 ± 1 vs 2.9 ± 1.6 days; $P < 0.01$).⁶⁴ Similar results were seen in a randomized controlled trial that compared open abdominal sacrocolpopexy with laparoscopic sacrocolpopexy, in which mean blood loss was significantly greater in the open arm (mean difference [MD], 184 mL; 95% CI, 96–272 mL), and there were fewer inpatient days in the laparoscopic group (MD, 0.9 days; 95% CI, 0.1–1.7 days).⁶⁵

Although robotic assistance shortens the learning curve for performing laparoscopic sacrocolpopexy and improves surgeon ergonomics,^{66–68} it has not been shown to improve short-term outcomes for patients.^{69–72} In 2 randomized controlled trials that compared robot-assisted sacrocolpopexy with laparoscopic sacrocolpopexy, operating time, postoperative pain, and cost were found to be significantly greater in the robot-assisted group.^{69,72} The groups had similar anatomic and functional outcomes 6 months to 1 year after surgery, although the robotic experience of the surgeons was low at the start of the study, which may have affected the results.⁷³ Overall, the current literature is too scant to adequately indicate which minimally invasive approach should be recommended. Further comparative studies that assess long-term anatomic and functional outcomes and patient safety and that identify subgroups of patients who would benefit from a robotic approach are warranted.⁷⁴

Is posterior vaginal wall prolapse repair more effective with a transanal or transvaginal incision?

Posterior vaginal wall prolapse repair is more effective when performed through a transvaginal incision than a transanal incision. Systematic review findings show that, compared with transanal incision, posterior vaginal repair results in fewer recurrent prolapse symptoms (relative risk [RR], 0.4; 95% CI, 0.2–1.0), lower recurrence on clinical examination (RR, 0.2; 95% CI, 0.1–0.6), and a smaller mean depth of rectocele on postoperative defecography (MD, -1.2 cm; 95% CI, -2.0 to -0.3).⁷⁵

Are surgical approaches available to treat POP in women with medical comorbidities?

Obliterative procedures—which narrow, shorten, or completely close the vagina—are effective for the treatment of POP and should be considered a first-line surgical treatment for women with significant medical comorbidities who do not desire future vaginal intercourse or vaginal preservation.^{76–79} Obliterative procedures have high reported rates of objective and subjective improvement of POP (98% and 90%, respectively)⁸⁰ and are associated with a low risk of recurrent POP.^{76,80,81} Because obliterative surgical procedures can be performed under local or regional anesthesia, these procedures may be especially beneficial for the treatment of POP in women with significant medical comorbidities that preclude general anesthesia or prolonged surgery, such as cardiac

disease, chronic obstructive pulmonary disease, or thromboembolic disease. In addition, obliterative procedures for the treatment of POP are associated with low rates of complications, intensive care unit admissions, and mortality (6.8%, 2.8%, and 0.15%, respectively).⁸² Patients undergoing obliterative procedures must be committed to no longer having vaginal sexual intercourse. In a multisite prospective study of older women (mean age, 79 years) who underwent obliterative repair of POP, 95% of patients (125 of 132) reported being satisfied or very satisfied with the results of the procedure 1 year after surgery.⁷⁹ Patient regret also has been reported to be low. Among women interviewed more than 1 year after obliterative prolapse repair, only 9% (3 of 32) reported they regretted having the procedure.⁸¹

Common types of obliterative surgical repair of POP include a Le Fort–style partial colpocleisis and total colpocleisis. Le Fort partial colpocleisis is performed when the uterus is preserved at the time of prolapse repair. This procedure involves denuding a strip of epithelium from the anterior and posterior vaginal walls and then suturing them together.⁸³ This leaves lateral canals to drain the secretions from the cervix. Because the uterus is difficult to access postoperatively, normal results from cervical cytology and human papillomavirus testing and an endometrial evaluation usually are documented before surgery. For posthysterectomy vaginal prolapse, a colectomy or tight anterior and posterior colporrhaphy creating a constricted vagina is a surgical option if a patient is amenable to an obliterative procedure. In total colpocleisis procedures, the entire vaginal epithelium is denuded, and sutures are used to invert the vagina.⁸³ With any obliterative procedure, a suburethral plication or midurethral sling and a perineorrhaphy often are recommended to decrease the risk of postoperative stress urinary incontinence and recurrent posterior vaginal wall prolapse.⁸⁰

What can be recommended regarding currently available synthetic mesh and biologic graft materials for use in vaginal POP surgery?

Availability of Transvaginal Synthetic Mesh

There are currently no available US Food and Drug Administration (FDA)–approved transvaginal mesh products for the treatment of POP. Many transvaginal mesh products were removed from the market after the 2011 FDA announcement that identified serious safety and effectiveness concerns about the use of transvaginal mesh to treat POP.⁸⁴ In April 2019, the FDA ordered the manufacturers of all remaining surgical mesh products indicated for the transvaginal repair of POP to stop selling and distributing their products in the United States.⁸⁵ The FDA determined that the manufacturers' premarket approval applications—a requirement since the device's 2016 reclassification as “high risk”⁸⁶—had failed to demonstrate an acceptable long-term benefit-risk profile for surgery with these devices compared with transvaginal native tissue prolapse repair. It is important to note that the FDA announcement applies only to mesh placed transvaginally to treat POP. The FDA order does not apply to transvaginal mesh for stress urinary incontinence or transabdominal mesh for POP repair.

The FDA advises that no intervention is needed for patients who received transvaginal mesh for the surgical repair of POP and are not experiencing any symptoms or complications.⁸⁵ These patients should be counseled to continue with routine care and report any complications or symptoms, including persistent vaginal bleeding or discharge, pelvic pain, or dyspareunia, to their gynecologic care provider. For more information, see Committee Opinion No. 694, *Management of Mesh and Graft Complications in Gynecologic Surgery*.⁸⁷

Although the 2019 FDA announcement stopped the sale of available transvaginal mesh POP repair products, some surgeons might still offer transvaginal mesh-augmented surgery for select patients with anterior and apical POP. Pelvic organ prolapse vaginal mesh repair should be limited to high-risk individuals in whom the benefit of mesh placement may justify the risk, such as individuals with recurrent prolapse (particularly of the anterior or apical compartments) or with medical comorbidities that preclude more invasive and lengthier open and endoscopic procedures. Before placement of synthetic mesh grafts in the anterior vaginal wall, patients should provide their informed consent after reviewing the benefits and risks of the procedure and discussing alternative repairs.

Vaginal Prolapse Repair With Transvaginal Mesh or Biologic Grafts

The use of synthetic mesh or biologic grafts in POP surgery is associated with unique complications not seen in POP repair with native tissue. A systematic review of 7 randomized controlled trials that compared native tissue repair with synthetic mesh vaginal prolapse repair found that more women in the mesh group required repeat surgery for the combined outcome of prolapse, stress incontinence, or mesh exposure (RR, 2.40; 95% CI, 1.51–3.81).⁴¹ The rate of mesh exposure was 12%, and 8% of women required repeat surgery for mesh exposure up to 3 years after the initial surgery.⁴¹ Systematic review findings show that vaginal repair of prolapse with biologic grafts (tissue from human cadaver or other species) results in similar rates of “awareness of prolapse” and reoperation for prolapse compared with repairs using native tissue.⁴¹ However, it is difficult to make an overall recommendation about the use of biologic grafts for vaginal prolapse repair because the available evidence is of low quality, and most of the biologic grafts that were used in studies to date are no longer available.

Posterior Vaginal Repair

The use of synthetic mesh or biologic grafts in transvaginal repair of posterior vaginal wall prolapse does not improve outcomes.⁴¹ In addition, there are increased complications (eg, mesh exposure) associated with placement of mesh through a posterior vaginal wall incision.⁵⁴ In 2 randomized trials that compared native tissue with biologic graft material for the repair of posterior prolapse, the objective failure rate was significantly lower at the 1-year follow-up in the native tissue group (10% [10 of 98]) as compared with the biologic graft group (21% [20 of 93]) (RR, 0.47; 95% CI, 0.24–0.94), and the subjective failure rate was similar between the groups (RR, 1.09; 95% CI, 0.45–2.62).^{58,75,88} There was no difference in the rate of postoperative dyspareunia between the groups (RR, 1.26; 95% CI, 0.59–2.68). Another trial that compared posterior biologic graft repair with traditional repair noted worse anatomic outcomes with posterior biologic graft repair than with traditional repair (46% vs 14%; $P = 0.02$).^{20,58} Thus, synthetic mesh or biologic grafts should not be placed routinely through posterior vaginal wall incisions to correct POP for primary repair of posterior vaginal wall prolapse.

Anterior Vaginal Repair

The use of biologic grafts in transvaginal repair of anterior vaginal wall prolapse provides minimal benefit compared with native tissue repair.⁸⁹ Systematic review results indicate that native tissue and biologic graft-augmented anterior repairs result in similar rates of prolapse awareness (RR, 0.98; 95% CI, 0.52–1.82) and risk of repeat surgery (RR, 1.02; 95% CI, 0.53–1.97).⁸⁹ Native tissue anterior repair appears to have an increased risk

of anterior prolapse recurrence when compared with repair using any type of biologic graft (RR, 1.32; 95% CI, 1.06–1.65). However, subanalysis by biologic graft type showed no significant difference in recurrence risk between native tissue and porcine dermis graft (RR, 1.29; 95% CI, 0.98–1.70), which was the most commonly used graft among the included studies.⁸⁹

Compared with native tissue anterior repair, polypropylene mesh augmentation of anterior vaginal wall prolapse repair improves anatomic and some subjective outcomes but is associated with increased morbidity.⁸⁹ Vaginally placed polypropylene mesh is associated with longer operating times and greater blood loss compared with native tissue anterior repair.^{89,90} In addition, the use of vaginally placed polypropylene mesh is associated with an increased risk of repeat surgery for prolapse, stress urinary incontinence, and mesh exposure (composite outcome).⁸⁹

Is special training required to perform POP procedures that use mesh or biologic grafts?

Surgeons who perform POP surgery with biologic grafts or synthetic mesh grafts should have training specifically for these procedures and should be able to counsel patients regarding the risk-benefit ratio for the use of mesh compared with native tissue repair. There are unique risks and complications associated with the use of mesh in surgeries to treat POP. Special training regarding patient selection, anatomy, surgical technique, postoperative care, and management of complications is necessary for physicians who perform POP surgery using mesh or biologic grafts.^{84,90,91} The American Urogynecologic Society has published guidelines for training and privileging for the performance of abdominal sacrocolpopexy and vaginal mesh prolapse surgery.^{92,93}

Is it necessary to perform intraoperative cystoscopy during POP surgery?

Routine intraoperative cystoscopy during POP surgery is recommended when the surgical procedure performed is associated with a significant risk of injury to the bladder or ureter. These procedures include suspension of the vaginal apex to the uterosacral ligaments, sacrocolpopexy, and anterior colporrhaphy and the placement of mesh in the anterior and apical compartments.^{94,95}

Intraoperative cystoscopy is performed after completion of POP repair while the patient is still under anesthesia and should include a complete survey of the bladder and assessment of efflux of urine from the ureteral orifices. Identified issues such as no flow or reduced flow from the ureter or an injury to the bladder should be addressed intraoperatively. Delay in recognition of a urinary tract injury may lead to increased morbidity.⁹⁶

Are there effective POP surgical treatment methods available for women who prefer to avoid hysterectomy?

Women who desire surgical treatment of POP may choose to avoid hysterectomy for a variety of reasons, including preservation of fertility, maintenance of body image, and beliefs about adverse effects on sexual function.^{97–99} Alternatives to hysterectomy for the surgical treatment of POP include hysteropexy (ie, uterine suspension) and Le Fort colpocleisis.

Hysteropexy

Hysteropexy is a viable alternative to hysterectomy in women with uterine prolapse, although there is less available evidence on safety and efficacy compared with hysterectomy.⁹⁹ Hysteropexy may be performed through a vaginal incision by attaching the cervix to the sacrospinous ligament with sutures¹⁰⁰ or mesh.¹⁰¹ Hysteropexy also may be performed abdominally or laparoscopically by placing a mesh or biologic graft from the cervix to the anterior longitudinal ligament.⁹⁹ Shortening the uterosacral ligaments laparoscopically with or without robotic assistance or by an abdominal incision also can be performed. A

2016 cohort study that compared laparoscopic sacral hysteropexy with vaginal mesh hysteropexy found that, at 1-year follow-up, the 2 procedures had similar efficacy and no significant differences in the rate of complications, blood loss, or length of hospitalization.¹⁰¹

Benefits of hysteropexy compared with total hysterectomy include shorter operative time and a lower incidence of mesh erosion if mesh augmentation is used. In comparison, women with uterine prolapse who choose hysterectomy will have a lower risk of uterine and cervical cancer or any procedures that involve abnormalities of the cervix or uterus (eg, endometrial biopsy). They will not become pregnant and will not have uterine bleeding or pain.

Outcome data comparing hysterectomy with hysteropexy are not clear. In a study, vaginal hysterectomy for the treatment of stage II or greater POP was associated with a lower risk of recurrent prolapse than hysteropexy.¹⁰⁰ However, in a randomized trial that compared sacrospinous hysteropexy with vaginal hysterectomy and uterosacral ligament vaginal vault suspension for stage 2 or greater POP, sacrospinous hysteropexy was found to be noninferior to vaginal hysterectomy (for anatomic recurrence of the apical compartment with bothersome bulge symptoms or repeat surgery for recurrent apical prolapse): sacrospinous hysteropexy 0% (n = 0) versus vaginal hysterectomy 4.0% (n = 4), a difference of -3.9% (95% CI, -8.6% to 0.79%) over 12 months.¹⁰² Longer-term follow-up on this cohort of women is needed. Another study that compared postoperative sexual function in women who underwent hysteropexy with women who underwent hysterectomy found no significant difference between the 2 groups.⁹⁸ There is little information regarding pregnancy after uterine suspension.¹⁰³

Le Fort Colpocleisis

In women with POP who want to avoid hysterectomy or who have significant comorbidities and no longer desire vaginal coital function, a Le Fort colpocleisis is a therapeutic option. This is an effective treatment for POP with a high success rate and high patient satisfaction. However, patients should be counseled that this surgery is irreversible.⁷⁷ For more information, see *Are surgical approaches available to treat POP in women with medical comorbidities?*

Can the occurrence of stress urinary incontinence after surgery for POP be anticipated and avoided?

All women with significant apical prolapse, anterior prolapse, or both should have a preoperative evaluation for occult stress urinary incontinence, with cough stress testing or urodynamic testing with the prolapse reduced.¹⁰⁴ Some women will have a positive cough stress test result only when their POP is in the reduced position. Prolapse may obstruct the urethra or the urethra might kink from an anterior vaginal wall prolapse. This could mask stress urinary incontinence, which then may present after surgery. In women with bothersome POP and current stress urinary incontinence symptoms, it is prudent to correct both disorders to reduce persistent or worsening stress incontinence after surgery. Because there is no single procedure that adequately treats POP and urinary incontinence, 2 procedures are done concomitantly. Thus, women with bothersome stress urinary incontinence who are undergoing POP surgery should consider having concomitant treatment for both disorders. The type of continence procedure often is selected based on the route of access for the prolapse repair.¹⁰⁴

Patients with POP but without stress urinary incontinence who are undergoing either abdominal or vaginal prolapse repair should be counseled that postoperative stress urinary incontinence is more likely without a concomitant continence procedure but that the risk of adverse effects is increased with an additional

procedure.¹⁰⁴ Burch colposuspension at the time of abdominal sacrocolpopexy and retropubic midurethral sling at the time of vaginal surgery for POP repair decrease the risk of postoperative stress urinary incontinence in women without preoperative stress urinary incontinence.¹⁰⁴⁻¹⁰⁶ In the CARE trial, women with no reported preoperative stress urinary incontinence who were undergoing open abdominal sacrocolpopexy for prolapse repair were randomized to receive concomitant Burch colposuspension or no continence procedure.¹⁰⁵ Fewer women who underwent concomitant Burch colposuspension had postoperative stress incontinence compared with those who underwent sacrocolpopexy alone (34% vs 57%, $P < 0.001$). Similar results were found in the outcomes after the Vaginal Prolapse Repair and Midurethral Sling trial, which evaluated placement of a prophylactic midurethral sling at the time of vaginal prolapse surgery.¹⁰⁶ Among the women who underwent prophylactic midurethral sling placement at the time of vaginal surgery, 24% developed stress urinary incontinence after surgery, compared with 49% in those who underwent only POP surgery.

In women undergoing vaginal POP surgery, the risks of complications from the stress urinary incontinence surgery should be weighed against the risk of postoperative stress urinary incontinence. Some practitioners favor a staged approach in which women undergo stress urinary incontinence surgery after POP surgery only if they develop stress urinary incontinence. For more information, see Practice Bulletin No. 155, *Urinary Incontinence in Women*.¹⁰⁴

What are the complications of POP surgery, and how are they managed?

Complications after native tissue POP surgery include bleeding, infection (typically urinary tract), and voiding dysfunction (which usually is transient). Less common complications include rectovaginal or vesicovaginal fistula, ureteral injury, foreshortened vagina, or a restriction of the vaginal caliber.^{21,75} In the Operations and Pelvic Muscle Training in the Management of Apical Support Loss trial, dyspareunia was noted in 16% of women 24 months after native tissue POP surgery.¹⁰⁷ Changes in vaginal anatomy may lead to pelvic pain and pain with intercourse. Fistula and ureteral injury require prompt referral to specialists with expertise in managing these conditions. A short vagina or vaginal constriction after POP surgery often can be managed with vaginal estrogen and progressive dilators.¹⁰⁸ If these management methods are not successful, referral to a specialist who is experienced with surgical correction of postoperative POP complications is recommended.

There are unique complications associated with synthetic mesh when they are used in POP surgery. These include mesh contracture and erosion into the vagina, urethra, bladder, and rectum. The rate of mesh erosion is approximately 12% after vaginal mesh prolapse surgery.⁴¹ When mesh is used for anterior vaginal wall prolapse repair, there is an 11% risk of mesh erosion, with 7% of these cases requiring surgical correction.⁸⁹ The rate of dyspareunia is approximately 9% after vaginal mesh prolapse surgery.¹⁰⁹ Multiple procedures often are required to manage mesh-related complications.¹¹⁰ Referral to an obstetrician-gynecologist with appropriate training and experience, such as a female pelvic medicine and reconstructive surgery specialist, is recommended for surgical treatment of prolapse mesh complications. For more information, see Committee Opinion No. 694, *Management of Mesh and Graft Complications in Gynecologic Surgery*.⁸⁷

How should recurrent POP be managed?

Recurrence of POP is possible after any POP surgery. Recurrence rates between 6% and 30% have been reported.¹⁹ Women should be counseled about the risk of recurrence before undergoing POP surgery.

Women who present with recurrent POP should undergo counseling similar to that for women who present with primary POP. It is helpful to review the preoperative examination results and prior surgical reports. Many patients may choose not to undergo a repeat surgery. They may choose instead to monitor the prolapse or to use a pessary.

If a patient chooses to undergo surgery for recurrent vaginal apex prolapse, abdominal sacrocolpopexy, vaginal colpopexy with possible mesh or graft augmentation, or colpoceleisis may be considered if the patient has failed a vaginal native tissue apical suspension. If the surgeon is not comfortable performing these procedures, referral of the patient to a surgeon who subspecializes in pelvic reconstructive surgery and can offer these procedures is recommended.

Summary of Recommendations and Conclusions

The following recommendations and conclusions are based on good and consistent scientific evidence (level A):

- Uterosacral ligament suspension and sacrospinous ligament suspension for apical POP with native tissue are equally effective surgical treatments of POP, with comparable anatomic, functional, and adverse outcomes.
- The use of synthetic mesh or biologic grafts in transvaginal repair of posterior vaginal wall prolapse does not improve outcomes.
- Compared with native tissue anterior repair, polypropylene mesh augmentation of anterior vaginal wall prolapse repair improves anatomic and some subjective outcomes but is associated with increased morbidity.

The following recommendations and conclusions are based on limited or inconsistent scientific evidence (level B):

- Many women with POP on physical examination do not report symptoms of POP. Treatment is indicated only if prolapse is causing bothersome bulge and pressure symptoms, sexual dysfunction, lower urinary tract dysfunction, or defecatory dysfunction.
- Women considering treatment of POP should be offered a vaginal pessary as an alternative to surgery.
- Vaginal apex suspension should be performed at the time of hysterectomy for uterine prolapse to reduce the risk of recurrent POP.
- Abdominal sacrocolpopexy with synthetic mesh has a lower risk of recurrent POP but is associated with more complications than vaginal apex repair with native tissue.
- Obliterative procedures—which narrow, shorten, or completely close the vagina—are effective for the treatment of POP and should be considered a first-line surgical treatment for women with significant medical comorbidities who do not desire future vaginal intercourse or vaginal preservation.
- The use of synthetic mesh or biologic grafts in POP surgery is associated with unique complications not seen in POP repair with native tissue.
- Hysteropexy is a viable alternative to hysterectomy in women with uterine prolapse, although there is less available evidence on safety and efficacy compared with hysterectomy.

The following recommendations are based primarily on consensus and expert opinion (level C):

- A POP-Q examination is recommended before treatment for the objective evaluation and documentation of the extent of prolapse.

- A pessary should be considered for a woman with symptomatic POP who wishes to become pregnant in the future.
- Pelvic organ prolapse vaginal mesh repair should be limited to high-risk individuals in whom the benefit of mesh placement may justify the risk, such as individuals with recurrent prolapse (particularly of the anterior or apical compartments) or with medical comorbidities that preclude more invasive and lengthier open and endoscopic procedures. Before placement of synthetic mesh grafts in the anterior vaginal wall, patients should provide their informed consent after reviewing the benefits and risks of the procedure and discussing alternative repairs.
- Surgeons who perform POP surgery with biologic grafts or synthetic mesh grafts should have training specifically for these procedures and should be able to counsel patients regarding the risk-benefit ratio for the use of mesh compared with native tissue repair.
- Routine intraoperative cystoscopy during POP surgery is recommended when the surgical procedure performed is associated with a significant risk of injury to the bladder or ureter. These procedures include suspension of the vaginal apex to the uterosacral ligaments, sacrocolpopexy, and anterior colporrhaphy and the placement of mesh in the anterior and apical compartments.
- All women with significant apical prolapse, anterior prolapse, or both should have a preoperative evaluation for occult stress urinary incontinence, with cough stress testing or urodynamic testing with the prolapse reduced.
- Patients with POP but without stress urinary incontinence who are undergoing either abdominal or vaginal prolapse repair should be counseled that postoperative stress urinary incontinence is more likely without a concomitant continence procedure but that the risk of adverse effects is increased with an additional procedure.

Literature Search/Level of Evidence Box

The MEDLINE database, the Cochrane Library, and the American College of Obstetricians and Gynecologists' own internal resources and documents were used to conduct a literature search to locate relevant articles published between January 2000 and October 2016. The search was restricted to articles published in the English language. Priority was given to articles reporting results of original research, although review articles and commentaries also were consulted. Abstracts of research presented at symposia and scientific conferences were not considered adequate for inclusion in this document. Guidelines published by organizations or institutions such as the National Institutes of Health and the American College of Obstetricians and Gynecologists were reviewed, and additional studies were located by reviewing bibliographies of identified articles. When reliable research was not available, expert opinions from obstetrician-gynecologists were used.

Studies were reviewed and evaluated for quality according to the method outlined by the US Preventive Services Task Force:

- I—Evidence obtained from at least 1 properly designed randomized controlled trial.
- II-1—Evidence obtained from well-designed controlled trials without randomization.
- II-2—Evidence obtained from well-designed cohort or case-control analytic studies, preferably from more than 1 center or research group.
- II-3—Evidence obtained from multiple time series with or without the intervention. Dramatic results in uncontrolled experiments also could be regarded as this type of evidence.

III—Opinions of respected authorities, based on clinical experience, descriptive studies, or reports of expert committees.

Based on the highest level of evidence found in the data, recommendations are provided and graded according to the following categories:

- Level A—Recommendations are based on good and consistent scientific evidence.
- Level B—Recommendations are based on limited or inconsistent scientific evidence.
- Level C—Recommendations are based primarily on consensus and expert opinion.

This information is designed as an educational resource to aid clinicians in providing obstetric and gynecologic care, and use of this information is voluntary. This information should not be considered as inclusive of all proper treatments or methods of care or as a statement of the standard of care. It is not intended to substitute for the independent professional judgment of the treating clinician. Variations in practice may be warranted when, in the reasonable judgment of the treating clinician, such course of action is indicated by the condition of the patient, limitations of available resources, or advances in knowledge or technology. The American College of Obstetricians and Gynecologists reviews its publications regularly; however, its publications may not reflect the most recent evidence. Any updates to this document can be found on acog.org or by calling the ACOG Resource Center.

While ACOG makes every effort to present accurate and reliable information, this publication is provided “as is” without any warranty of accuracy, reliability, or otherwise, either express or implied. ACOG does not guarantee, warrant, or endorse the products or services of any firm, organization, or person. Neither ACOG nor its officers, directors, members, employees, or agents will be liable for any loss, damage, or claim with respect to any liabilities, including direct, special, indirect, or consequential damages, incurred in connection with this publication or reliance on the information presented.

All ACOG committee members and authors have submitted a conflict of interest disclosure statement related to this published product. Any potential conflicts have been considered and managed in accordance with ACOG’s Conflict of Interest Disclosure Policy. The ACOG policies can be found on acog.org. For products jointly developed with other organizations, conflict of interest disclosures by representatives of the other organizations are addressed by those organizations. The American College of Obstetricians and Gynecologists has neither solicited nor accepted any commercial involvement in the development of the content of this published product.

REFERENCES

1. Wu JM, Matthews CA, Conover MM, et al. Lifetime risk of stress urinary incontinence or pelvic organ prolapse surgery. *Obstet Gynecol* 2014;123:1201–1206.
2. Luber KM, Boero S, Choe JY. The demographics of pelvic floor disorders: current observations and future projections. *Am J Obstet Gynecol* 2001;184:1496–1501 discussion 1501–1503.
3. Wu JM, Vaughan CP, Goode PS, et al. Prevalence and trends of symptomatic pelvic floor disorders in U.S. women. *Obstet Gynecol* 2014;123:141–148.
4. Haylen BT, de Ridder D, Freeman RM, et al. International Urogynecological Association, International Continence Society. An International Urogynecological Association (IUGA)/International

- Continence Society (ICS) joint report on the terminology for female pelvic floor dysfunction. *NeurourolUrodyn* 2010;29:4–20.
5. Gutman RE, Ford DE, Quiroz LH, et al. Is there a pelvic organ prolapse threshold that predicts pelvic floor symptoms? *Am J Obstet Gynecol* 2008;199:683.e1–683.e 7.
6. Barber MD, Maher C. Epidemiology and outcome assessment of pelvic organ prolapse. *Int Urogynecol J* 2013;24:1783–1790.
7. Swift S, Woodman P, O’Boyle A, et al. Pelvic Organ Support Study (POSS): the distribution, clinical definition, and epidemiologic condition of pelvic organ support defects. *Am J Obstet Gynecol* 2005;192:795–806.
8. Gilchrist AS, Campbell W, Steele H, et al. Outcomes of observation as therapy for pelvic organ prolapse: a study in the natural history of pelvic organ prolapse. *NeurourolUrodyn* 2013;32:383–386.
9. Bradley CS, Zimmerman MB, Qi Y, et al. Natural history of pelvic organ prolapse in postmenopausal women. *Obstet Gynecol* 2007;109:848–854.
10. Boyles SH, Weber AM, Meyn L. Procedures for pelvic organ prolapse in the United States, 1979–1997. *Am J Obstet Gynecol* 2003;188:108–115.
11. Shah AD, Kohli N, Rajan SS, et al. The age distribution, rates, and types of surgery for pelvic organ prolapse in the USA. *Int Urogynecol J Pelvic Floor Dysfunct* 2008;19:421–428.
12. Smith FJ, Holman CD, Moorin RE, et al. Lifetime risk of undergoing surgery for pelvic organ prolapse. *Obstet Gynecol* 2010;116:1096–1100.
13. Mant J, Painter R, Vessey M. Epidemiology of genital prolapse: observations from the Oxford Family Planning Association Study. *Br J Obstet Gynaecol* 1997;104:579–585.
14. Maher C, Baessler K. Surgical management of posterior vaginal wall prolapse: an evidence-based literature review. *Int Urogynecol J Pelvic Floor Dysfunct* 2006;17:84–88.
15. Weber AM, Richter HE. Pelvic organ prolapse. *Obstet Gynecol* 2005;106:615–634.
16. Handa VL, Blomquist JL, Knoepp LR, et al. Pelvic floor disorders 5–10 years after vaginal or cesarean childbirth. *Obstet Gynecol* 2011;118:777–784.
17. Vergeldt TF, Weemhoff M, Int’Hout J, et al. Risk factors for pelvic organ prolapse and its recurrence: a systematic review. *Int Urogynecol J* 2015;26:1559–1573.
18. Blandon RE, Bharucha AE, Melton LJ 3rd, et al. Incidence of pelvic floor repair after hysterectomy: a population-based cohort study. *Am J Obstet Gynecol* 2007;197:664.e1–664.e7.
19. Dällenbach P. To mesh or not to mesh: a review of pelvic organ reconstructive surgery. *Int J Womens Health* 2015;7:331–343.
20. Nygaard I, Brubaker L, Zyczynski HM, et al. Long-term outcomes following abdominal sacrocolpopexy for pelvic organ prolapse. *JAMA* 2013;309:2016–2024.
21. Barber MD, Brubaker L, Burgio KL, et al. Eunice Kennedy Shriver National Institute of Child Health and Human Development Pelvic Floor Disorders Network. Comparison of 2 transvaginal surgical approaches and perioperative behavioral therapy for apical vaginal prolapse: the OPTIMAL randomized trial. [published correction appears in *JAMA* 2015;313:2287]. *JAMA* 2014;311:1023–1034.
22. Larson KA, Smith T, Berger MB, et al. Long-term patient satisfaction with Michigan four-wall sacrospinous ligament suspension for prolapse. *Obstet Gynecol* 2013;122:967–975.
23. Eilber KS, Alperin M, Khan A, et al. Outcomes of vaginal prolapse surgery among female Medicare beneficiaries: the role of apical support. *Obstet Gynecol* 2013;122:981–987.
24. Whiteside JL, Weber AM, Meyn LA, et al. Risk factors for prolapse recurrence after vaginal repair. *Am J Obstet Gynecol* 2004;191:1533–1538.

25. Nieminen K, Huhtala H, Heinonen PK. Anatomic and functional assessment and risk factors of recurrent prolapse after vaginal sacrospinous fixation. *Acta Obstet Gynecol Scand* 2003;82:471–478.
26. Diez-Itza I, Aizpitarte I, Becerro A. Risk factors for the recurrence of pelvic organ prolapse after vaginal surgery: a review at 5 years after surgery. *Int Urogynecol J Pelvic Floor Dysfunct* 2007;18:1317–1324.
27. Abrams P, Andersson KE, Birder L, et al. Fourth International Consultation on Incontinence recommendations of the International Scientific Committee: evaluation and treatment of urinary incontinence, pelvic organ prolapse, and fecal incontinence. *Neurourol Urodyn* 2010; 29:213–240.
28. Bump RC, Mattiasson A, Bo K, et al. The standardization of terminology of female pelvic organ prolapse and pelvic floor dysfunction. *Am J Obstet Gynecol* 1996;175:10–17.
29. Hall AF, Theofrastous JP, Cundiff GW, et al. Interobserver and intraobserver reliability of the proposed International Continence Society, Society of Gynecologic Surgeons, and American Urogynecologic Society pelvic organ prolapse classification system. *Am J Obstet Gynecol* 1996; 175:1467–1470 discussion 1470–1471.
30. Kobak WH, Rosenberger K, Walters MD. Interobserver variation in the assessment of pelvic organ prolapse. *Int Urogynecol J Pelvic Floor Dysfunct* 1996;7:121–124.
31. Pham T, Burgart A, Kenton K, et al. Current use of Pelvic Organ Prolapse Quantification by AUGS and ICS members. *Female Pelvic Med Reconstr Surg* 2011;17:67–69.
32. Treszezamsky AD, Rascoff L, Shahryarnejad A, et al. Use of pelvic organ prolapse staging systems in published articles of selected specialized journals. *Int Urogynecol J* 2010;21:359–363.
33. Spiller RC, Thompson WG. Bowel disorders. *Am J Gastroenterol* 2010; 105:775–785.
34. Braekken IH, Majida M, Engh ME, et al. Can pelvic floor muscle training reverse pelvic organ prolapse and reduce prolapse symptoms? An assessor-blinded, randomized, controlled trial. *Am J Obstet Gynecol* 2010; 203:170.e1–170.e 7.
35. Hagen S, Stark D. Conservative prevention and management of pelvic organ prolapse in women [systematic review]. *Cochrane Database of Systematic Reviews* 2011; issue 12, art. no.: CD003882.
36. Ismail SI, Bain C, Hagen S. Oestrogens for treatment or prevention of pelvic organ prolapse in postmenopausal women [systematic review]. *Cochrane Database of Systematic Reviews* 2010; issue 9, art. no.: CD007063.
37. Cundiff GW, Amundsen CL, Bent AE, et al. The PESSRI study: symptom relief outcomes of a randomized crossover trial of the ring and Gellhorn pessaries. *Am J Obstet Gynecol* 2007;196:405.e1–405.e8.
38. Clemons JL, Aguilar VC, Tillinghast TA, et al. Patient satisfaction and changes in prolapse and urinary symptoms in women who were fitted successfully with a pessary for pelvic organ prolapse. *Am J Obstet Gynecol* 2004;190:1025–1029.
39. Robert M, Schulz JA, Harvey MA, et al. Urogynaecology Committee. Technical update on pessary use. *J Obstet Gynaecol Can* 2013;35: 664–674.
40. Arias BE, Ridgeway B, Barber MD. Complications of neglected vaginal pessaries: case presentation and literature review. *Int Urogynecol J Pelvic Floor Dysfunct* 2008;19:1173–1178.
41. Maher C, Feiner B, Baessler K, et al. Transvaginal mesh or grafts compared with native tissue repair for vaginal prolapse. *Cochrane Database Syst Rev* 2016; issue 2, art. no.: CD012079.
42. Webb MJ, Aronson MP, Ferguson LK, et al. Posthysterectomy vaginal vault prolapse: primary repair in 693 patients. *Obstet Gynecol* 1998;92: 281–285.
43. Shull BL, Bachofen C, Coates KW, et al. A transvaginal approach to repair of apical and other associated sites of pelvic organ prolapse with uterosacral ligaments. *Am J Obstet Gynecol* 2000;183:1365–1373 discussion 1373–1374.
44. Cruikshank SH, Kovac SR. Randomized comparison of three surgical methods used at the time of vaginal hysterectomy to prevent posterior enterocele. *Am J Obstet Gynecol* 1999;180:859–865.
45. McCall ML. Posterior culdeplasty; surgical correction of enterocele during vaginal hysterectomy; a preliminary report. *Obstet Gynecol* 1957; 10:595–602.
46. Petri E, Ashok K. Sacrospinous vaginal fixation—current status. *Acta Obstet Gynecol Scand* 2011;90:429–436.
47. Chmielewski L, Walters MD, Weber AM, et al. Reanalysis of a randomized trial of 3 techniques of anterior colporrhaphy using clinically relevant definitions of success. *Am J Obstet Gynecol* 2011;205(69):e1–e8.
48. Chen L, Ashton-Miller JA, Hsu Y, et al. Interaction among apical support, levator ani impairment, and anterior vaginal wall prolapse. *Obstet Gynecol* 2006;108:324–332.
49. Richardson AC. The anatomic defects in rectocele techniques and enterocele. *J Pelv Surg* 1995;1:214–221.
50. Larson KA, Luo J, Guire KE, et al. 3D analysis of cystoceles using magnetic resonance imaging assessing midline, paravaginal, and apical defects. *Int Urogynecol J* 2012;23:285–293.
51. Barber MD, Cundiff GW, Weidner AC, et al. Accuracy of clinical assessment of paravaginal defects in women with anterior vaginal wall prolapse. *Am J Obstet Gynecol* 1999;181:87–90.
52. Dietz HP, Pang S, Korda A, et al. Paravaginal defects: a comparison of clinical examination and 2D/3D ultrasound imaging. *Aust N Z J Obstet Gynaecol* 2005;45:187–190.
53. Shippey SH, Quiroz LH, Sanses TV, et al. Anatomic outcomes of abdominal sacrocolpopexy with or without paravaginal repair. *Int Urogynecol J* 2010;21:279–283.
54. Karram M, Maher C. Surgery for posterior vaginal wall prolapse. *Int Urogynecol J* 2013;24:1835–1841.
55. Kahn MA, Stanton SL. Posterior colporrhaphy: its effects on bowel and sexual function. *Br J Obstet Gynaecol* 1997;104:82–86.
56. Cundiff GW, Weidner AC, Visco AG, et al. An anatomic and functional assessment of the discrete defect rectocele repair. *Am J Obstet Gynecol* 1998;179:1451–1456 discussion 1456–1457.
57. Abramov Y, Gandhi S, Goldberg RP, et al. Site-specific rectocele repair compared with standard posterior colporrhaphy. *Obstet Gynecol* 2005; 105:314–318.
58. Paraiso MF, Barber MD, Muir TW, et al. Rectocele repair: a randomized trial of three surgical techniques including graft augmentation. *Am J Obstet Gynecol* 2006;195:1762–1771.
59. Maher CF, Qatawneh AM, Dwyer PL, et al. Abdominal sacral colpopexy or vaginal sacrospinous colpopexy for vaginal vault prolapse: a prospective randomized study. *Am J Obstet Gynecol* 2004;190:20–26.
60. Culligan PJ, Salamon C, Priestley JL, et al. Porcine dermis compared with polypropylene mesh for laparoscopic sacrocolpopexy: a randomized controlled trial. *Obstet Gynecol* 2013;121:143–151.
61. Tate SB, Blackwell L, Lorenz DJ, et al. Randomized trial of fascia lata and polypropylene mesh for abdominal sacrocolpopexy: 5-year follow-up. *Int Urogynecol J* 2011;22:137–143.
62. Siddiqui NY, Grimes CL, Casiano ER, et al. Society of Gynecologic Surgeons Systematic Review Group. Mesh sacrocolpopexy compared with native tissue vaginal repair: a systematic review and meta-analysis [systematic review]. *Obstet Gynecol* 2015;125:44–55.
63. Hudson CO, Northington GM, Lyles RH, et al. Outcomes of robotic sacrocolpopexy: a systematic review and meta-analysis. *Female Pelvic Med Reconstr Surg* 2014;20:252–260 (Systematic review).

64. Nosti PA, Umoh Andy U, Kane S, et al. Outcomes of abdominal and minimally invasive sacrocolpopexy: a retrospective cohort study. *Female Pelvic Med Reconstr Surg* 2014;20:33–37.
65. Freeman RM, Pantazis K, Thomson A, et al. A randomised controlled trial of abdominal versus laparoscopic sacrocolpopexy for the treatment of post-hysterectomy vaginal vault prolapse: LAS study. *Int Urogynecol J* 2013;24:377–384.
66. Tarr ME, Brancato SJ, Cunkelman JA, et al. Comparison of postural ergonomics between laparoscopic and robotic sacrocolpopexy: a pilot study. *J Minim Invasive Gynecol* 2015;22:234–238.
67. Diana M, Marescaux J. Robotic surgery. *Br J Surg* 2015;102:e15–e28.
68. Awad N, Mustafa S, Amit A, et al. Implementation of a new procedure: laparoscopic versus robotic sacrocolpopexy. *Arch Gynecol Obstet* 2013; 287:1181–1186.
69. Paraiso MF, Jelovsek JE, Frick A, et al. Laparoscopic compared with robotic sacrocolpopexy for vaginal prolapse: a randomized controlled trial. *Obstet Gynecol* 2011;118:1005–1013.
70. Seror J, Yates DR, Seringe E, et al. Prospective comparison of short-term functional outcomes obtained after pure laparoscopic and robot-assisted laparoscopic sacrocolpopexy. *World J Urol* 2012;30: 393–398.
71. Collins SA, Tulikangas PK, O’Sullivan DM. Effect of surgical approach on physical activity and pain control after sacral colpopexy. *Am J Obstet Gynecol* 2012;206:438.e1–438.e6.
72. Anger JT, Mueller ER, Tamay C, et al. Robotic compared with laparoscopic sacrocolpopexy: a randomized controlled trial. *Obstet Gynecol* 2014;123:5–12.
73. Liu H, Lawrie TA, Lu DH, et al. Robot-assisted surgery in gynaecology [systematic review]. *Cochrane Database Syst Rev* 2014; issue 12. art. no.: CD011422.
74. Committee Opinion No. 628. American College of Obstetricians and Gynecologists. Robotic surgery in gynecology. *Obstet Gynecol* 2015;125: 760–767.
75. Maher C, Feiner B, Baessler K, et al. Surgical management of pelvic organ prolapse in women [systematic review]. *Cochrane Database Syst Rev* 2013; issue 4. art. no.: CD004014.
76. Sung VW, Weitzen S, Sokol ER, et al. Effect of patient age on increasing morbidity and mortality following urogynecologic surgery. *Am J Obstet Gynecol* 2006;194:1411–1417.
77. FitzGerald MP, Richter HE, Siddique S, et al. Pelvic Floor Disorders Network. Colpopoiesis: a review. *Int Urogynecol J Pelvic Floor Dysfunct* 2006;17:261–271.
78. Barber MD, Amundsen CL, Paraiso MF, et al. Quality of life after surgery for genital prolapse in elderly women: obliterative and reconstructive surgery. *Int Urogynecol J Pelvic Floor Dysfunct* 2007;18:799–806.
79. Fitzgerald MP, Richter HE, Bradley CS, et al. Pelvic Floor Disorders Network. Pelvic support, pelvic symptoms, and patient satisfaction after colpopoiesis. *Int Urogynecol J Pelvic Floor Dysfunct* 2008;19: 1603–1609.
80. von Pechmann WS, Mutone M, Fyffe J, et al. Total colpopoiesis with high levator plication for the treatment of advanced pelvic organ prolapse. *Am J Obstet Gynecol* 2003;189:121–126.
81. Wheeler TL 2nd, Richter HE, Burgio KL, et al. Regret, satisfaction, and symptom improvement: analysis of the impact of partial colpopoiesis for the management of severe pelvic organ prolapse. *Am J Obstet Gynecol* 2005;193:2067–2070.
82. Mueller MG, Ellimootil C, Abemethy MG, et al. Colpopoiesis: a safe, minimally invasive option for pelvic organ prolapse. *Female Pelvic Med Reconstr Surg* 2015;21:30–33.
83. Glavind K, Kempf L. Colpectomy or Le Fort colpopoiesis—a good option in selected elderly patients. *Int Urogynecol J Pelvic Floor Dysfunct* 2005; 16:48–51 discussion 51.
84. Food and Drug Administration. Urogynecologic surgical mesh: update on the safety and effectiveness of transvaginal placement for pelvic organ prolapse. Silver Spring, MD: FDA; 2011. Available at: <http://www.fda.gov/downloads/medicaldevices/safety/alertsandnotices/UCM262760.pdf>. Accessed October 17, 2016.
85. U.S. Food and Drug Administration. FDA takes action to protect women’s health, orders manufacturers of surgical mesh intended for transvaginal repair of pelvic organ prolapse to stop selling all devices. Silver Spring, MD: FDA; 2019. Available at: <https://www.fda.gov/NewsEvents/Newsroom/PressAnnouncements/ucm636114.htm>. Accessed July 17, 2019.
86. Surgical mesh for transvaginal pelvic organ prolapse repair. 21 C.F.R. § 884.5980 (2016).
87. Management of mesh and graft complications in gynecologic surgery. Committee Opinion No. 694. American College of Obstetricians and Gynecologists. *Obstet Gynecol* 2017;129:e102–e108.
88. Sung VW, Rardin CR, Raker CA, et al. Porcine subintestinal submucosal graft augmentation for rectocele repair: a randomized controlled trial. *Obstet Gynecol* 2012;119:125–133.
89. Maher C, Feiner B, Baessler K, et al. Surgery for women with anterior compartment prolapse [systematic review]. *Cochrane Database Syst Rev* 2016; issue 11. art. no.: CD004014.
90. Ellington DR, Richter HE. Indications, contraindications, and complications of mesh in surgical treatment of pelvic organ prolapse. *Clin Obstet Gynecol* 2013;56:276–288.
91. de Tayrac R, Faillie JL, Gaillet S, et al. Analysis of the learning curve of bilateral anterior sacrospinous ligament suspension associated with anterior mesh repair. *Eur J Obstet Gynecol Reprod Biol* 2012;165:361–365.
92. American Urogynecologic Society’s Guidelines Development Committee. Guidelines for providing privileges and credentials to physicians for transvaginal placement of surgical mesh for pelvic organ prolapse. *Female Pelvic Med Reconstr Surg* 2012;18:194–197.
93. American Urogynecologic Society’s Guidelines Development Committee. Guidelines for privileging and credentialing physicians for sacrocolpopexy for pelvic organ prolapse. *Female Pelvic Med Reconstr Surg* 2013;19:62–65.
94. Brubaker L, Cundiff G, Fine P, et al. A randomized trial of colpopexy and urinary reduction efforts (CARE): design and methods. *Control Clin Trials* 2003;24:629–642.
95. Barber MD, Brubaker L, Menefee S, et al. Operations and pelvic muscle training in the management of apical support loss (OPTIMAL) trial: design and methods. *Contemp Clin Trials* 2009;30: 178–189.
96. Kwon CH, Goldberg RP, Koduri S, et al. The use of intraoperative cystoscopy in major vaginal and urogynecologic surgeries. *Am J Obstet Gynecol* 2002;187:1466–1471 discussion 1471–1472.
97. Korbly NB, Kassis NC, Good MM, et al. Patient preferences for uterine preservation and hysterectomy in women with pelvic organ prolapse. *Am J Obstet Gynecol* 2013;209:470.e1–470.e6.
98. Jeng CJ, Yang YC, Tzeng CR, et al. Sexual functioning after vaginal hysterectomy or transvaginal sacrospinous uterine suspension for uterine prolapse: a comparison. *J Reprod Med* 2005;50:669–674.
99. Gutman R, Maher C. Uterine-preserving POP surgery. *Int Urogynecol J* 2013;24:1803–1813.
100. Dietz V, van der Vaart CH, van der Graaf Y, et al. One-year follow-up after sacrospinous hysteropexy and vaginal hysterectomy for uterine descent: a randomized study. *Int Urogynecol J* 2010;21:209–216.
101. Gutman RE, Rardin CR, Sokol ER, et al. Vaginal and laparoscopic mesh hysteropexy for uterovaginal prolapse: a parallel cohort study. *Am J Obstet Gynecol* 2017;216:38.e1–38.e11.
102. Detollenaere RJ, den Boon J, Stekelenburg J, et al. Sacrospinous hysteropexy versus vaginal hysterectomy with suspension of the

- uterosacral ligaments in women with uterine prolapse stage 2 or higher: multicentre randomised non-inferiority trial. *BMJ* 2015;351:h3717.
103. Kovac SR, Cruikshank SH. Successful pregnancies and vaginal deliveries after sacrospinous uterosacral fixation in five of nineteen patients. *Am J Obstet Gynecol* 1993;168:1778–1783 discussion 1783–1786.
104. American College of Obstetricians and Gynecologists. Urinary incontinence in women. Practice bulletin no. 155. *Obstet Gynecol* 2015; 126:e66–e81.
105. Brubaker L, Nygaard I, Richter HE, et al. Two-year outcomes after sacrocolpopexy with and without Burch to prevent stress urinary incontinence. *Obstet Gynecol* 2008;112:49–55.
106. Wei JT, Nygaard I, Richter HE, et al Pelvic Floor Disorders Network. A midurethral sling to reduce incontinence after vaginal prolapse repair. *N Engl J Med* 2012;366:2358–2367.
107. Lukacz ES, Warren LK, Richter HE, et al. Quality of life and sexual function 2 years after vaginal surgery for prolapse. *Obstet Gynecol* 2016; 127:1071–1079.
108. Antosh DD, Gutman RE, Park AJ, et al. Vaginal dilators for prevention of dyspareunia after prolapse surgery: a randomized controlled trial. *Obstet Gynecol* 2013;121:1273–1280.
109. Abed H, Rahn DD, Lowenstein L, et al. Systematic Review Group of the Society of Gynecologic Surgeons. Incidence and management of graft erosion, wound granulation, and dyspareunia following vaginal prolapse repair with graft materials: a systematic review. *Int Urogynecol J* 2011;22:789–798.
110. Margulies RU, Lewicky-Gaupp C, Fenner DE, et al. Complications requiring reoperation following vaginal mesh kit procedures for prolapse. *Am J Obstet Gynecol* 2008;199:678.e1–678.e4.