



# Clinical Practice Guideline for the Management of Infantile Hemangiomas

Daniel P. Krowchuk, MD, FAAP,<sup>a</sup> Ilona J. Frieden, MD, FAAP,<sup>b</sup> Anthony J. Mancini, MD, FAAP,<sup>c</sup> David H. Darrow, MD, DDS, FAAP,<sup>d</sup> Francine Blei, MD, MBA, FAAP,<sup>e</sup> Arin K. Greene, MD, FAAP,<sup>f</sup> Aparna Annam, DO, FAAP,<sup>g</sup> Cynthia N. Baker, MD, FAAP,<sup>h</sup> Peter C. Frommelt, MD, FAAP,<sup>i</sup> Amy Hodak, CPMSM,<sup>j</sup> Brian M. Pate, MD, FHM, FAAP,<sup>k</sup> Janice L. Pelletier, MD, FAAP,<sup>l</sup> Deborah Sandrock, MD, FAAP,<sup>m</sup> Stuart T. Weinberg, MD, FAAP,<sup>n</sup> Mary Anne Whelan, MD, PhD, FAAP,<sup>o</sup> SUBCOMMITTEE ON THE MANAGEMENT OF INFANTILE HEMANGIOMAS

Infantile hemangiomas (IHs) occur in as many as 5% of infants, making them the most common benign tumor of infancy. Most IHs are small, innocuous, self-resolving, and require no treatment. However, because of their size or location, a significant minority of IHs are potentially problematic. These include IHs that may cause permanent scarring and disfigurement (eg, facial IHs), hepatic or airway IHs, and IHs with the potential for functional impairment (eg, periorbital IHs), ulceration (that may cause pain or scarring), and associated underlying abnormalities (eg, intracranial and aortic arch vascular abnormalities accompanying a large facial IH). This clinical practice guideline for the management of IHs emphasizes several key concepts. It defines those IHs that are potentially higher risk and should prompt concern, and emphasizes increased vigilance, consideration of active treatment and, when appropriate, specialty consultation. It discusses the specific growth characteristics of IHs, that is, that the most rapid and significant growth occurs between 1 and 3 months of age and that growth is completed by 5 months of age in most cases. Because many IHs leave behind permanent skin changes, there is a window of opportunity to treat higher-risk IHs and optimize outcomes. Early intervention and/or referral (ideally by 1 month of age) is recommended for infants who have potentially problematic IHs. When systemic treatment is indicated, propranolol is the drug of choice at a dose of 2 to 3 mg/kg per day. Treatment typically is continued for at least 6 months and often is maintained until 12 months of age (occasionally longer). Topical timolol may be used to treat select small, thin, superficial IHs. Surgery and/or laser treatment are most useful for the treatment of residual skin changes after involution and, less commonly, may be considered earlier to treat some IHs.

## abstract



*Departments of <sup>a</sup>Pediatrics and Dermatology, Wake Forest School of Medicine, Winston-Salem, North Carolina; Departments of <sup>b</sup>Dermatology and Pediatrics, School of Medicine, University of California, San Francisco, San Francisco, California; Departments of <sup>c</sup>Pediatrics and Dermatology, Feinberg School of Medicine, Northwestern University and Ann and Robert H. Lurie Children's Hospital of Chicago, Chicago, Illinois; Departments of <sup>d</sup>Otolaryngology and Pediatrics, Eastern Virginia Medical School and Children's Hospital of the King's Daughters, Norfolk, Virginia; <sup>e</sup>Donald and Barbara Zucker School of Medicine, Northwell Health, New York City, New York; <sup>f</sup>Department of Plastic and Oral Surgery, Boston Children's Hospital and Harvard Medical School, Harvard University, Boston, Massachusetts; <sup>g</sup>Department of Radiology, University of Colorado School of Medicine, Children's Hospital Colorado, Aurora, Colorado; <sup>h</sup>Department of Pediatrics, Kaiser Permanente Medical Center, Los Angeles, California; <sup>i</sup>Department of Pediatrics, Cardiology, Medical College of Wisconsin and Children's Hospital of Wisconsin, Milwaukee, Wisconsin; <sup>j</sup>American Board of Pediatrics, Chapel Hill, North Carolina; <sup>k</sup>Department of Pediatrics, University of Kansas School of Medicine-Wichita, Wichita, Kansas; <sup>l</sup>Department of Pediatrics, Northern Light Health, Bangor, Maine; <sup>m</sup>St Christopher's Hospital for Children and College of Medicine, Drexel University, Philadelphia, Pennsylvania; Departments of <sup>n</sup>Biomedical Informatics and Pediatrics, School of Medicine, Vanderbilt University, Nashville, Tennessee; and <sup>o</sup>College of Physicians and Surgeons, Columbia University, New York City, New York*

*This document is copyrighted and is property of the American Academy of Pediatrics and its Board of Directors. All authors have filed conflict of interest statements with the American Academy of Pediatrics. Any conflicts have been resolved through a process approved by the Board of Directors. The American Academy of Pediatrics has neither solicited nor accepted any commercial involvement in the development of the content of this publication.*

**To cite:** Krowchuk DP, Frieden IJ, Mancini AJ, et al. Clinical Practice Guideline for the Management of Infantile Hemangiomas. *Pediatrics*. 2019;143(1):e20183475

## INTRODUCTION

This is the first clinical practice guideline (CPG) from the American Academy of Pediatrics (AAP) regarding the management of infantile hemangiomas (IHs). Similar consensus statements have been published by European<sup>1</sup> and Australasian expert groups.<sup>2</sup> In addition, a recent AAP clinical report provided a comprehensive review of the pathogenesis, clinical features, and treatment of IH; it is available at <http://pediatrics.aappublications.org/content/136/4/e1060>.<sup>3</sup>

IHs occur in approximately 4% to 5% of infants, making them the most common benign tumor of childhood. They are more common in girls, twins, infants born preterm or with low birth weight (up to 30% of infants born weighing <1 kg are affected), and white neonates. The pathogenesis of IHs has yet to be fully defined. A leading hypothesis is that circulating endothelial progenitor cells migrate to locations in which conditions (eg, hypoxia and developmental field disturbances) are favorable for growth.<sup>3</sup>

Knowledge about IHs has advanced dramatically in the past decade, particularly regarding the unique timing and nature of proliferation and involution, risks of sequelae, and newer treatment options. As a result, pediatric providers have an opportunity to improve care and reduce morbidity in infants with IHs by promptly recognizing which

IHs are potentially high risk and when intervention is needed.

In the broadest sense, the goal of this CPG from the AAP is to enhance primary care providers' ability to confidently evaluate, triage, and manage IHs, employing an evidence-based approach. Specifically, the CPG will:

- provide an approach to risk stratification and recognition of potentially problematic IHs;
- emphasize that early and frequent monitoring in the first few weeks and months of life is crucial in identifying those IHs that require intervention because IHs may change rapidly during this time period;
- review the role of imaging in patients who have IHs; and
- offer evidence-based guidance for the management of IHs, including indications for consultation, referral and possible intervention, pharmacologic options for therapy, the role of surgical modalities, and ongoing management and monitoring (including parent education).

This CPG is intended for pediatricians and other primary care providers who (1) manage IHs collaboratively with a hemangioma specialist (defined below), (2) care for children with IHs being managed primarily by a hemangioma specialist, or (3) manage

IHs independently on the basis of their knowledge and expertise. It does not address the management of vascular malformations, congenital hemangiomas, or other vascular tumors. The CPG encourages enhanced communication between primary care clinicians and hemangioma specialists to ensure early assessment and treatment of infants in whom active intervention is indicated, to improve patient outcomes, and to enhance anticipatory guidance. It is not intended to be a sole source of guidance in the management of children with IHs, to replace clinical judgment, or to establish a protocol for all infants with IHs. Rather, it provides a framework for clinical decision-making.

## METHODS

The methods of this CPG are discussed in detail in the Methods section of the Supplemental Information. Briefly, a comparative effectiveness review of potential benefits and harms of diagnostic modalities and pharmacologic and surgical treatments was conducted on behalf of the Agency for Healthcare Research and Quality (AHRQ). The literature search strategy employed Medline via the PubMed interface, the Cumulative Index to Nursing and Allied Health Literature (CINAHL), and Excerpta Medica Database (Embase). Searches were limited to the English language and to studies published from 1982 to June

**TABLE 1** Highlights of This CPG

- IH growth characteristics are different than once taught.
  - Most rapid IH growth occurs between 1 and 3 months of age.
  - Although IHs involute, this process may be incomplete, leaving permanent skin changes that may be life altering. This is especially true for IHs that are thick.
  - There is a window of opportunity to treat problematic IHs. Consult early (by 1 month of age) for lesions that are potentially high risk because of the following associations (Table 3):
    - potential for disfigurement (the most common reason treatment is needed);
    - life-threatening complications;
    - functional impairment;
    - ulceration; and
    - underlying abnormalities.
- Oral propranolol is the treatment of choice for problematic IHs that require systemic therapy.
- Topical timolol may be used to treat some thin and/or superficial IHs.
- Surgery and/or laser treatment are most useful for the treatment of residual skin changes after involution. They may be used earlier to treat selected IHs.

**TABLE 2** Definitions

Hemangioma specialist:	Unlike many diseases, management of IHs is not limited to 1 medical or surgical specialty. A hemangioma specialist may have expertise in dermatology, hematologyoncology, pediatrics, facial plastic and reconstructive surgery, ophthalmology, otolaryngology, pediatric surgery, and/or plastic surgery, and his or her practice is often focused primarily or exclusively on the pediatric age group.
Hemangioma specialists should:	<ul style="list-style-type: none"> <li>• understand the time-sensitive nature of IHs during the growth phase and be able to accommodate requests for urgent evaluation;</li> <li>• have experience with accurate risk stratification and potential complications associated with IHs;</li> <li>• be able to provide recommendations for various management options, including observation, medical therapies, and surgical or laser procedures, and provide counseling regarding the potential risks and benefits of these interventions for specific patients; and</li> <li>• have a thorough knowledge of past and emerging medical literature regarding IHs.</li> <li>• Such specialists often have 1 or more of the following characteristics: <ul style="list-style-type: none"> <li>○ participated in a vascular anomalies program during previous medical training;</li> <li>○ devotes a significant part of his or her clinical practice to IHs;</li> <li>○ is a member of or collaborates with a multidisciplinary vascular anomalies center;</li> <li>○ maintains membership in professional organizations or groups with a special interest in IHs;</li> <li>○ participates in research studies in the field of IHs; or</li> <li>○ publishes medical literature in the field of IHs.</li> </ul> </li> </ul>
IHs: infantile hemangiomas	Benign vascular tumors of infancy and childhood with unique clinical and histopathologic characteristics that distinguish them from other vascular tumors (eg, congenital hemangiomas) or malformations. These characteristics include development during the first weeks or months of life, a typical natural history of rapid growth followed by gradual involution, and immunohistochemical staining of biopsy specimens with erythrocyte-type glucose transporter protein and other unique markers not present on other benign vascular tumors. Many other entities are also called hemangiomas. Some are true vascular tumors, and others are vascular malformations. Therefore, it is important to use the adjective “infantile” when referring to true IHs. IHs are classified on the basis of soft-tissue depth and the pattern of anatomic involvement (see Supplemental Figs 5–10 for photographic examples).
Soft-tissue depth:	<ul style="list-style-type: none"> <li>• Superficial: red with little or no evidence of a subcutaneous component (formerly called “strawberry” hemangiomas);</li> <li>• Deep: blue and located below the skin surface (formerly called “cavernous” hemangiomas); and</li> <li>• Combined (mixed): both superficial and deep components are present.</li> </ul>
Anatomic appearance:	<ul style="list-style-type: none"> <li>• Localized: well-defined focal lesions (appearing to arise from a central point);</li> <li>• Segmental: IH involving an anatomic region that is often plaque-like and often measuring at &gt;5 cm in diameter;</li> <li>• Indeterminate (undetermined): neither clearly localized or segmental (often called partial segmental); and</li> <li>• Multifocal: multiple discrete IHs at disparate sites.</li> </ul>

2015. Because the therapy of IHs has been evolving rapidly, the CPG subcommittee performed an updated literature review for the period of July 2015 to January 2017 to augment the original search. This most recent search employed only Medline because previously, virtually all relevant articles had been accessed via this database. The search was concentrated on pharmacologic interventions, including topical timolol (an emerging therapeutic alternative for which limited data were available at the time of the original search). The original methodology and report, including the evidence search and review, are available in their entirety and as an executive summary at [www.effectivehealthcare.ahrq.gov/reports/final.cfm](http://www.effectivehealthcare.ahrq.gov/reports/final.cfm).<sup>4</sup>

### DEVELOPMENT OF THE CLINICAL PRACTICE GUIDELINE

In December 2016, the AAP convened a multidisciplinary subcommittee composed of IH experts in the fields of dermatology, cardiology, hematology-oncology, otolaryngology (head and neck surgery), plastic surgery, and radiology. The subcommittee also included general pediatricians, a parent representative, an implementation scientist, a representative from the Partnership for Policy Implementation (<https://www.aap.org/en-us/professional-resources/quality-improvement/Pages/Partnership-for-Policy-Implementation.aspx>), and an epidemiologist and methodologist. All panel members declared potential conflicts on the basis of the AAP policy

on Conflict of Interest and Voluntary Disclosure. Subcommittee members repeated this process at the time of the publication of the guideline. All potential conflicts of interest are listed at the end of this document. The project was funded by the AAP.

The final recommendations were based on articles identified in the AHRQ and updated systematic reviews. Decisions and the strength of recommendations were based on a systematic grading of the quality of evidence by independent reviewers. Expert consensus was used when definitive data were not available. Key action statements (KASs), summarized in Table 4, were generated by subcommittee members authoring individual components of the CPG using

**TABLE 3** High-Risk IHs

IH Clinical Findings	IH Risk
Life-threatening “Beard-area” IH ≥5 cutaneous IHs	Obstructive airway hemangiomas Liver hemangiomas, cardiac failure, hypothyroidism
Functional impairment Periocular IH (>1 cm) IH involving lip or oral cavity	Astigmatism, anisometropia, proptosis, amblyopia Feeding impairment
Ulceration Segmental IH: IH of any size involving any of the following sites: lips, columella, superior helix of ear, gluteal cleft and/or perineum, perianal skin, and other intertriginous areas (eg, neck, axillae, inguinal region)	Increased risk of ulceration
Associated structural anomalies Segmental IH of face or scalp Segmental IH of lumbosacral and/or perineal area	PHACE syndrome LUMBAR syndrome
Disfigurement Segmental IH, especially of face and scalp Facial IH (measurements refer to size during infancy): nasal tip or lip (any size) or any facial location ≥2 cm (>1 cm if ≤3 mo of age) Scalp IH >2 cm	High risk of scarring and/or permanent disfigurement Risk of disfigurement via distortion of anatomic landmarks and/or scarring and/or permanent skin changes Permanent alopecia (especially if the hemangioma becomes thick or bulky); profuse bleeding if ulceration develops (typically more bleeding than at other anatomic sites)
Neck, trunk, or extremity IH >2 cm, especially in growth phase or if abrupt transition from normal to affected skin (ie, ledge effect); thick superficial IH (eg, ≥2 mm thickness) Breast IH (female infants)	Greater risk of leaving permanent scarring and/or permanent skin changes depending on anatomic location  Permanent changes in breast development (eg, breast asymmetry) or nipple contour

Categorization of IH as high risk is based on published literature (including the AHRQ review and hemangioma severity scores) and consensus of CPG subcommittee members. Given the wide variation in IH location, size, and age at presentation, the subcommittee acknowledges that there may be situations in which an IH meets high-risk criteria and, therefore, merits consultation or referral, but the practitioner and parents do not believe this is necessary or practical. Clinical judgment is always involved in such decisions, and any plan of action needs to be individualized on the basis of a number of factors, including location of the lesion, age of child, family preferences, and geographic access to care.

the results of the literature review. These sections were reviewed and refined by the subcommittee chairperson and co-chairperson and ultimately by all subcommittee members.

Evidence-based guideline recommendations from the AAP may be graded as strong, moderate, weak on the basis of low-quality evidence, or weak on the basis of balance between benefits and harms. Strong and moderate recommendations usually are associated with “should” and “should not” recommendation statements, whereas some moderate and all weak recommendations may be recognized by use of “may” or “need not,” signifying that moderate recommendations are based on a range of evidence strengths within the boundaries of the definition (Table 5, Fig 1).

The CPG underwent a comprehensive review by stakeholders (including AAP councils, committees, and sections), selected outside organizations, and individuals identified by the

subcommittee as experts in the field before formal approval by the AAP. All comments were reviewed by the subcommittee and incorporated into the final guideline when appropriate.

### RISK STRATIFICATION, TRIAGE, AND REFERRAL

#### Key Action Statement 1A (Table 6)

Clinicians should classify an IH as high risk if there is evidence of or potential for the following: (1) life-threatening complications, (2) functional impairment or ulceration, (3) structural anomalies (eg, in PHACE syndrome or LUMBAR syndrome), or (4) permanent disfigurement (grade X, strong recommendation).

The purpose of this statement is to ensure timely identification of IHs that may require early intervention. Clinicians in the primary care setting caring for infants with IH face 2 major challenges: disease heterogeneity and the unique growth characteristics of

IHs.<sup>24</sup> For example, because IHs involute spontaneously, many that are small, are superficial, occur in areas covered by clothing, and/or are unlikely to cause disfigurement do not require hemangioma specialist evaluation or treatment. However, some IHs may be considered high risk, and depending on the clinician’s comfort level and local access to specialty care, require a higher level of experience and expertise to determine if additional intervention is indicated. These high-risk IHs and their associated clinical findings are summarized in Table 3 and illustrated in Figs 2–4, Supplemental Table 22, and Supplemental Fig 11. Of particular note and as discussed later, segmental hemangiomas, those that cover an anatomic territory arising from 1 or more developmental units, confer a higher risk of morbidity and life-threatening complications than those that are localized, that is, seeming to arise from a central focal point.<sup>5</sup> At the same time, smaller IHs in particular anatomic locations, such as the cheek, tip of the

**TABLE 4** Summary of Key Action Statements (KASs) for the Management of IHs

In Managing IH, Recommendations for Clinicians	Evidence Quality; Strength of Recommendation
1. Risk stratification	
1A. Classify an IH as high risk if there is evidence of or potential for the following: (1) life-threatening complications, (2) functional impairment or ulceration, (3) structural anomalies (eg, in PHACE syndrome or LUMBAR syndrome), or (4) permanent disfigurement	X; strong
1B. After identifying an IH as high risk, facilitate evaluation by a hemangioma specialist as soon possible	X; strong
2. Imaging	
2A. Do not perform imaging unless the diagnosis of IH is uncertain, there are $\geq 5$ cutaneous IHs, or associated anatomic abnormalities are suspected	B; moderate
2B. Perform ultrasonography as the initial imaging modality when the diagnosis of IH is uncertain	C; weak
2C. Perform MRI when concerned about associated structural abnormalities (eg, PHACE syndrome or LUMBAR syndrome)	B; moderate
3. Pharmacotherapy	
3A. Use oral propranolol as the first-line agent for IHs requiring systemic treatment	A; strong
3B. Dose propranolol between 2 and 3 mg/kg per d unless there are comorbidities (eg, PHACE syndrome) or adverse effects (eg, sleep disturbance) that necessitate a lower dose	A; moderate
3C. Counsel that propranolol be administered with or after feeding and that doses be held at times of diminished oral intake or vomiting to reduce the risk of hypoglycemia	X; strong
3D. Evaluate patients for and educate caregivers about potential adverse effects of propranolol, including sleep disturbances, bronchial irritation, and clinically symptomatic bradycardia and hypotension	X; strong
3E. May prescribe oral prednisolone or prednisone to treat IHs if there are contraindications or an inadequate response to oral propranolol	B; moderate
3F. May recommend intralesional injection of triamcinolone and/or betamethasone to treat focal, bulky IHs during proliferation or in certain critical anatomic locations (eg, the lip)	B; moderate
3G. May prescribe topical timolol maleate as a therapy for thin and/or superficial IHs	B; moderate
4. Surgical management	
4. May recommend surgery and laser therapy as treatment options in managing selected IHs	C; moderate
5. Parent education	
5. Educate caregivers of infants with an IH about the condition, including the expected natural history and its potential for causing complications or disfigurement	X; strong

**TABLE 5** Guideline Definitions for Key Action Statements

Statement	Definition	Implication
Strong recommendation	A particular action is favored because anticipated benefits clearly exceed harms (or vice versa), and quality of evidence is excellent or unobtainable.	Clinicians should follow a strong recommendation unless a clear and compelling rationale for an alternative approach is present.
Moderate recommendation	A particular action is favored because anticipated benefits clearly exceed harms (or vice versa), and the quality of evidence is good but not excellent (or is unobtainable).	Clinicians would be prudent to follow a moderate recommendation but should remain alert to new information and sensitive to patient preferences.
Weak recommendation (based on low-quality evidence)	A particular action is favored because anticipated benefits clearly exceed harms (or vice versa), but the quality of evidence is weak.	Clinicians would be prudent to follow a weak recommendation but should remain alert to new information and sensitive to patient preferences.
Weak recommendation (based on balance of benefits and harms)	A weak recommendation is provided when the aggregate database shows evidence of both benefit and harm that appears to be similar in magnitude for any available courses of action.	Clinicians should consider the options in their decision-making, but patient preference may have a substantial role.

PHACE indicates posterior fossa defects, hemangiomas, cerebrovascular arterial anomalies, cardiovascular anomalies including coarctation of the aorta, and eye anomalies; LUMBAR, lower body IH and other cutaneous defects, urogenital anomalies and ulceration, myelopathy, bony deformities, anorectal malformations, and arterial anomalies and renal anomalies.

nose, and perioral and periocular skin, can confer a high risk of complications as well (see discussion below).

There are 5 major indications for consideration of early treatment or need for further evaluation of IHs:

1. life-threatening complications;

2. functional impairment or risk thereof;

3. ulceration or risk thereof;

4. evaluation to identify important associated structural anomalies; and

5. risk of leaving permanent scarring or distortion of anatomic landmarks

### *Life-threatening Complications*

Life-threatening lesions include obstructing IHs of the airway, liver IHs associated with high-output congestive heart failure and severe hypothyroidism, and, rarely, profuse bleeding from an ulcerated IH. Obstructing IHs of the airway typically involve the subglottis,



Aggregate Evidence Quality	Benefit or Harm Predominates	Benefit and Harm Balanced
<b>Level A</b> Intervention: Well-designed and conducted trials, meta-analyses on applicable populations Diagnosis: Independent gold-standard studies of applicable populations	Strong recommendation	Weak recommendation (based on balance of benefit and harm)
<b>Level B</b> Trials or diagnostic studies with minor limitations; consistent findings from multiple observational studies	Moderate recommendation	
<b>Level C</b> Single or few observational studies or multiple studies with inconsistent findings or major limitations.	Weak recommendation (based on low-quality evidence)	
<b>Level D</b> Expert opinion, case reports, reasoning from first principles	No recommendation may be made.	
<b>Level X</b> Exceptional situations in which validating studies cannot be performed and there is a clear preponderance of benefit or harm	Strong recommendation	Moderate recommendation

**FIGURE 1**  
AAP rating of evidence and recommendations.

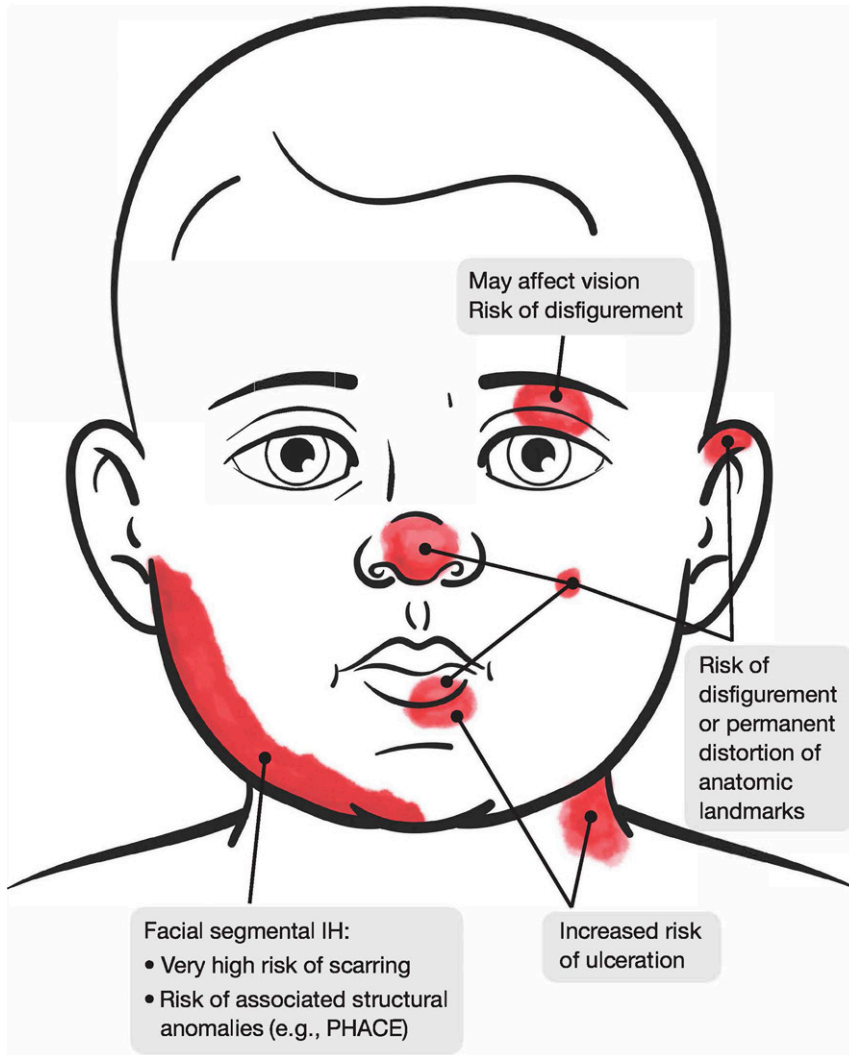
**TABLE 6** Key Action Statement 1A: Clinicians should classify an IH as high risk if there is evidence of or potential for the following: (1) life-threatening complications, (2) functional impairment or ulceration, (3) structural anomalies (eg, in PHACE syndrome or LUMBAR syndrome), or (4) permanent disfigurement (grade X, strong recommendation).

Aggregate Evidence Quality	Grade X
Benefits	Early recognition of high-risk, potentially problematic IHs facilitates early specialist evaluation and management and potential avoidance of complications
Risks, harm, cost	Unnecessary parental concern regarding lesions inappropriately characterized as high-risk IHs
Benefit-harm assessment	The benefits of identifying high-risk IHs outweigh the harm
Intentional vagueness	None
Role of patient preference	None
Exclusions	Vascular lesions that are not true IHs
Strength	Strong recommendation
Key references	5–23

further compromising the narrowest portion of the pediatric airway. Although the mean age at the time of diagnosis is about 4 months, symptoms usually present much earlier but are often mistaken as infectious or inflammatory croup or reactive airway disease.<sup>25–27</sup> Most children who are affected develop

biphasic stridor and barking cough as the IH enlarges. Approximately half of infants in whom an airway IH is diagnosed also will have a cutaneous IH. Segmental IH of the lower face (“beard distribution”) or anterior neck and oral and/or pharyngeal mucosal IHs are the greatest risk factors for an airway IH.<sup>6,27–29</sup>

Hepatic hemangiomas have been characterized as occurring in 3 patterns: focal, multifocal, and diffuse; the latter 2 are attributable to IHs, whereas focal lesions more often represent congenital hemangiomas.<sup>7,8</sup> Most multifocal hepatic IHs are asymptomatic and do not require treatment. However, a minority of these lesions are associated with macrovascular shunting, causing high flow that can, in rare cases, result in high-output cardiac failure. So-called “diffuse” hepatic IHs are another rare subset that confers an even greater risk for morbidity and mortality. Infants who are affected typically present before 4 months of age with severe hepatomegaly, which can lead to potentially lethal abdominal compartment syndrome attributable to compromised ventilation, renal failure attributable to renal vein compression, or compromised inferior vena cava blood flow to the heart.<sup>7,8</sup> A consumptive form of hypothyroidism caused by the inactivation of thyroid hormones by type 3 iodothyronine deiodinase present in IH tissue can also be a complication of multifocal or diffuse hepatic IHs.<sup>9</sup> Although liver IHs can occasionally be seen in infants with 1 or no IH of the skin, the greatest risk for liver IHs is in infants who have 5 or more cutaneous IHs,<sup>10</sup> for whom screening ultrasonography is recommended (see KAS 2A).<sup>11,30</sup> Other sites of extracutaneous hemangiomas can occur, including the gastrointestinal tract, brain, and other organs. However, such involvement is rare and occurs mostly in association with large segmental IHs, and screening for these extracutaneous hemangiomas is not recommended unless signs or symptoms are present.<sup>31,32</sup> Severe bleeding, although often feared by parents, is an extremely rare complication of ulcerated IHs (see discussion of ulceration). Another potentially life-threatening complication is severe coarctation of the aorta not attributable to IHs but rather to structural anomalies seen in association with IHs in PHACE syndrome.



**FIGURE 2**  
High-risk IHs involving the face and neck.

### Functional Impairment

Examples of functional impairment include visual disturbance and interference with feeding because of IH involvement of the lips or mouth. IHs occurring in the periorbital region have the potential to cause mechanical ptosis, strabismus, anisometropia, or astigmatism, which can quickly lead to the development of amblyopia.<sup>12,13,33</sup> Specific characteristics that place an infant at a higher risk for amblyopia include an IH size of >1 cm, upper eyelid involvement, associated ptosis, eyelid margin changes, medial location, and segmental morphology or displacement of the globe.<sup>13,34,35</sup> Feeding impairment can occur in infants with IHs involving

either the perioral region or the airway. Infants with ulcerated lip IHs may have feeding difficulties secondary to severe pain.<sup>36</sup> Airway IHs may complicate breathing and swallowing, leading also to impaired feeding.<sup>37</sup>

### Ulceration

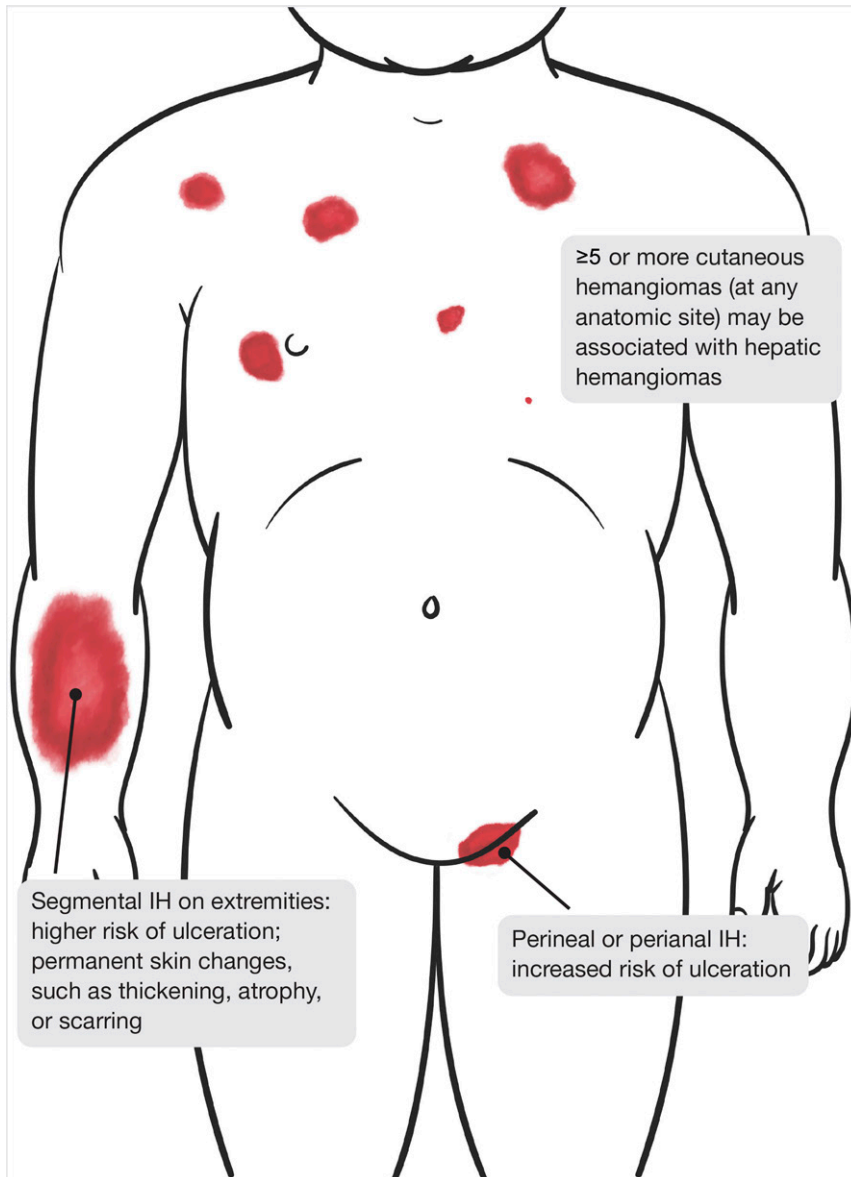
Skin or mucosal ulceration of the IH surface occurs with an estimated incidence of 5% to 21% in referral populations.<sup>14,38</sup> Ulceration can lead to significant pain, bleeding, and secondary infection and virtually always results in scarring. Depending on the anatomic site of involvement, it can result in disfigurement. Ulceration occurs most frequently in infants

younger than 4 months, during the period of active IH proliferation. Certain types of IHs are at higher risk, including superficial and mixed types, segmental IHs, and those involving the scalp, neck, and perioral, perineal, perianal, and intertriginous sites, the latter likely caused by maceration and friction. In addition, protuberant IHs can ulcerate as a result of trauma. Although concern for potential bleeding in IHs is common among caregivers and providers, most IH bleeding is minor and easily controllable with pressure. In rare cases, particularly IHs involving the scalp or with deep ulceration, bleeding can be more profuse, even life-threatening.<sup>14,15</sup>

### Associated Structural Anomalies

A small subset of children with IHs have associated congenital anomalies. The best known phenomenon is PHACE syndrome (OMIM 606519).<sup>39</sup> The acronym “PHACES” is sometimes used instead to include potential ventral midline defects, specifically sternal cleft and/or supraumbilical raphe. Cerebrovascular anomalies, present in more than 90% of patients with PHACE syndrome, are the most common extracutaneous feature of the syndrome, followed by cardiac anomalies (67%) and structural brain anomalies (52%). The hallmark of PHACE syndrome is a large (often >5 cm in diameter) segmental IH that typically involves the face, scalp, and/or neck, although in rare cases, the face or scalp are spared, with a segmental IH located on the torso and upper extremity instead.<sup>5,16</sup> The risk of PHACE syndrome in an infant presenting with a large segmental IH of the head or neck is approximately 30%.<sup>5</sup> Revised consensus criteria for the diagnosis of PHACE syndrome and the care of infants who are affected have recently been published.<sup>16</sup>

LUMBAR syndrome may best be viewed as the “lower half of the body” equivalent of PHACE syndrome.<sup>17</sup> IHs in LUMBAR syndrome are almost invariably segmental, involving the



**FIGURE 3**  
High-risk IHS involving the trunk, extremities, and perineum.

lumbosacral or perineal skin and often extending onto 1 leg. Many IHS in LUMBAR syndrome are minimally proliferative morphologically, with telangiectatic vascular stains predominating over bulkier superficial hemangiomas. In such cases, ulceration can be an early clue to the diagnosis.<sup>17</sup> Rarely, undergrowth or overgrowth of an affected limb may be present. Like PHACE syndrome, the cutaneous IH and underlying anomalies in LUMBAR syndrome reveal regional correlation. Myelopathy, particularly

spinal dysraphism, is the most common extracutaneous anomaly.<sup>17</sup>

#### Disfigurement

IHS can lead to permanent disfigurement either via scarring of the skin or distortion of anatomic landmarks (see Table 3 for specific information). The risk of disfigurement is much higher than the risk of functional or life-threatening consequences. The majority of infants who receive treatment of IHS do so to prevent uncontrolled growth leading to permanent disfigurement.<sup>1,18,40</sup>

This indication for treatment represents a paradigm shift from the hands-off approach of the late 1950s through 1980s, when many experts recommended treatment only for those IHS causing functional impairment.<sup>41</sup> One reason for this change is an increased recognition that although IHS involute, they often leave behind permanent skin changes that, although not life or function threatening, are potentially life altering.<sup>19,20</sup> Moreover, with the advent of  $\beta$ -blocker therapies for IHS, there are now better treatment options with greater efficacy and lower potential toxicity than oral corticosteroids, the previous gold standard. There is also increased recognition that parental and patient quality of life can be adversely affected by visible birthmarks and resultant scarring, particularly in areas that cannot be easily covered with clothing, such as the face, neck, arms, and hands, as well as other emotionally sensitive areas, such as the breasts and genitalia.<sup>42–44</sup>

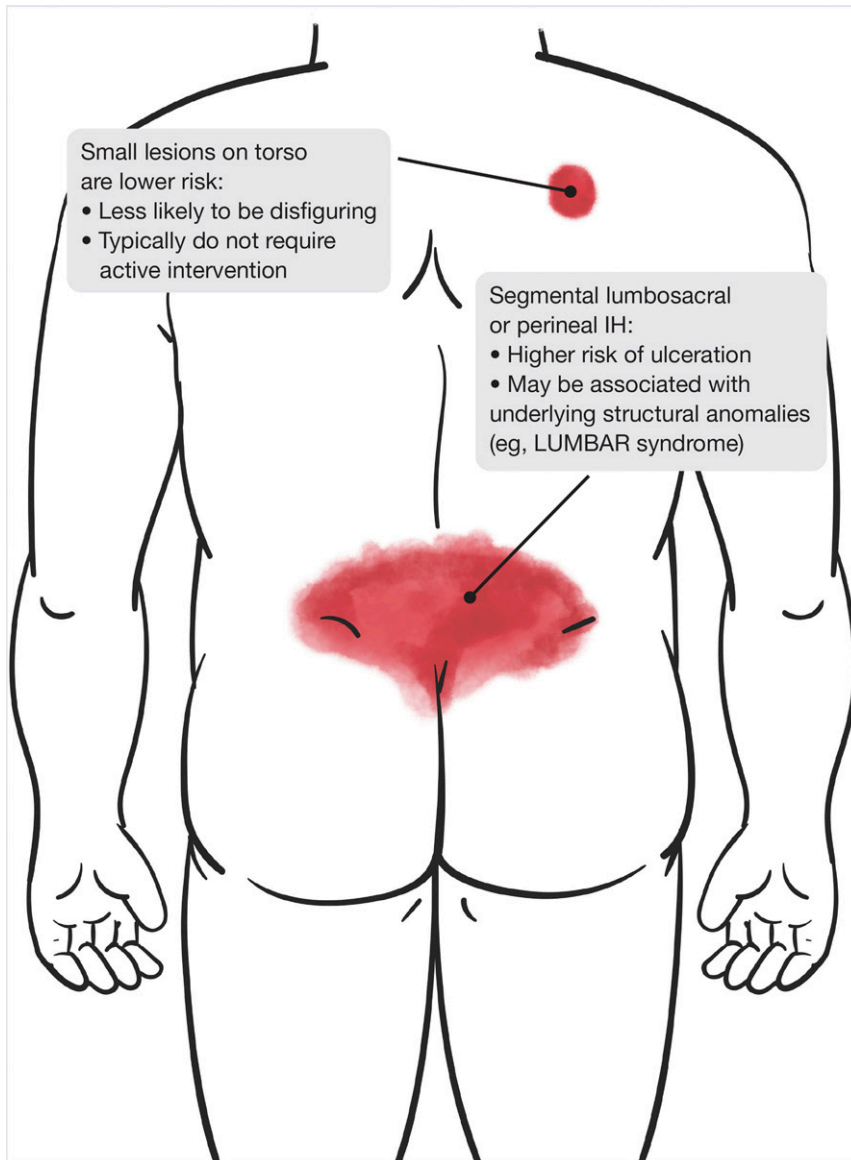
The precise risk of a patient in a primary care setting having permanent skin changes from an IH is not known, but in a referral setting, such changes are seen in 55% to 69% of those with untreated IHS.<sup>19,20</sup> This risk is greatest in IHS with a prominent and thick superficial (strawberry) component, especially when there is a steep step-off (ie, ledge effect) from affected to surrounding normal skin. However, the degree of superficial thickening may be difficult to predict in early infancy. Thus, even in IHS that do not initially appear to be high risk, it is prudent to serially follow lesion growth and establish a means for prompt evaluation if ongoing or rapid growth is observed because this could alter management.

#### Key Action Statement 1B (Table 7)

After identifying an IH as high risk, clinicians should facilitate an evaluation by a hemangioma specialist as soon as possible (grade X, strong recommendation).

The purpose of this statement is to ensure timely evaluation by a





**FIGURE 4**  
IHs involving the posterior trunk.

hemangioma specialist of an IH identified as high risk. IH is a disease with a window of opportunity in which to intervene and prevent poorer outcomes, and this critical time frame for optimizing outcomes can be missed if there are delays in referral or treatment. Recent literature suggests that the presence and growth of IHs is apparent much earlier than originally thought.<sup>21,22</sup> Premonitory findings appear in the skin during early infancy, including localized blanching or macular telangiectatic erythema.<sup>21</sup> As endothelial

cell proliferation continues, the IH enlarges, becomes more elevated, and develops a rubbery consistency. IHs typically have their clinical onset before 4 weeks of age.<sup>21,22</sup>

Several studies have helped to better characterize the proliferative phase of IHs. Although IHs proliferate for variable periods of time and to varying degrees, the most rapid growth of superficial IHs typically occurs between 1 and 3 months' chronological age.<sup>21</sup> IHs reach 80% of their ultimate size by 3 months of age, and the large majority of IHs

have completed growth by 5 months of age.<sup>22</sup> In a study in which parents' photographs were used, early IH growth was found to be nonlinear, with an accelerated period of rapid growth between 5 and 7 weeks of age, and the optimal time for referral or initiation of treatment was 1 month of age, a time far earlier than the time most infants with IHs are typically referred to (or seen by) hemangioma specialists.<sup>21,22</sup>

These observations regarding growth are helpful, but their impact in individual case management is limited by the tremendous degree of disease heterogeneity of IHs. Even for the most experienced clinicians, it can be difficult to predict the degree of IH growth until several weeks to months after the lesion is first noticed. By that time, damage to the dermis and subcutaneous tissues as well as permanent distortion of important anatomic landmarks, such as the nose or lips, may already have occurred.<sup>19,20,44</sup> Hence, decisions regarding intervention must be based on risk stratification, including the age of the child (in anticipation of possible IH growth), health considerations (like prematurity), anatomic site, the size of the IH, any actual or potential complications, and parental preferences. In high-risk IHs, a wait-and-see approach can result in a missed window of opportunity to prevent adverse outcomes.

The rate of growth and ultimate size of an IH can vary dramatically from patient to patient. Predicting the growth of a particular IH is, therefore, difficult and made even more challenging by the minority of lesions that do not exhibit the typical pattern of proliferation followed by slow involution.<sup>23,45</sup> Differences in growth can even be evident when comparing 1 IH to another on the same patient. For example, in patients who have 2 or more IHs, 1 lesion may become large and problematic, and others may barely grow. A subset of IHs known as infantile hemangiomas with minimal or arrested growth (IH-MAGs) typically present as a patch of fine or coarsely reticulated

**TABLE 7** Key Action Statement 1B: After identifying an IH as high risk, clinicians should facilitate an evaluation by a hemangioma specialist as soon as possible (grade X, strong recommendation).

Aggregate Evidence Quality	Grade X
Benefits	Potential for early intervention for IH at a high risk of causing complications
Risks, harm, cost	Potential for delay in intervention if specialist evaluation cannot be arranged promptly or is unavailable in the geographic region; costs associated with specialist evaluation for IH incorrectly identified as high risk
Benefit-harm assessment	The benefits of specialist evaluation outweigh harms and costs
Intentional vagueness	The subcommittee recognizes the multidisciplinary nature of IH management and the diverse level of expertise among individuals in this field. As a result, the definition of a specialist with expertise in vascular birthmarks is vague. The subcommittee also recognizes that the time frame “as soon as possible” is vague.
Role of patient preference	Parental preference should be considered in the decision to see a specialist and in the choice of specialist
Exclusions	IHs not considered high risk
Strength	Strong recommendation
Key references	19–23

telangiectasias, often within a zone of vasoconstriction.<sup>23</sup> They may be mistaken for a port-wine stain or other vascular birthmark. Although they lack the robust proliferative phase characteristic of many IHs, IH-MAGs may be associated with complications, such as ulceration or, if segmental, structural anomalies. The growth trajectory of deeper IHs or those with deeper soft-tissue components also differs from that of localized superficial IHs, often presenting at a later age (eg, 1–2 months and, occasionally, even later).<sup>22</sup>

On the basis of this information, the consensus recommendation of the subcommittee is that patients with IHs identified as high risk have expedited consultation and/or referral to a hemangioma specialist (Supplemental Table 22, Supplemental Fig 11). The type of hemangioma specialist may depend on the specific concern (eg, a hemangioma specialist experienced in airway management will be needed if concern exists for a subglottic hemangioma). Because the time to appointment with a hemangioma specialist may exceed the window of opportunity during which evaluation and possible treatment would be of maximum benefit, those who care for infants with IHs should have mechanisms in place to expedite such

appointments, including the education of office staff to give young infants with high-risk IHs priority appointments. In-person consultation may not always be possible or mandatory. Clinicians may also use telemedicine (either live interactive or store and forward of photographs taken in the office) to assist with triage, evaluation, and management.

#### Key Action Statement 2A (Table 8)

Clinicians should not perform imaging unless the diagnosis of IH is uncertain, there are 5 or more cutaneous IHs, or associated anatomic abnormalities are suspected (grade B, moderate recommendation).

The purpose of this statement is to provide guidance to clinicians regarding the indications for imaging of IHs. Most IHs can be diagnosed clinically. Therefore, imaging of IHs is not indicated for diagnostic purposes unless the lesion has an atypical appearance (ie, the diagnosis is uncertain) or it behaves in a manner that is inconsistent with the expected proliferative growth and involution phases within the expected time frame.<sup>46,47</sup> Noninvasive imaging may be used to monitor response to treatment but typically is not required.<sup>47</sup> Occasionally, differentiating an IH from a highly vascularized malignant tumor

may be difficult. Clinical history, response to therapy, and imaging characteristics considered together are extremely important in this differentiation. In rare cases, a tissue biopsy may be needed to confirm the diagnosis.

Clinicians should use imaging, specifically abdominal ultrasonography, if 5 or more cutaneous IHs are present to screen for hepatic IH.<sup>50</sup> Ultrasonography has a sensitivity of 95% for detection of hepatic hemangiomas and avoids the need for sedation and exposure to ionizing radiation.<sup>46</sup> Early detection of these lesions may lead to improved monitoring and initiation of appropriate treatment, resulting in decreased morbidity and mortality.<sup>8,46,49</sup>

Imaging also is indicated if concern exists for structural anomalies, as would be the case in infants at risk for PHACE syndrome or LUMBAR syndrome. These infants would typically have large (eg, >5 cm in diameter) segmental facial or scalp IHs or segmental IHs of the perineum, gluteal cleft, or lumbosacral area, with or without lower extremity IHs (see KAS 2C for further discussion).<sup>16,17,47,48</sup>

#### Key Action Statement 2B (Table 9)

Clinicians should perform ultrasonography as the initial imaging modality when the diagnosis of IH is uncertain (grade C, weak recommendation).

Ultrasonography (with Doppler imaging) is the initial imaging modality of choice when the diagnosis of IH is uncertain. The study can be performed without sedation and does not necessitate exposure to ionizing radiation, which can be risky, particularly in young infants. On ultrasonography, most IHs appear as a well-defined mass with high-flow vascular characteristics and no arteriovenous shunting (an exception to the latter is that hepatic IHs may exhibit arteriovenous shunting). This may change as the IH involutes and has a more fatty appearance with decreased vascularity.<sup>47,50</sup> Doppler ultrasonography is also the modality of choice when screening for hepatic IHs and can be used to monitor

**TABLE 8** Key Action Statement 2A: Clinicians should not perform imaging unless the diagnosis of IH is uncertain, there are 5 or more cutaneous IHs, or associated anatomic abnormalities are suspected (grade B, moderate recommendation).

Aggregate Evidence Quality	Grade B
Benefits	Avoid the cost, risk of sedation, and radiation associated with unnecessary imaging
Risks, harm, cost	Potential misdiagnosis if imaging is not performed
Benefit-harm assessment	Benefits outweigh harm
Intentional vagueness	None
Role of patient preference	Minimal; when parental anxiety is significant, ultrasonography is a low-cost and low-risk means of confirming the diagnosis
Exclusions	None
Strength	Moderate recommendation
Key references	8,46–48

**TABLE 9** Key Action Statement 2B: Clinicians should perform ultrasonography as the initial imaging modality when the diagnosis of IH is uncertain (grade C, weak recommendation).

Aggregate Evidence Quality	Grade C
Benefits	Select the appropriate imaging study to aid in diagnosis and identify associated abnormalities; avoid ionizing radiation and sedation
Risks, harm, cost	Risk that ultrasonography may not be sufficiently diagnostic or may result in the misdiagnosis of a lesion believed to represent an IH
Benefit-harm assessment	Benefits outweigh harms
Intentional vagueness	None
Role of patient preference	Minimal
Exclusions	None
Strength	Weak recommendation
Key references	47,50

progression of disease and response to treatment.<sup>47</sup>

### Key Action Statement 2C (Table 10)

Clinicians should perform MRI when concerned about associated structural abnormalities (eg, PHACE syndrome or LUMBAR syndrome) (grade B, moderate recommendation).

Imaging for associated structural anomalies is indicated in infants at risk for PHACE syndrome or LUMBAR syndrome. For example, an infant with a large (eg, >5 cm in diameter) segmental facial or scalp IH is at risk for PHACE syndrome, and further evaluation with MRI and/or magnetic resonance angiography (MRA) of the head and neck (including the aortic arch and brachiocephalic origins) and echocardiography is advisable.<sup>16,47</sup>

For patients with segmental IHs of the perineum, gluteal cleft, or lumbosacral area (with or without lower extremity IHs), imaging for LUMBAR syndrome should be considered.<sup>17,48</sup> If there is uncertainty about whether there is a risk of associated structural anomalies, consultation with a hemangioma specialist or other appropriate expert (eg, pediatric neurologist, neurosurgeon, or radiologist) can be helpful to determine if imaging is required and which studies should be performed.

MRI is the optimal imaging modality to define underlying structural abnormalities, and contrast is needed to assess vascular components.<sup>46</sup> MRA can illustrate the vascular anatomy. Thus, MRI and MRA, with and without contrast of the head and neck, are the

best studies to detect PHACE syndrome. MRI does not use ionizing radiation but may require sedation given the duration of the examination.<sup>51,52</sup> The duration of imaging is important because it has been theorized that prolonged (>3 hours) or repeated exposures to general anesthetic and sedative drugs in children younger than 3 years may negatively affect brain development.<sup>53,54</sup> Single, brief exposures are unlikely to have similar effects. As more rapid MRI scanning protocols are developed, the need for sedation may diminish. As an alternative to sedation, young infants fed immediately before an MRI and swaddled may sleep through the procedure. Discussion between the radiologist, ordering clinician, and sedation team is critical to determine the optimal imaging and sedation protocols.<sup>55</sup>

In patients in whom there is a risk of LUMBAR syndrome, spinal ultrasonography (for those with a corrected age of less than 6 months) and Doppler ultrasonography of the abdomen and pelvis can be used as an initial screen for abnormalities.<sup>56–58</sup> Ultimately, however, MRI likely will be required to provide greater definition. For example, if a high suspicion for spinal abnormalities remains despite normal ultrasonography (ie, there are associated markers of dysraphism [eg, sacral dimple, skin appendage, tuft of hair, and lipoma]), MRI is a more sensitive diagnostic modality.<sup>47</sup>

Computed tomography is not the modality of choice for imaging IHs because it involves ionizing radiation, which should be avoided in children, particularly young infants, unless absolutely necessary. Advantages of computed tomography are that it can be rapidly performed and may not require sedation.

## MANAGEMENT: PHARMACOTHERAPY

### Key Action Statement 3A (Table 11)

Clinicians should use oral propranolol as the first-line agent for IHs requiring

**TABLE 10** Key Action Statement 2C: Clinicians should perform MRI when concerned about associated structural abnormalities (eg, PHACE syndrome or LUMBAR syndrome) (grade B, moderate recommendation).

Aggregate Evidence Quality	Grade B
Benefits	Select the appropriate imaging study to aid in diagnosis and identify associated abnormalities; avoid ionizing radiation and sedation
Risks, harm, cost	Risk of sedation or general anesthesia Cost of MRI (but offers greater diagnostic sensitivity)
Benefit-harm assessment	Benefits outweigh harms
Intentional vagueness	None
Role of patient preference	Minimal
Exclusions	None
Strength	Moderate recommendation
Key references	46,51–55

**TABLE 11** Key Action Statement 3A: Clinicians should use oral propranolol as the first-line agent for IHs requiring systemic treatment (grade A, strong recommendation).

Aggregate Evidence Quality	Grade A
Benefits	Improve IH treatment; avoid adverse effects associated with oral steroid therapy
Risks, harm, cost	Occurrence of adverse effects associated with propranolol use (see KAS 3D); medication cost and cost of hospitalization if drug is initiated while infant is an inpatient
Benefit-harm assessment	Benefits outweigh harms
Intentional vagueness	None
Role of patient preference	Parents should be involved in shared decision-making regarding treatment.
Exclusions	Caution (but not exclusion) in infants <5 wk of age, postconceptional age of <48 wk; potential exclusions that require appropriate subspecialty evaluation and/or clearance; evidence of cardiogenic shock or heart failure; sinus bradycardia; heart block greater than first degree; known or suspected PHACE syndrome, including presence or risk of coarctation of the aorta and cerebrovascular anomalies; known asthma and/or reactive airway disease; known hypersensitivity to propranolol
Strength	Strong recommendation
Key references	3,46,59–61

systemic treatment (grade A, strong recommendation).

The purpose of this statement is to advise clinicians that oral propranolol is the current treatment of choice for IHs requiring systemic therapy. After the serendipitous observation of its utility in treating IHs,<sup>59</sup> propranolol, a nonselective antagonist of both  $\beta$ -1 and  $\beta$ -2 adrenergic receptors, has evolved to become the treatment of choice for IHs.<sup>1,3,60</sup>

The precise mechanisms of action of propranolol on IHs are unclear but have been hypothesized to be attributable to vasoconstriction, angiogenesis inhibition,

induction of apoptosis, inhibition of nitric oxide production, and regulation of the renin-angiotensin system.<sup>61–69</sup> Oral propranolol hydrochloride (Hemangeol) was approved by the US Food and Drug Administration (FDA) in March 2014 for use in proliferating IHs requiring systemic therapy. This therapy has now replaced the previous gold standard therapy for threatening IHs, systemic or intralesional corticosteroids.<sup>70</sup>

In the AHRQ review, 18 studies were included in a network meta-analysis of the effectiveness and harms of corticosteroids and  $\beta$ -blockers. The

mean estimate of expected clearance for oral propranolol was 95%, which was superior to other interventions.<sup>46</sup> Ten studies compared propranolol versus another modality, including steroids, pulsed-dye laser (PDL), bleomycin, or other treatments (Table 12). Propranolol was more effective in 3 studies, effectiveness did not differ significantly in 2 other studies, and studies comparing propranolol versus steroids to reduce IH size had conflicting results. Harms are discussed in subsequent KASs, but in the AHRQ analysis, propranolol's superior safety profile is confirmed.

The subcommittee's additional review yielded another 19 studies, 4 of which met inclusion criteria for benefits of interventions (and 9 of which met inclusion criteria for harms of interventions). These 4 studies evaluated propranolol versus placebo or observation. Propranolol was associated with significantly greater clearance of IH compared with the control group in all studies. The strength of evidence (SOE) was considered high for greater effectiveness of propranolol versus placebo or observation. The review also confirmed the superiority of oral propranolol over a variety of comparators. Propranolol was superior to ibuprofen and paracetamol in treating ulcerated hemangiomas<sup>71</sup> and to oral captopril in patients with problematic IHs.<sup>72</sup> In a randomized controlled trial (RCT) of oral propranolol compared with observation for IHs, the overall efficacy of propranolol (defined as excellent, good, or medium response) was 98.97%, compared with 31.25% in the observation group ( $P < .05$ ).<sup>73</sup> Last, Aly et al<sup>74</sup> compared oral propranolol alone versus oral propranolol combined with 2 weeks of "priming" with oral prednisolone. Those in the prednisolone-primed propranolol group showed a statistically superior reduction in IH size at weeks 2, 4, and 8 compared with the propranolol group, but the 6-month response was equivocal for both groups regarding all assessed variables.<sup>74</sup>



**TABLE 12** AHRQ Summary of Comparative Efficacy of Various Treatments for IHs

Drug	Mean Estimate of Expected Clearance, %	95% Bayesian Credible Interval, %
Propranolol	95	88–99
Topical timolol	62	39–83
Intralesional triamcinolone	58	21–93
Oral steroid	43	21–66
Control	6	1–11

Limited data exist on the utility of  $\beta$ -blockers other than propranolol or different delivery mechanisms for propranolol. The AHRQ review included 3 small studies comparing propranolol versus nadolol or atenolol and 1 study comparing oral, intralesional, and topical propranolol. Atenolol and nadolol each demonstrated effectiveness on lesion size, with little difference in efficacy between propranolol and atenolol and greater efficacy of nadolol in 1 small study. The review did not find differences in response with propranolol, nadolol, or atenolol, but the SOE in comparing these was low.<sup>46</sup> The subcommittee's additional review yielded 1 article on oral atenolol for IH, which did not meet the AHRQ inclusion criteria for comparative effectiveness but revealed an excellent treatment response in 56.5% of patients.<sup>75</sup>

### Key Action Statement 3B (Table 13)

Clinicians should dose propranolol between 2 and 3 mg/kg per day unless there are comorbidities (eg, PHACE syndrome) or adverse effects (eg, sleep disturbance) that necessitate a lower dose (grade A, moderate recommendation).

The purpose of this statement is to provide clinicians guidance in dosing oral propranolol for IHs. To date, authors of most studies favor dosing at 2 to 3 mg/kg per day. An RCT of 456 infants compared a placebo versus 1 of 4 propranolol regimens (1 mg/kg per day or 3 mg/kg per day for 3 or 6 months duration). The regimen of 3 mg/kg per day for 6 months was superior, with complete or nearly complete resolution in 60% of patients, compared with 4% of patients in the

placebo arm ( $P < .0001$ ).<sup>76</sup> The FDA approval of propranolol hydrochloride oral solution (4.28 mg/mL) recommends a starting dose of 0.6 mg/kg twice daily, with a gradual increase over 2 weeks to a maintenance dose of 1.7 mg/kg twice daily (3.4 mg/kg per day based on expression as the hydrochloride salt of propranolol). As noted in the AHRQ review, other studies typically reported dosing of 2 to 2.5 mg/kg per day,<sup>46</sup> and a multidisciplinary, multiinstitutional expert panel and a European expert consensus group<sup>1,61</sup> support a starting dose of 1 mg/kg per day and a target dose of 2 to 3 mg/kg per day. Data comparing 2 and 3 mg/kg per day are lacking.

Similarly, available data do not permit evidence-based recommendations on dosing frequency (twice daily versus 3 times daily), but both the FDA and the European Medicine Evaluation Agency labeling is for twice-daily dosing. The site for initiation of propranolol (outpatient versus inpatient) is evolving as more evidence accumulates that cardiovascular and other acute toxicities occur rarely. Although in both the aforementioned consensus articles, initiation in an inpatient setting is favored for infants younger than 8 weeks, those with cardiovascular or respiratory comorbidities, and those with poor social support, FDA labeling sanctions initiation in an outpatient setting for infants >5 weeks' corrected gestational age.

A duration of 6 months of therapy was shown to be superior to 3 months in the large RCT conducted by Léauté-Labrèze et al.<sup>76</sup> In the AHRQ review, the duration of propranolol treatment ranged from 3 to 13 months.<sup>46</sup> Rebound

growth during tapering or after stopping the medication may occur in 10% to 25% of patients and can occur even after 6 months of therapy.<sup>18,76</sup> A large multicenter retrospective cohort study found the greatest risk of rebound occurred in those in whom therapy was discontinued at <12 months of age (and especially before 9 months), and the lowest risk was in those in whom treatment was discontinued between 12 and 15 months of age.<sup>18</sup> Risk factors for rebound growth noted in this study were the presence of mixed or deep morphology and female sex. These observations have led many experts to recommend continuing therapy until at least 1 year of age.

Dosing may need to be modified in certain situations. Patients with PHACE syndrome may have an increased risk of stroke, and this risk may be greater if certain neurovascular anomalies are present.<sup>16</sup> In patients who merit systemic IH therapy, the benefits and risks must be carefully weighed. Evaluation with MRI and/or MRA of the head and neck and echocardiography should be performed before or shortly after the initiation of therapy.<sup>61</sup> If patients who are at high risk require treatment with propranolol, it is advisable to use the lowest effective dose, slowly titrate the dose, and administer the drug 3 times daily (to minimize abrupt changes in blood pressure); comanagement with a pediatric neurologist is recommended.<sup>1,16,61,77</sup> Other patients who may require lower propranolol doses include those with progressive IH ulceration while receiving therapy and those who experience adverse effects (such as sleep disturbances).

### Key Action Statement 3C (Table 14)

Clinicians should counsel that propranolol be administered with or after feeding and that doses be held at times of diminished oral intake or vomiting to reduce the risk of hypoglycemia (grade X, strong recommendation).

**TABLE 13** Key Action Statement 3B: Clinicians should dose propranolol between 2 and 3 mg/kg per day unless there are comorbidities (eg, PHACE syndrome) or adverse effects (eg, sleep disturbance) that necessitate a lower dose (grade A, moderate recommendation).

Aggregate Evidence Quality	Grade A
Benefits	The recommended doses have been associated with high clearance rates of IH
Risks, harm, cost	Response rates for higher or lower doses have not been well studied
Benefit-harm assessment	Benefits outweigh harms
Intentional vagueness	None
Role of patient preference	Parents will be involved in the decision about dosing in the setting of PHACE syndrome or the occurrence of adverse effects
Exclusions	See KAS 3A; dosing may be modified if comorbidities exist
Strength	Moderate recommendation
Key references	1,46,61,76

**TABLE 14** Key Action Statement 3C: Clinicians should counsel that propranolol be administered with or after feeding and that doses be held at times of diminished oral intake or vomiting to reduce the risk of hypoglycemia (grade X, strong recommendation).

Aggregate Evidence Quality	Grade X
Benefits	Reduce the likelihood of adverse reactions
Risks, harm, cost	Risk that parents will decline therapy because of concerns about potential medication adverse effects
Benefit-harm assessment	Benefits outweigh harms
Intentional vagueness	None
Role of patient preference	None
Exclusions	None
Strength	Strong recommendation
Key references	46,60,61,76,78–80

The purpose of this statement is to reinforce the importance of administering oral propranolol with feeds and of holding therapy at times of restricted oral intake to prevent hypoglycemia and hypoglycemia-induced seizures. The association between hypoglycemia and propranolol in infants and children is well established and is related to effects on glycogenolysis and gluconeogenesis.<sup>78</sup>  $\beta$ -blockade by propranolol can affect these processes, and infants and children may be particularly susceptible to this effect.<sup>78,79</sup> Early clinical features of hypoglycemia in infants, which may be masqueraded by  $\beta$ -adrenergic blockade, include sweating, tachycardia, shakiness, and anxious appearance, whereas later manifestations (signs of neuroglycopenia) may include lethargy, poor feeding, apnea, seizures, stupor, and loss of consciousness.<sup>79</sup>

The AHRQ review identified 24 comparative studies (4 good quality) and 56 case series (4 good quality) that reported harms data of  $\beta$ -blockers for IHs. Rates of clinically important harms (hypoglycemia, hypotension, bradycardia, and bronchospasm) varied widely, and the authors assigned a moderate SOE for the association of propranolol with both clinically important and minor harms (with high study limitations).<sup>46</sup> Harms overall did not cause treatment discontinuation.

The subcommittee's additional review yielded 8 reports that met inclusion criteria for harms regarding oral propranolol for treatment of IHs. These reports provided more detailed information about the occurrence of hypoglycemia. Three of the 8 articles reported hypoglycemia; these articles included 1021 patients, 10 of whom

experienced hypoglycemia (3 of these suffered hypoglycemic seizures in the setting of viral gastroenteritis and poor oral intake).<sup>80–82</sup>

In a large meta-analysis of oral propranolol for IHs not included in the AHRQ review, adverse events were reported for 1945 of 5862 patients who were treated.<sup>60</sup> The investigators identified 24 cases of hypoglycemia and 2 cases of hypoglycemic seizures among 3766 patients who were treated with propranolol from their literature review (some of whom are included in aforementioned studies). Of the 14 events with resolution details, 9 led to dose adjustment or temporary discontinuation of propranolol, and 1 led to permanent discontinuation of treatment. The authors mention that 1 case of hypoglycemic seizure was related to overdose, and the other was associated with diminished oral intake because of infection.<sup>60</sup>

Although the risk of hypoglycemia must be considered when prescribing oral propranolol for IHs, routine glucose screening is not indicated.<sup>1,61</sup> Hypoglycemia occurs infrequently and can be minimized with appropriate education of caregivers on the importance of administering propranolol during or immediately after a feeding and of temporarily withdrawing therapy during periods of fasting (including poor oral intake because of illness or before general anesthesia) or vomiting.<sup>60</sup> Prolonged fasting should be avoided, and parents should be advised that hypoglycemia becomes more likely after  $\geq 8$  hours of fasting in infants and young children.<sup>83,84</sup>

### Key Action Statement 3D (Table 15)

Clinicians should evaluate patients for and educate caregivers about potential adverse effects of propranolol, including sleep disturbances, bronchial irritation, and clinically symptomatic bradycardia and hypotension (grade X, strong recommendation).

The purpose of this statement is to increase awareness of potential propranolol-associated adverse effects other than hypoglycemia for clinicians

and caregivers of patients receiving this medical therapy for IHs. Propranolol has been used in pediatric patients for decades, primarily in an off-label fashion. In young infants, it has been used primarily for cardiac disorders and for the treatment of thyrotoxicosis at doses up to 6 to 8 mg/kg per day. Despite this use, many pediatricians will be unfamiliar with the drug, and reviewing its possible adverse effects is warranted.

As noted in the discussion of KAS 3C, the AHRQ review identified a number of adverse effects during propranolol treatment. Adverse effects most frequently reported included sleep disturbances, cold extremities, gastrointestinal symptoms, bronchial irritation (classified as hyperreactivity, bronchospasm, bronchiolitis, and cold-induced wheezing), and a decrease in heart rate or blood pressure. Rates of clinically important harms (hypoglycemia, hypotension, bradycardia, and bronchospasm) varied widely across the studies, and the authors assigned a moderate SOE for the association of propranolol with both clinically important and minor harms (with high study limitations).<sup>46</sup> Overall, harms did not cause treatment discontinuation.

Our additional review yielded 8 reports that met inclusion criteria for harms of interventions. Sleep disturbance, sleeping disorders, agitation during the night, and nightmares or night terrors were mentioned in 6 of 8 reports and occurred in 2% to 18.5% of patients who were treated.<sup>80,82,85,86,89,90</sup> In 3 of these 6 reports, propranolol treatment was modified (reduction in dosage, earlier-evening dosing, and early discontinuation of therapy) in response to these effects.<sup>80,82,85</sup>

In 4 reports, possible respiratory adverse effects were mentioned, including labored breathing in 0.9%,<sup>86</sup> breathing-related problems in 11.5%,<sup>89</sup> respiratory disorders in 3.4%,<sup>80</sup> and wheezing or bronchiolitis in 12.9%.<sup>82</sup> In 3 of these series treatment modifications in response to the

**TABLE 15** Key Action Statement 3D: Clinicians should evaluate patients for and educate caregivers about potential adverse effects of propranolol, including sleep disturbances, bronchial irritation, and clinically symptomatic bradycardia and hypotension (grade X, strong recommendation).

Aggregate Evidence Quality	Grade X
Benefits	Recognition of adverse effects of propranolol treatment
Risks, harm, cost	Risk of caregivers declining medical therapy because of concern about potential adverse effects
Benefit-harm assessment	Benefits outweigh harms
Intentional vagueness	None
Role of patient preference	None
Exclusions	None
Strength	Strong recommendation
Key references	3,46,61,76,80,85–88

respiratory events were mentioned, including temporary discontinuation of therapy<sup>80,82</sup> and decreased dosage of propranolol.<sup>89</sup>

Although bradycardia and hypotension are known to accompany propranolol-associated  $\beta$ -receptor blockade, both tend to be mild and asymptomatic in children treated for IHs who have no preexisting cardiac comorbidities.<sup>3,84,87,88,91–93</sup> In the subcommittee's review, only 1 of the 8 reports mentioned hypotension or bradycardia as an adverse event, with 1 of 906 patients (0.1%) exhibiting bradycardia and 2 of 906 exhibiting asymptomatic hypotension.<sup>80</sup> The use of pretreatment electrocardiography (ECG) is controversial. Although this initially was advocated by some, several studies have revealed no actionable findings with continuous ECG monitoring, and researchers have questioned its value.<sup>61,91</sup> FDA guidelines for patient monitoring do not include routine ECG.<sup>61</sup> In their consensus recommendations, Drolet et al<sup>61</sup> suggest ECG screening only (1) in infants with a baseline heart rate below normal for age, (2) in infants with a family history of congenital heart conditions or arrhythmias or with a maternal history of connective tissue disease, or (3) when there is a history of arrhythmia or one is auscultated during examination. Currently, the FDA-approved administration guidelines mirror those used in the pivotal clinical

trial, with a recommendation for in-office intermittent heart rate and blood pressure monitoring for 2 hours after the first dose of propranolol or for increasing the dose for infants 5 weeks' adjusted gestational age or older.<sup>76</sup> Monitoring for those who are younger or for those with other comorbidities should be individualized and may require brief hospitalization for medication initiation. These recommendations may change over time as more information becomes available now that the medication is in widespread use.

Theoretical concerns about adverse effects of propranolol on brain development have been raised. As a highly lipophilic  $\beta$ -blocker, propranolol has the ability to cross the blood brain barrier.<sup>94</sup> Adult studies have revealed impairments in short- and long-term memory, psychomotor function, and mood, and prenatal  $\beta$ -blockade has been associated with long-term cognitive impairment,<sup>95,96</sup> leading some to question the potential central nervous system effects of this agent when used to treat young children with IHs.<sup>97,98</sup> In the large prospective randomized propranolol trial conducted by Léauté-Labrèze et al,<sup>76</sup> no appreciable neurodevelopmental differences were noted between the propranolol-treated groups and the placebo group at week 96. Four other studies addressing development in infants treated with propranolol for

IHs have yielded conflicting results. In 2 case series (with a total of 272 patients), gross motor delay was reported in 4.8% to 6.9%.<sup>99,100</sup> In contrast, a case series of 141 patients found psychomotor delay in only 1 child, and a controlled trial of 82 children found no increase in the rate of developmental concerns as assessed by the Ages and Stages Questionnaire.<sup>101,102</sup> Although these latter studies are reassuring, further prospective psychometric studies of children treated with oral propranolol for IHs may be warranted.

### Key Action Statement 3E (Table 16)

Clinicians may prescribe oral prednisolone or prednisone to treat IHs if there are contraindications or an inadequate response to oral propranolol (grade B, moderate recommendation).

The purpose of this statement is to highlight the utility of systemic corticosteroid therapy for IHs in certain settings, such as for patients in whom  $\beta$ -blocker therapy is contraindicated, poorly tolerated, or ineffective. Systemic therapy with corticosteroids was considered the standard of care for several decades before being supplanted by oral propranolol.

In the AHRQ review, oral steroids had a mean estimate of expected clearance of 43% (Table 12).<sup>46,103</sup> The AHRQ report identified 24 studies (3 RCTs, 1 cohort study, and 20 case series) reporting outcomes and/or harms after corticosteroid use in children with IHs. One RCT was judged as good, 1 as fair, and 1 as poor quality, and the cohort study was judged as fair quality (all case series were judged as poor quality for harms reporting). The steroids studied varied in terms of dose, type, route of administration, and patient ages. Children in steroid treatment arms typically had modest improvement in lesion size, but outcomes were difficult to compare given differences in scales. The optimal dosing of systemic corticosteroids for IHs remains unclear. Dose ranges of prednisone or prednisolone reported

most frequently in the literature are between 2 and 5 mg/kg per day,<sup>3,70,104–106</sup> and most consider optimal dosing to be 2 to 3 mg/kg per day. Typical protocols include treating at full dose for 4 to 12 weeks followed by a gradual taper and completion of therapy by 9 to 12 months of age.<sup>3,70,105,106</sup> Some have advocated for shorter treatment durations (1–6 weeks), with multiple intermittent courses as needed.<sup>107</sup>

In the AHRQ review, steroids were consistently associated with clinically important harms, including Cushingoid appearance, infection, growth retardation, hypertension, and mood changes. The authors considered the SOE to be moderate for the association of steroids with clinically important harms.<sup>46</sup>

### Key Action Statement 3F (Table 17)

Clinicians may recommend intralesional injection of triamcinolone and/or betamethasone to treat focal, bulky IHs during proliferation or in certain critical anatomic locations (eg, the lip) (grade B, moderate recommendation).

The purpose of this statement is to highlight the utility of intralesional corticosteroid injection for certain IH subsets. Numerous studies have reported success in the use of steroid injections for IHs, demonstrating it to be safe and effective.<sup>108–114</sup> This modality is most often reserved for IHs that are relatively small and well localized where proliferation is resulting in increased bulk and threatening anatomic landmarks (eg, the lip or nose). Larger or more extensive lesions are poorer candidates for this treatment modality given the larger volume of steroids necessary (and the inherent systemic risks), the difficulty of obtaining even distribution throughout the tumor, and the potential for local complications in lesions that are mostly flat or superficial.<sup>3</sup> Most studies have used triamcinolone either alone or in conjunction with betamethasone, with injections given on average every 4 to 6 weeks (but with wide variability). Repeat

injections are often administered, with the number used ranging in most reports from 1 to 7.<sup>109–112</sup>

The AHRQ review found that intralesional triamcinolone had a mean estimate of expected clearance of 58% (Table 12).<sup>46,103</sup> Overall, the SOE was low for intralesional steroids having a modest effect relative to control, with wide confidence bounds.<sup>46</sup> The subcommittee's additional search yielded 1 report that met inclusion criteria for benefits of interventions as a comparative study. This was a retrospective review of patients with periocular IHs treated with oral propranolol, who were compared with a cohort treated with intralesional corticosteroid injection. Both groups showed a reduction in astigmatism over 12 months, and neither experienced significant adverse effects necessitating dose reduction or treatment cessation.<sup>115</sup> The authors concluded that oral propranolol (given its efficacy and safety profiles) has emerged as the treatment of choice for periocular IHs requiring therapy.<sup>115</sup>

Steroids (oral and intralesional forms were grouped together in the AHRQ harms analysis) were consistently associated with clinically important harms, including Cushingoid appearance, infection, growth retardation, hypertension, and mood changes. The authors considered the SOE to be moderate for the association of steroids with clinically important harms. The most commonly reported complications associated with intralesional steroid injection for IHs are transient Cushingoid features, failure to thrive, and local skin complications.<sup>109–112</sup> Local complications may include fat and/or dermal atrophy and pigmentary changes.<sup>108–110</sup> Adrenal suppression is infrequently reported in association with intralesional steroid injections but has been observed when large doses (eg, >4 mg/kg) have been administered.<sup>116,117</sup> There have been rare reports of central retinal artery embolization, usually after injection into IHs of the upper eyelid, likely related to high injection pressures and/or volumes.<sup>118–121</sup>



**TABLE 16** Key Action Statement 3E: Clinicians may prescribe oral prednisolone or prednisone to treat IHs if there are contraindications or an inadequate response to oral propranolol (grade B, moderate recommendation).

Aggregate Evidence Quality	Grade B
Benefits	Modest benefit in IH clearance; medication cost is low
Risks, harm, cost	Clinically important harms; cost associated with the evaluation and treatment of adverse effects
Intentional vagueness	None
Benefit-harm assessment	Benefits outweigh harms
Role of patient preference	Shared decision-making regarding treatment
Exclusions	None
Strength	Moderate recommendation
Key references	46,70,103

**TABLE 17** Key Action Statement 3F: Clinicians may recommend intralesional injection of triamcinolone and/or betamethasone to treat focal, bulky IHs during proliferation or in certain critical anatomic locations (eg, the lip) (grade B, moderate recommendation).

Aggregate Evidence Quality	Grade B
Benefits	Modest benefit in IH clearance
Risks, harm, cost	Clinically important harms; cost of medication, visits for injection; risk of anesthesia if used
Benefit-harm assessment	Benefits outweigh harms in selected clinical situations
Intentional vagueness	None
Role of patient preference	Shared decision-making regarding route of drug delivery
Exclusions	None
Strength	Moderate recommendation
Key references	3,46,103,108–112

### Key Action Statement 3G (Table 18)

Clinicians may prescribe topical timolol maleate as a therapy for thin and/or superficial IHs (grade B, moderate recommendation).

The purpose of this statement is to highlight the potential utility of topical timolol in treating thin and/or superficial IHs. Topical timolol maleate, a nonselective  $\beta$ -adrenergic receptor inhibitor, has been used in the treatment of pediatric glaucoma as a first-line agent for several decades.<sup>122,127,128</sup> Treatment of IHs with ophthalmic timolol maleate was initially reported in 2010, and since that time, there have been many reports (including some with hundreds of patients), as well as an RCT, with positive findings.<sup>40,122–125,129–134</sup> On the basis of these reports showing efficacy with minimal adverse effects, timolol is increasingly being used for thin and superficial IHs, and many centers report

that their use of timolol exceeds that of oral  $\beta$ -blockers.<sup>135</sup>

In the AHRQ review, 2 RCTs and 4 cohort studies were included. Topical timolol had a mean estimate of expected clearance of 62% (Table 12).<sup>46,103</sup> Timolol was significantly more effective than observation or a placebo in 3 studies; 1 study comparing topical imiquimod with timolol did not demonstrate superiority of either agent but was found to have insufficient SOE.<sup>46</sup> Our subsequent review found 3 further reports meeting criteria for efficacy, including 1 study comparing timolol to an ultrapotent corticosteroid and 2 other studies of timolol alone.<sup>40,133,134</sup> In the largest of these, a multicenter retrospective cohort study of 731 patients, most infants were treated with the 0.5% gel-forming solution. The study reveal improvement in nearly 70% of patients treated for 1 to 3 months and in 92.3% of patients who received

6 to 9 months of therapy. The greatest improvement was in color; however, with a longer duration of treatment, improvement in size, extent, and volume were also observed. Best responses were observed in thinner superficial IHs (ie, <1 mm thick) versus mixed or deep IHs. The large majority of infants studied were 6 months or younger at time of initiation of treatment, and 41% were  $\leq 3$  months of age. This suggests that early topical timolol treatment may also inhibit IH growth. Only 7% of infants required subsequent treatment with a systemic  $\beta$ -blocker.<sup>40</sup>

Although pharmacokinetic data are limited, evidence suggests that timolol maleate can be detected in the blood or urine of at least some infants treated topically.<sup>126,136</sup> Additional pharmacokinetic studies are needed given occasional reports of systemic toxicity.<sup>137–139</sup> It should be noted that timolol is significantly more potent than propranolol, and topical application avoids first-pass liver metabolism, as would occur with an oral  $\beta$ -blocker.<sup>127</sup> Pending the results of ongoing studies, these factors should lead to caution when using timolol, especially if prescribing more than 1 drop twice daily or when treating preterm or young infants.

The AHRQ report emphasized that there were far more reports of harms with oral  $\beta$ -blockers than with timolol but did note 1 report of shortness of breath and insomnia.<sup>46</sup> Subsequent to that report, tolerability data have been reassuring overall, but some adverse events have been reported.<sup>40,122,124,125,131–134,140</sup> In the large cohort study of 731 patients conducted by Püttgen et al,<sup>40</sup> adverse events were noted in 3.4% of patients and included local irritation (nearly half of the adverse events) and bronchospasm (in 3 patients); no cardiovascular events were reported. No adverse events were significant enough to necessitate drug discontinuation.<sup>40</sup> In a retrospective case series of 30 children with ulcerated IHs treated with topical timolol maleate 0.5% gel-forming solution and evaluating for

**TABLE 18** Key Action Statement 3G: Clinicians may prescribe topical timolol maleate as a therapy for thin and/or superficial IHs (grade B, moderate recommendation).

Aggregate Evidence Quality	Grade B
Benefit	Modest benefit in IH clearance
Harm	Low but possible risk of local irritation, sleep disturbance, cold extremities, bronchospasm, and bradycardia, with more caution needed in preterm infants and those without intact skin (ie, ulceration)
Cost	Cost of medication
Benefits-harm assessment	Benefits outweigh harms
Value judgments	None
Role of patient preference	Parents have a significant role in decision-making regarding the desire to treat small superficial lesions for which timolol may be effective
Intentional vagueness	None
Exclusions	Lesions that are large size, significantly elevated, or life-threatening
Strength	Moderate recommendation
Key references	40,46,85,122–126

adverse events, sleep disturbance was observed in 1 infant (who was treated simultaneously with oral propranolol and topical timolol) and a single episode of cold extremities was reported in another. The remainder had no reported adverse events.<sup>141</sup> Bradycardia, both symptomatic and asymptomatic, was reported in 4 of 22 young and preterm infants given timolol for IHs. Two infants had bradycardia that was mild and asymptomatic, but in 2 (both of whom were born preterm and weighed less than 2500 g at initiation of therapy) there were associated symptoms.<sup>126</sup> To address concerns regarding potential percutaneous absorption and toxicity, many authors have advocated using limited amounts of medication (eg, 1 drop 2–3 times per day),<sup>40</sup> and some have cautioned against application to ulcerated lesions.<sup>127</sup>

## SURGICAL MANAGEMENT

### Key Action Statement 4 (Table 19)

Clinicians may recommend surgery and laser therapy as treatment options in managing selected IHs (grade C, moderate recommendation).

The purpose of this statement is to support surgery and laser therapy as treatment options for selected IHs, although it is recommended that decisions regarding their use should be

made in consultation with a hemangioma specialist, especially in young infants. With the advent of  $\beta$ -blocker therapy, surgical and laser approaches are used less frequently.

In general, surgical interventions are not performed in infancy. During this time, anesthetic risks are of greater concern, and the tumor is highly vascular, posing a higher risk of blood loss, iatrogenic injury, and an inferior outcome.<sup>142,143,145</sup>

In certain locations, such as the lip and nasal tip, the final cosmetic result is superior when growth of the lesion has ceased and the number of surgical interventions can be kept to a minimum. Furthermore, there is no psychosocial urgency to improve a deformity caused by IHs in this age group because long-term memory and self-esteem are not established until later in childhood.<sup>143,146–148</sup> There are certain clinical situations, however, in which early surgery can be an important treatment option. These include IHs that ulcerate, obstruct or deform vital structures (such as the airway or orbit), or involve aesthetically sensitive areas. In these circumstances, surgery may be indicated when (1) the lesion has failed to improve with local wound care and/or pharmacotherapy; (2) the lesion is well localized, and early surgery will simplify later reconstruction (eg, a prominent IH

involving the ear or eyelid [causing ptosis]); (3) the lesion is well localized in an anatomically favorable area; or (4) resection is likely to be necessary in the future, and the resultant scar would be the same.<sup>142,143,145</sup> The decision to undertake surgery during infancy should take into consideration current knowledge of the risks of general anesthesia in this age group.<sup>53–55</sup>

Surgery also is an important treatment option for IHs that, despite involution, have left residual skin changes (eg, thinned skin, scar, fibrofatty tissue, telangiectasias, and/or anatomic deformities in areas such as the nose, ear, or lip).<sup>19,20,143</sup> In most cases, deferring surgery until the child is 3 to 5 years of age is reasonable because: (1) the lesion may resolve significantly without leaving a deformity that necessitates intervention; (2) the tumor is smaller than it was during infancy, and thus, the operation is often easier, and the resultant scar may be smaller; and (3) the IH primarily is adipose tissue instead of blood vessels, and thus, the operation is safer.<sup>142,143,145</sup> However, it is usually unnecessary to wait longer than 3 to 5 years of age because the previously accepted adage that 50% of IHs complete involution by 5 years of age, 70% by 7 years of age, and 90% by 9 years of age has proven to be incorrect.<sup>19,143,149</sup> In fact, most IHs do not improve significantly after 3 to 4 years of age.<sup>20,143</sup> Moreover, performing surgery at this earlier age can be beneficial in minimizing stigma and impact on a child's self-esteem.<sup>143</sup> There is less urgency to correct a residual deformity in an area that is concealed by clothing (eg, a lesion on the trunk). Some parents may elect to wait until the child is older and able to help in decision-making, especially if the reason for surgery is the management of less disfiguring skin changes.<sup>143</sup>

### Laser Management

PDL has been used for several decades to treat IHs. The AHRQ review noted that most studies that were reviewed

**TABLE 19** Key Action Statement 4: Clinicians may recommend surgery and laser therapy as treatment options in managing selected IHs (grade C, moderate recommendation).

Aggregate Evidence Quality	Grade C
Benefits	Early surgical intervention after infancy corrects residual deformities before the child's self-esteem develops
Risks, harm, cost	Risk of surgical complications and general anesthesia; costs associated with operative intervention, anesthesia, and postoperative care
Benefits-harm assessment	Preponderance of benefit
Intentional vagueness	None
Role of patient preference	Significant
Exclusions	Children with a nonproblematic IH
Strength	Moderate recommendation
Key references	20,142–144

evaluated PDL (as opposed to other lasers) and examined heterogeneous end points (the latter factor limiting the ability to draw conclusions). However, there is low SOE that PDL is more effective in reducing IH size when compared with observation.<sup>46</sup> There is evidence that PDL is superior to other lasers. In contrast, there is wide recognition that PDL is effective and safe in removing residual macular erythema and superficial telangiectasias in involuting or involuted IHs, but it often requires several treatments to achieve optimal results.<sup>1,142</sup> Other lasers, such as erbium-yttrium-aluminum-garnet, have been reportedly effective in ameliorating textural changes in small case series.<sup>150</sup> Harms associated with laser therapy that were identified in the AHRQ review included skin atrophy, bleeding, scarring, ulceration, purpura, and pigmentation changes.<sup>46</sup> The AHRQ review also noted that most studies of lasers reviewed evaluated lasers as a first-line treatment, a practice that is less common since the advent of  $\beta$ -blocker treatment.

There is controversy regarding whether PDL should be used to treat IHs early in infancy (ie, during the proliferative phase). Several case reports and case series have revealed an increased risk of ulceration, scarring, and hypopigmentation when PDL is used during this period.<sup>1,144,151</sup> Moreover, PDL penetrates only into the superficial dermis, and thus, although

redness may be diminished, deeper elements of the IH (that increase the risk of residual skin changes) are not affected.<sup>144,152,153</sup>

Some authors advocate for using PDL as a treatment of ulceration. However, evidence supporting the use of PDL for this indication comes from case reports and small case series. Propranolol has been associated with faster healing of ulceration when compared with laser therapy and antibiotics.<sup>46</sup>

## PARENT EDUCATION

### Key Action Statement 5 (Table 20)

Clinicians should educate parents of infants with an IH about the condition, including the expected natural history, and its potential for causing complications or disfigurement (grade X, strong recommendation).

The purpose of this statement is to ensure that parents are knowledgeable about their child's IH and to provide clinicians with a framework for educating those parents about IHs. The information provided by clinicians should be as specific to the patient's IH as possible (eg, indicating whether and why an IH is low risk and, thus, likely to cause no problems or sequelae or is potentially high risk and requires urgent evaluation or treatment; Table 3, illustrated in

Figs 2–4, Supplemental Table 22, and Supplemental Fig 11).

## IHs That Do Not Raise Concern

In a primary care setting, the majority of IHs are not problematic and require no active intervention (ie, are low risk; Supplemental Table 22, Supplemental Fig 11). However, given their appearance, even nonproblematic (that is, low-risk) IHs may cause significant parental anxiety and concern. These emotions may be amplified by information gleaned from Internet searches that show photographs emphasizing the more severe end of the disease spectrum as well as public reactions to the child's IH if the lesion is located at a site not easily covered by clothing.<sup>42,155,156</sup> Formal educational efforts can reduce parental anxiety and enhance comfort with a plan to observe the IH for any unexpected or worrisome changes.<sup>154</sup>

Parents should be educated about the natural history of IHs. Specifically, they may be advised that, although growth characteristics vary from case to case, most superficial IHs have a maximum growth potential between 1 and 3 months of age<sup>3,21,157</sup> and that the majority of growth is complete by 5 months of age.<sup>22</sup> Deeper IHs may have a slightly later onset and a more prolonged duration of growth. During the period of growth, clinicians should encourage parents to call, schedule an office visit, or share photographs of the IH with them to reassess if concerns exist about the lesion's appearance, unexpectedly rapid growth, ulceration, bleeding, or pain, all findings that indicate that a lesion is no longer low risk.

Parents should be advised that by age 5 to 12 months, most IHs have stopped growing and are beginning to involute. For IHs with a superficial component, this appears as a gradual change in color from red to milky-white or gray. Lesions gradually flatten and shrink from the center outward. Involution proceeds more slowly than growth. Newer studies have demonstrated that 90% of IH involution is complete by 4 years of age.<sup>20,143</sup> This

is in contrast to traditional teaching that involution proceeds at 10% per year (ie, 50% of IHs resolve by 5 years of age and 90% by 9 years of age). Parents should be advised that even after involution, residual changes, such as telangiectasias, redundant skin, or a scar,<sup>3,19</sup> may be left. It is usually possible to tell whether such changes are going to persist by 4 years of age, and if concerning, consultation for management of these skin changes, particularly laser or surgical treatment, may be pursued.

A collection of serial photographs can be useful to demonstrate to parents the natural history of IHs and the process of spontaneous involution.<sup>154</sup> Such photos are available on the Hemangioma Investigator Group (<https://hemangiomaeducation.org/>) and Yale Dermatology (<https://www.yalemedicine.org/conditions/infantile-hemangioma/>) Web sites. Information sheets (ie, handouts) are available from the Society for Pediatric Dermatology Web site (<http://pedsderm.net/>) under the “For Patients and Families” tab, and adapted versions of their hemangioma patient information and propranolol sheets are included in the What Are Hemangiomas? Propranolol for Hemangiomas, and Medication Information sections of the Supplemental Information. A video for parents is also available on the Society for Pediatric Dermatology Web site (<https://pedsderm.net/for-patients-families/patient-education-videos/#InfantileHemangiomas>). Information also is available from the AHRQ (<https://effectivehealthcare.ahrq.gov/topics/infantile-hemangioma/consumer/>),<sup>158</sup> and answers to frequently asked questions are available on the Hemangioma Investigator Group and Yale Dermatology Web sites.

### IHs That May Be Problematic

When confronted with a potentially problematic IH (ie, high risk; Table 3; illustrated in Figs 2–4, Supplemental Table 22, and Supplemental Fig 11), primary care clinicians are encouraged

**TABLE 20** Key Action Statement 5: Clinicians should educate parents of infants with an IH about the condition, including the expected natural history, and its potential for causing complications or disfigurement (grade X, strong recommendation).

Aggregate Evidence Quality	Grade X
Benefits	Promotes parent satisfaction and understanding, may reduce medication errors, may improve clinical outcomes
Risks, harm, cost	May increase parental anxiety because of the need to administer medication; time spent in education, may increase health care costs because of the need for follow-up visits
Benefit-harm assessment	Benefits outweigh harms
Intentional vagueness	None
Role of parental preferences	Essential; shared decision-making regarding the need for treatment is vital
Exclusions	None
Strength	Strong recommendation
Key references	21,22,154

to consult promptly with a hemangioma specialist unless they have the experience and knowledge to manage such patients independently. Because IH proliferation may occur early and be unpredictable and because there is a window of opportunity for optimal treatment, caregivers can be advised that consultation should take place in a timely manner. Unfortunately, this does not always occur. Although caregivers first notice lesions by 1 month of age (on average, at 2 weeks) and the ideal time for consultation may be 4 weeks of age, 1 study found that the mean age at presentation to a dermatologist was 5 months, by which time most growth is complete.<sup>21,22</sup>

Recognizing that it may be difficult to obtain an appointment with a hemangioma specialist in a timely manner, caregivers and clinicians may need to advocate on behalf of the infant. In settings where a hemangioma specialist is not readily available, telemedicine triage or consultation, using photographs taken by caregivers or the clinician, can be helpful. In 1 academic center in Spain, teledermatology triage reduced the age at first evaluation of an infant with an IH from 5.9 to 3.5 months.<sup>159</sup>

Once the hemangioma specialist has an opportunity to meet with parents and evaluate the infant, a

discussion about management can take place. If medical treatment is recommended, the specialist will educate parents about the medication and its dosing, its possible adverse effects, and the expected duration of treatment. If the medication selected is propranolol, as often is the case, a patient information sheet (such as that developed by the Society for Pediatric Dermatology or that provided in the What Are Hemangiomas? and Propranolol for Hemangiomas sections of the Supplemental Information) or information from the article by Martin et al<sup>160</sup> may be provided. For families unable to travel to see a hemangioma specialist, collaborative care may be considered. The hemangioma specialist can evaluate serial photographs and provide the primary care clinician with guidance on treatment. In this case, the primary care clinician will assume a more active role in parent education.

### CHALLENGES TO IMPLEMENTING THIS CPG

Several potential challenges exist to implementing this CPG. The first is the dynamic nature of individual IHs with a period of rapid growth, the degree of which can be difficult to predict, particularly in young infants. There are no surrogate markers or imaging studies that have been shown to reliably predict growth. Hence, frequent



in-person visits or a review of parental photos may be needed, especially in infants younger than 3 to 4 months. However, this may be complicated by the frequency and timing of well-child visits during this period. After the first-week visit, an infant who is well, has regained birth weight, and has parents who are experienced caregivers may not be seen again until 2 months of age. As noted by Tollefson and Frieden,<sup>21</sup> most superficial IHs have accelerated growth between 5 and 7 weeks of age, and 4 weeks of age may be the ideal time for referral if high-risk features are present. Thus, the most dramatic IH growth (and potentially permanent skin changes) may occur during a time when an infant is not scheduled to see a health care provider. Although awareness of this issue does not justify altering the interval of well-child visits for all infants, it heightens the need for more frequent monitoring in those with possible or definite IHs. Prompt evaluation, either in-person or via photographs, is warranted for any infant reported by parents to have a changing birthmark during the first 2 months of life.

A second challenge is the wide heterogeneity of IHs in terms of size, location, patterns of distribution (ie, segmental versus localized), and depth (ie, superficial, mixed, or deep). This heterogeneity, particularly when combined with the unpredictable growth of any given IH, may lead to uncertainty in management (ie, whether to treat or observe). Although this CPG provides guidance regarding risk stratification and growth characteristics, there is no one-size-fits-all approach. If uncertainty exists, consultation with a hemangioma specialist (whether by an in-person visit or photographic triage) can be helpful.

A third challenge is the long-held tenet that IHs are benign and go away. Because of this myth, parents and caregivers are often reassured that the lesion will disappear, and this is accurate in the vast majority of cases. However, there is ample evidence that

false reassurance can be given even in high-risk cases; indeed, all hemangioma specialists have seen examples of lost opportunities to intervene and prevent poor outcomes because of lack of or delayed referral. The availability of highly effective treatments for IHs makes it critical that this myth is debunked and that practitioners become more comfortable with the concept of identifying high-risk IHs that require close observation or prompt intervention.

Last, some geographical locations lack access to prompt specialty care from hemangioma specialists. Lack of access can also result in delays in referrals or prompt appointments. Possible solutions could include establishing resources for the photographic triage of cases in which risk stratification is uncertain or in which triage to hasten referral can be augmented by this methodology.

### EVIDENCE GAPS AND PROPOSED FUTURE DIRECTIONS

The proportion of IHs in primary care settings that are truly high risk is not known. Even in a referral setting, the proportions needing active intervention vary depending on referral patterns.<sup>3,161</sup> This information would be useful to pediatricians and other primary care providers and should be the subject of future research.

Scoring systems for IH severity have been proposed, and one in particular, the Hemangioma Severity Score, has gained some favor as a triage tool.<sup>162–164</sup> However, more research is needed to ensure that it can accurately be interpreted by primary care physicians and to find scores that capture the vast majority of high-risk IHs requiring specialty care without overreferring.

Other important evidence gaps should be highlighted, including the following:

- How safe is topical timolol as a treatment during early infancy, and which patients being treated with the

drug need referral versus which can be observed without referral by the pediatrician?

- Is outpatient in-office cardiovascular monitoring for propranolol truly needed in healthy infants 5 weeks or older? Is blood pressure monitoring necessary, or is measuring heart rate sufficient?
- What is the role of the pediatrician in managing infants placed on  $\beta$ -blocker therapies (both topical and systemic), and are there specific time frames for specialty reevaluation?
- How accurate are primary care physicians in identifying high-risk IHs using parameters such as those outlined in this CPG?
- Are pediatric trainees receiving adequate training in risk stratification and management of IHs?

Some of these questions may be answered by research that is currently underway. Other studies will be needed to identify and remedy remaining gaps. Moreover, because there has been a tremendous accrual of information about IH management, there will need to be periodic updates as new information becomes available (and possibly sooner than the 5 years typical for CPGs). With such ongoing reassessment and revision, the subcommittee hopes this CPG will be viewed as an effective guide to IH triage and management and to minimize poor outcomes from higher-risk IHs. One barrier to a better understanding of IHs and to answering the questions posed here is the imprecision of current diagnostic codes. For example, the *International Classification of Diseases, 10th Revision* code for “hemangioma of the skin and subcutaneous tissues” is not specific to IHs and can include other entities (eg, congenital hemangioma and verrucous hemangioma) that are not IHs. In addition, current diagnostic codes do not contain sufficient detail to permit appreciation of higher-risk features, such as location or multifocality. Advocacy for the creation of a unique and exclusive *International*

*Classification of Diseases, 10th Revision* code (and appropriate modifiers) for IHS would be an appropriate step in addressing this issue.

Implementation tools for this guideline are available on the AAP Web site at <https://www.aap.org/en-us/professional-resources/quality-improvement/Pages/default.aspx> (this may leave or stay depending on the Digital Transformation Initiative). A useful resource for clinicians is the AAP Web page, “Diagnosis and Management of Infantile Hemangiomas” (<https://www.aap.org/en-us/advocacy-and-policy/aap-health-initiatives/Infantile-Hemangiomas/Pages/default.aspx>).

### LEAD AUTHORS

Daniel P. Krowchuk, MD, FAAP  
Ilona J. Frieden, MD, FAAP  
Anthony J. Mancini MD, FAAP  
David H. Darrow, MD, DDS, FAAP  
Francine Blei, MD, MBA, FAAP  
Arin K. Greene, MD, FAAP  
Aparna Annam, DO, FAAP  
Cynthia N. Baker, MD, FAAP  
Peter C. Frommelt, MD  
Amy Hodak, CPMSM  
Brian M. Pate, MD, FHM, FAAP  
Janice L. Pelletier, MD, FAAP  
Deborah Sandrock, MD, FAAP

Stuart T. Weinberg, MD, FAAP  
Mary Anne Whelan, MD, PhD, FAAP

### SUBCOMMITTEE ON THE MANAGEMENT OF INFANTILE HEMANGIOMAS (OVERSIGHT BY THE COUNCIL ON QUALITY IMPROVEMENT AND PATIENT SAFETY)

Daniel P. Krowchuk, MD, FAAP, Chairperson, General Pediatrics and Adolescent Medicine  
Ilona Frieden, MD, FAAP, Vice Chairperson, Pediatric Dermatology  
Aparna Annam, DO, FAAP, Pediatric Radiology  
Cynthia N. Baker, MD, FAAP, General Pediatrics  
Francine Blei, MD, MBA, FAAP, Pediatric Hematology-Oncology  
David H. Darrow, MD, DDS, FAAP, Otolaryngology Head and Neck Surgery  
Peter C. Frommelt, MD, Pediatric Cardiology  
Arin K. Greene, MD, FAAP, Plastic Surgery  
Amy Hodak, CPMSM, Family Representative  
Anthony J. Mancini, MD, FAAP, Pediatric Dermatology  
Brian M. Pate, MD, FHM, FAAP, Implementation Scientist  
Janice L. Pelletier, MD, FAAP, General Pediatrics  
Deborah Sandrock, MD, FAAP, General Pediatrics  
Stuart T. Weinberg, MD, FAAP, Partnership for Policy Implementation Representative  
Mary Anne Whelan, MD, PhD, FAAP, Epidemiologist and Methodologist

### STAFF

Kymika Okechukwu, MPA, Senior Manager, Evidence-Based Medicine Initiatives

### ABBREVIATIONS

AAP: American Academy of Pediatrics  
AHRQ: Agency for Healthcare Research and Quality  
CPG: clinical practice guideline  
ECG: electrocardiography  
FDA: Food and Drug Administration  
IH: infantile hemangioma  
IH-MAG: infantile hemangioma with minimal or arrested growth  
KAS: key action statement  
LUMBAR: lower body infantile hemangiomas and other cutaneous defects, urogenital anomalies and ulceration, myelopathy, bony deformities, anorectal malformations, and arterial anomalies and renal anomalies  
MRA: magnetic resonance angiography  
PDL: pulsed-dye laser  
PHACE: posterior fossa defects, hemangiomas, cerebrovascular arterial anomalies, cardiovascular anomalies (including coarctation of the aorta), and eye anomalies  
RCT: randomized controlled trial  
SOE: strength of evidence

*The guidance in this report does not indicate an exclusive course of treatment or serve as a standard of medical care. Variations, taking into account individual circumstances, may be appropriate.*

*All clinical practice guidelines from the American Academy of Pediatrics automatically expire 5 years after publication unless reaffirmed, revised, or retired at or before that time.*

**DOI:** <https://doi.org/10.1542/peds.2018-3475>

Address correspondence to Daniel P. Krowchuk, MD, FAAP. E-mail: [krowchuk@wakehealth.edu](mailto:krowchuk@wakehealth.edu)

PEDIATRICS (ISSN Numbers: Print, 0031-4005; Online, 1098-4275).

Copyright © 2019 by the American Academy of Pediatrics

**FINANCIAL DISCLOSURE:** Dr Frieden is a member of the Data Monitoring Safety Board for Pfizer and the Scientific Advisory Board for Venthera/Bridge Bio; Dr Mancini has indicated that he has advisory board relationships with Verrica, Valeant, and Pfizer; the other authors have indicated they have no financial relationships relevant to this article to disclose.

**FUNDING:** No external funding.

**POTENTIAL CONFLICT OF INTEREST:** The authors have indicated they have no potential conflicts of interest to disclose.

### REFERENCES

- Hoeger PH, Harper JI, Baselga E, et al. Treatment of infantile haemangiomas: recommendations of a European expert group. *Eur J Pediatr*. 2015;174(7):855–865
- Smithson SL, Rademaker M, Adams S, et al. Consensus statement for the treatment of infantile haemangiomas with propranolol. *Australas J Dermatol*. 2017;58(2):155–159
- Darrow DH, Greene AK, Mancini AJ, Nopper AJ; Section on Dermatology; Section on Otolaryngology–Head and Neck Surgery; Section on Plastic Surgery. Diagnosis and management of infantile hemangioma. *Pediatrics*. 2015;136(4). Available at: [www.pediatrics.org/cgi/content/full/136/4/e1060](http://www.pediatrics.org/cgi/content/full/136/4/e1060)
- Agency for Healthcare Research and Quality. Effective health care program.

Available at: [www.effectivehealthcare.ahrq.gov/reports/final.cfm](http://www.effectivehealthcare.ahrq.gov/reports/final.cfm). Accessed February 6, 2018

5. Haggstrom AN, Garzon MC, Baselga E, et al. Risk for PHACE syndrome in infants with large facial hemangiomas. *Pediatrics*. 2010;126(2). Available at: [www.pediatrics.org/cgi/content/full/126/2/e418](http://www.pediatrics.org/cgi/content/full/126/2/e418)
6. Orlow SJ, Isakoff MS, Blei F. Increased risk of symptomatic hemangiomas of the airway in association with cutaneous hemangiomas in a “beard” distribution. *J Pediatr*. 1997;131(4):643–646
7. Kulungowski AM, Alomari AI, Chawla A, Christison-Lagay ER, Fishman SJ. Lessons from a liver hemangioma registry: subtype classification. *J Pediatr Surg*. 2012;47(1):165–170
8. Rialon KL, Murillo R, Fevurly RD, et al. Risk factors for mortality in patients with multifocal and diffuse hepatic hemangiomas. *J Pediatr Surg*. 2015;50(5):837–841
9. Huang SA, Tu HM, Harney JW, et al. Severe hypothyroidism caused by type 3 iodothyronine deiodinase in infantile hemangiomas. *N Engl J Med*. 2000;343(3):185–189
10. Horii KA, Drolet BA, Frieden IJ, et al; Hemangioma Investigator Group. Prospective study of the frequency of hepatic hemangiomas in infants with multiple cutaneous infantile hemangiomas. *Pediatr Dermatol*. 2011;28(3):245–253
11. Rialon KL, Murillo R, Fevurly RD, et al. Impact of screening for hepatic hemangiomas in patients with multiple cutaneous infantile hemangiomas. *Pediatr Dermatol*. 2015;32(6):808–812
12. Jockin YM, Friedlander SF. Periocular infantile hemangioma. *Int Ophthalmol Clin*. 2010;50(4):15–25
13. Schwartz SR, Blei F, Ceisler E, Steele M, Furlan L, Kodosi S. Risk factors for amblyopia in children with capillary hemangiomas of the eyelids and orbit. *J AAPOS*. 2006;10(3):262–268
14. Chamlin SL, Haggstrom AN, Drolet BA, et al. Multicenter prospective study of ulcerated hemangiomas [published correction appears in *J Pediatr*. 2008;152(4):597]. *J Pediatr*. 2007;151(6):684–689, 689.e1
15. Connelly EA, Viera M, Price C, Waner M. Segmental hemangioma of infancy complicated by life-threatening arterial bleed. *Pediatr Dermatol*. 2009;26(4):469–472
16. Garzon MC, Epstein LG, Heyer GL, et al. PHACE syndrome: consensus-derived diagnosis and care recommendations. *J Pediatr*. 2016;178:24–33.e2
17. Iacobas I, Burrows PE, Frieden IJ, et al. LUMBAR: association between cutaneous infantile hemangiomas of the lower body and regional congenital anomalies. *J Pediatr*. 2010;157(5):795–801.e1–e7
18. Shah SD, Baselga E, McCuaig C, et al. Rebound growth of infantile hemangiomas after propranolol therapy. *Pediatrics*. 2016;137(4):e20151754
19. Bauland CG, Lüning TH, Smit JM, Zeebregts CJ, Spauwen PH. Untreated hemangiomas: growth pattern and residual lesions. *Plast Reconstr Surg*. 2011;127(4):1643–1648
20. Baselga E, Roe E, Coulie J, et al. Risk factors for degree and type of sequelae after involution of untreated hemangiomas of infancy. *JAMA Dermatol*. 2016;152(11):1239–1243
21. Tollefson MM, Frieden IJ. Early growth of infantile hemangiomas: what parents’ photographs tell us. *Pediatrics*. 2012;130(2). Available at: [www.pediatrics.org/cgi/content/full/130/2/e314](http://www.pediatrics.org/cgi/content/full/130/2/e314)
22. Chang LC, Haggstrom AN, Drolet BA, et al; Hemangioma Investigator Group. Growth characteristics of infantile hemangiomas: implications for management. *Pediatrics*. 2008;122(2):360–367
23. Suh KY, Frieden IJ. Infantile hemangiomas with minimal or arrested growth: a retrospective case series. *Arch Dermatol*. 2010;146(9):971–976
24. Luu M, Frieden IJ. Hemangioma: clinical course, complications and management. *Br J Dermatol*. 2013;169(1):20–30
25. Shikhani AH, Jones MM, Marsh BR, Holliday MJ. Infantile subglottic hemangiomas. An update. *Ann Otol Rhinol Laryngol*. 1986;95(4, pt 1):336–347
26. Bitar MA, Moukarbel RV, Zalzal GH. Management of congenital subglottic hemangioma: trends and success over the past 17 years. *Otolaryngol Head Neck Surg*. 2005;132(2):226–231
27. Uthuriague C, Boccara O, Catteau B, et al. Skin patterns associated with upper airway infantile haemangiomas: a retrospective multicentre study. *Acta Derm Venereol*. 2016;96(7):963–966
28. Sherrington CA, Sim DK, Freezer NJ, Robertson CF. Subglottic haemangioma. *Arch Dis Child*. 1997;76(5):458–459
29. Sie KC, McGill T, Healy GB. Subglottic hemangioma: ten years’ experience with the carbon dioxide laser. *Ann Otol Rhinol Laryngol*. 1994;103(3):167–172
30. Horii KA, Drolet BA, Baselga E, et al; Hemangioma Investigator Group. Risk of hepatic hemangiomas in infants with large hemangiomas. *Arch Dermatol*. 2010;146(2):201–203
31. Drolet BA, Pope E, Juern AM, et al. Gastrointestinal bleeding in infantile hemangioma: a complication of segmental, rather than multifocal, infantile hemangiomas. *J Pediatr*. 2012;160(6):1021–1026.e3
32. Viswanathan V, Smith ER, Mulliken JB, et al. Infantile hemangiomas involving the neuraxis: clinical and imaging findings. *AJNR Am J Neuroradiol*. 2009;30(5):1005–1013
33. von Noorden GK. Application of basic research data to clinical amblyopia. *Ophthalmology*. 1978;85(5):496–504
34. Dubois J, Milot J, Jaeger BI, McCuaig C, Rousseau E, Powell J. Orbit and eyelid hemangiomas: is there a relationship between location and ocular problems? *J Am Acad Dermatol*. 2006;55(4):614–619
35. Frank RC, Cowan BJ, Harrop AR, Astle WF, McPhalen DF. Visual development in infants: visual complications of periocular haemangiomas. *J Plast Reconstr Aesthet Surg*. 2010;63(1):1–8
36. Yan AC. Pain management for ulcerated hemangiomas. *Pediatr Dermatol*. 2008;25(6):586–589
37. Thomas MW, Burkhart CN, Vaghani SP, Morrell DS, Wagner AM. Failure to thrive in infants with complicated facial hemangiomas. *Pediatr Dermatol*. 2012;29(1):49–52

38. Shin HT, Orlow SJ, Chang MW. Ulcerated haemangioma of infancy: a retrospective review of 47 patients. *Br J Dermatol*. 2007;156(5):1050–1052
39. Frieden IJ, Reese V, Cohen D. PHACE syndrome. The association of posterior fossa brain malformations, hemangiomas, arterial anomalies, coarctation of the aorta and cardiac defects, and eye abnormalities. *Arch Dermatol*. 1996;132(3):307–311
40. Püttgen K, Lucky A, Adams D, et al; Hemangioma Investigator Group. Topical timolol maleate treatment of infantile hemangiomas. *Pediatrics*. 2016;138(3):e20160355
41. Jacobs AH. Strawberry hemangiomas; the natural history of the untreated lesion. *Calif Med*. 1957;86(1):8–10
42. Tanner JL, Dechert MP, Frieden IJ. Growing up with a facial hemangioma: parent and child coping and adaptation. *Pediatrics*. 1998;101(3, pt 1):446–452
43. Fay A, Nguyen J, Waner M. Conceptual approach to the management of infantile hemangiomas. *J Pediatr*. 2010;157(6):881–888.e1–e5
44. O TM, Scheuermann-Poley C, Tan M, Waner M. Distribution, clinical characteristics, and surgical treatment of lip infantile hemangiomas. *JAMA Facial Plast Surg*. 2013;15(4):292–304
45. Ma EH, Robertson SJ, Chow CW, Bekhor PS. Infantile hemangioma with minimal or arrested growth: further observations on clinical and histopathologic findings of this unique but underrecognized entity. *Pediatr Dermatol*. 2017;34(1):64–71
46. Chinnadurai S, Snyder K, Sathe N, et al. *Diagnosis and Management of Infantile Hemangioma*. Rockville, MD: Agency for Healthcare Research and Quality; 2016
47. Menapace D, Mitkov M, Towbin R, Hogeling M. The changing face of complicated infantile hemangioma treatment. *Pediatr Radiol*. 2016;46(11):1494–1506
48. Bessis D, Bigorre M, Labrèze C. Reticular infantile hemangiomas with minimal or arrested growth associated with lipomatosis. *J Am Acad Dermatol*. 2015;72(5):828–833
49. Dickie B, Dasgupta R, Nair R, et al. Spectrum of hepatic hemangiomas: management and outcome. *J Pediatr Surg*. 2009;44(1):125–133
50. Rotter A, Samorano LP, de Oliveira Labinas GH, et al. Ultrasonography as an objective tool for assessment of infantile hemangioma treatment with propranolol. *Int J Dermatol*. 2017;56(2):190–194
51. Mamlouk MD, Hess CP. Arterial spin-labeled perfusion for vascular anomalies in the pediatric head and neck. *Clin Imaging*. 2016;40(5):1040–1046
52. Aggarwal N, Tekes A, Bosemani T. Infantile hepatic hemangioma: role of dynamic contrast-enhanced magnetic resonance angiography. *J Pediatr*. 2015;167(4):940–940.e1
53. US Food and Drug Administration. FDA drug safety communications: FDA review results in new warnings about using general anesthetics and sedation drugs in young children and pregnant women. 2016. Available at: [www.fda.gov/downloads/Drugs/DrugSafety/UCM533197.pdf](http://www.fda.gov/downloads/Drugs/DrugSafety/UCM533197.pdf). Accessed September 10, 2018
54. American Society of Anesthesiologists. ASA response to the FDA med watch warning - December 16, 2016. 2016. Available at: <https://www.asahq.org/advocacy-and-asapac/fda-and-washington-alerts/washington-alerts/2016/12/asa-response-to-the-fda-med-watch>. Accessed September 10, 2018
55. Practice advisory on anesthetic care for magnetic resonance imaging: an updated report by the American Society of Anesthesiologists Task Force on Anesthetic Care for Magnetic Resonance Imaging. *Anesthesiology*. 2015;122(3):495–520
56. Drolet BA, Chamlin SL, Garzon MC, et al. Prospective study of spinal anomalies in children with infantile hemangiomas of the lumbosacral skin. *J Pediatr*. 2010;157(5):789–794
57. Schumacher WE, Drolet BA, Maheshwari M, et al. Spinal dysraphism associated with the cutaneous lumbosacral infantile hemangioma: a neuroradiological review. *Pediatr Radiol*. 2012;42(3):315–320
58. Yu J, Maheshwari M, Foy AB, Galkins CM, Drolet BA. Neonatal lumbosacral ulceration masking lumbosacral and intraspinal hemangiomas associated with occult spinal dysraphism. *J Pediatr*. 2016;175:211–215
59. Léauté-Labrèze C, Dumas de la Roque E, Hubiche T, Boralevi F, Thambo JB, Taïeb A. Propranolol for severe hemangiomas of infancy. *N Engl J Med*. 2008;358(24):2649–2651
60. Léaute-Labrèze C, Boccara O, Degrugillier-Chopinot C, et al. Safety of oral propranolol for the treatment of infantile hemangioma: a systematic review. *Pediatrics*. 2016;138(4):e20160353
61. Drolet BA, Frommelt PC, Chamlin SL, et al. Initiation and use of propranolol for infantile hemangioma: report of a consensus conference. *Pediatrics*. 2013;131(1):128–140
62. Itinteang T, Withers AH, Davis PF, Tan ST. Biology of infantile hemangioma. *Front Surg*. 2014;1:38
63. Dai Y, Hou F, Buckmiller L, et al. Decreased eNOS protein expression in involuting and propranolol-treated hemangiomas. *Arch Otolaryngol Head Neck Surg*. 2012;138(2):177–182
64. Greenberger S, Bischoff J. Infantile hemangioma-mechanism(s) of drug action on a vascular tumor. *Cold Spring Harb Perspect Med*. 2011;1(1):a006460
65. Storch CH, Hoeger PH. Propranolol for infantile haemangiomas: insights into the molecular mechanisms of action. *Br J Dermatol*. 2010;163(2):269–274
66. Sans V, de la Roque ED, Berge J, et al. Propranolol for severe infantile hemangiomas: follow-up report. *Pediatrics*. 2009;124(3). Available at: [www.pediatrics.org/cgi/content/full/124/3/e423](http://www.pediatrics.org/cgi/content/full/124/3/e423)
67. Pan WK, Li P, Guo ZT, Huang Q, Gao Y. Propranolol induces regression of hemangioma cells via the down-regulation of the PI3K/Akt/eNOS/VEGF pathway. *Pediatr Blood Cancer*. 2015;62(8):1414–1420
68. Sharifpanah F, Saliu F, Bekhite MM, Wartenberg M, Sauer H.  $\beta$ -adrenergic receptor antagonists inhibit vasculogenesis of embryonic stem cells by downregulation of nitric oxide generation and interference



- with VEGF signalling. *Cell Tissue Res*. 2014;358(2):443–452
69. Ji Y, Chen S, Xu C, Li L, Xiang B. The use of propranolol in the treatment of infantile haemangiomas: an update on potential mechanisms of action. *Br J Dermatol*. 2015;172(1):24–32
  70. Greene AK, Couto RA. Oral prednisolone for infantile hemangioma: efficacy and safety using a standardized treatment protocol. *Plast Reconstr Surg*. 2011;128(3):743–752
  71. Tiwari P, Pandey V, Gangopadhyay AN, Sharma SP, Gupta DK. Role of propranolol in ulcerated haemangioma of head and neck: a prospective comparative study. *Oral Maxillofac Surg*. 2016;20(1):73–77
  72. Zaher H, Rasheed H, El-Komy MM, et al. Propranolol versus captopril in the treatment of infantile hemangioma (IH): a randomized controlled trial. *J Am Acad Dermatol*. 2016;74(3):499–505
  73. Wu S, Wang B, Chen L, et al. Clinical efficacy of propranolol in the treatment of hemangioma and changes in serum VEGF, bFGF and MMP-9. *Exp Ther Med*. 2015;10(3):1079–1083
  74. Aly MM, Hamza AF, Abdel Kader HM, Saafan HA, Ghazy MS, Ragab IA. Therapeutic superiority of combined propranolol with short steroids course over propranolol monotherapy in infantile hemangioma. *Eur J Pediatr*. 2015;174(11):1503–1509
  75. Ji Y, Wang Q, Chen S, et al. Oral atenolol therapy for proliferating infantile hemangioma: a prospective study. *Medicine (Baltimore)*. 2016;95(24):e3908
  76. Léauté-Labrèze C, Hoeger P, Mazereeuw-Hautier J, et al. A randomized, controlled trial of oral propranolol in infantile hemangioma. *N Engl J Med*. 2015;372(8):735–746
  77. Siegel DH, Tefft KA, Kelly T, et al. Stroke in children with posterior fossa brain malformations, hemangiomas, arterial anomalies, coarctation of the aorta and cardiac defects, and eye abnormalities (PHACE) syndrome: a systematic review of the literature. *Stroke*. 2012;43(6):1672–1674
  78. Breur JM, de Graaf M, Breugem CC, Pasmans SG. Hypoglycemia as a result of propranolol during treatment of infantile hemangioma: a case report. *Pediatr Dermatol*. 2011;28(2):169–171
  79. Holland KE, Frieden IJ, Frommelt PC, Mancini AJ, Wyatt D, Drolet BA. Hypoglycemia in children taking propranolol for the treatment of infantile hemangioma. *Arch Dermatol*. 2010;146(7):775–778
  80. Prey S, Voisard JJ, Delarue A, et al. Safety of propranolol therapy for severe infantile hemangioma. *JAMA*. 2016;315(4):413–415
  81. Techasatian L, Komwilaisak P, Panombualert S, Uppala R, Jetsrisuparb C. Propranolol was effective in treating cutaneous infantile haemangiomas in Thai children. *Acta Paediatr*. 2016;105(6):e257–e262
  82. Stringari G, Barbato G, Zanzucchi M, et al. Propranolol treatment for infantile hemangioma: a case series of sixty-two patients. *Pediatr Med Chir*. 2016;38(2):113
  83. Sreekantam S, Preece MA, Vijay S, Raiman J, Santra S. How to use a controlled fast to investigate hypoglycaemia. *Arch Dis Child Educ Pract Ed*. 2017;102(1):28–36
  84. Cushing SL, Boucek RJ, Manning SC, Sidbury R, Perkins JA. Initial experience with a multidisciplinary strategy for initiation of propranolol therapy for infantile hemangiomas. *Otolaryngol Head Neck Surg*. 2011;144(1):78–84
  85. Ng M, Knuth C, Weisbrod C, Murthy A. Propranolol therapy for problematic infantile hemangioma. *Ann Plast Surg*. 2016;76(3):306–310
  86. Chang L, Ye X, Qiu Y, et al. Is propranolol safe and effective for outpatient use for infantile hemangioma? A prospective study of 679 cases from one center in China. *Ann Plast Surg*. 2016;76(5):559–563
  87. Liu LS, Sokoloff D, Antaya RJ. Twenty-four-hour hospitalization for patients initiating systemic propranolol therapy for infantile hemangiomas—is it indicated? *Pediatr Dermatol*. 2013;30(5):554–560
  88. El Ezzi O, Hohlfeld J, de Buys Roessingh A. Propranolol in infantile haemangioma: simplifying pretreatment monitoring. *Swiss Med Wkly*. 2014;144:w13943
  89. Tang LY, Hing JW, Tang JY, et al. Predicting complications with pretreatment testing in infantile haemangioma treated with oral propranolol. *Br J Ophthalmol*. 2016;100(7):902–906
  90. Ge J, Zheng J, Zhang L, Yuan W, Zhao H. Oral propranolol combined with topical timolol for compound infantile hemangiomas: a retrospective study. *Sci Rep*. 2016;6:19765
  91. Raphael MF, Breugem CC, Vlasveld FA, et al. Is cardiovascular evaluation necessary prior to and during beta-blocker therapy for infantile hemangiomas?: a cohort study. *J Am Acad Dermatol*. 2015;72(3):465–472
  92. de Graaf M, Breur JMPJ, Raphaël MF, Vos M, Breugem CC, Pasmans SGMA. Adverse effects of propranolol when used in the treatment of hemangiomas: a case series of 28 infants. *J Am Acad Dermatol*. 2011;65(2):320–327
  93. Xu DP, Cao RY, Xue L, Sun NN, Tong S, Wang XK. Treatment of severe infantile hemangiomas with propranolol: an evaluation of the efficacy and effects of cardiovascular parameters in 25 consecutive patients. *J Oral Maxillofac Surg*. 2015;73(3):430–436
  94. Street JA, Hemsworth BA, Roach AG, Day MD. Tissue levels of several radiolabelled beta-adrenoceptor antagonists after intravenous administration in rats. *Arch Int Pharmacodyn Ther*. 1979;237(2):180–190
  95. Feenstra MG. Functional neuroteratology of drugs acting on adrenergic receptors. *Neurotoxicology*. 1992;13(1):55–63
  96. Pitzer M, Schmidt MH, Esser G, Laucht M. Child development after maternal tocolysis with beta-sympathomimetic drugs. *Child Psychiatry Hum Dev*. 2001;31(3):165–182
  97. Langley A, Pope E. Propranolol and central nervous system function: potential implications for paediatric patients with infantile haemangiomas. *Br J Dermatol*. 2015;172(1):13–23

98. Bryan BA. Reconsidering the use of propranolol in the treatment of cosmetic infantile hemangiomas. *Angiology: Open Access*. 2013;1:e101
99. Phillips RJ, Penington AJ, Bekhor PS, Crock CM. Use of propranolol for treatment of infantile haemangiomas in an outpatient setting. *J Paediatr Child Health*. 2012;48(10):902–906
100. Gonski K, Wargon O. Retrospective follow up of gross motor development in children using propranolol for treatment of infantile haemangioma at Sydney Children's Hospital. *Australas J Dermatol*. 2014;55(3):209–211
101. Moyakine AV, Hermans DJ, Fuijkschot J, van der Vleuten CJ. Propranolol treatment of infantile hemangiomas does not negatively affect psychomotor development. *J Am Acad Dermatol*. 2015;73(2):341–342
102. Moyakine AV, Kerstjens JM, Spillekom-van Koullil S, van der Vleuten CJ. Propranolol treatment of infantile hemangioma (IH) is not associated with developmental risk or growth impairment at age 4 years. *J Am Acad Dermatol*. 2016;75(1):59–63.e1
103. Chinnadurai S, Fannesbeck C, Snyder KM, et al. Pharmacologic interventions for infantile hemangioma: a meta-analysis. *Pediatrics*. 2016;137(2):e20153896
104. Frieden IJ, Eichenfield LF, Esterly NB, Geronemus R, Mallory SB; American Academy of Dermatology Guidelines Outcomes Committee. Guidelines of care for hemangiomas of infancy. *J Am Acad Dermatol*. 1997;37(4):631–637
105. Sadan N, Wolach B. Treatment of hemangiomas of infants with high doses of prednisone. *J Pediatr*. 1996;128(1):141–146
106. Bennett ML, Fleischer AB Jr, Chamlin SL, Frieden IJ. Oral corticosteroid use is effective for cutaneous hemangiomas: an evidence-based evaluation. *Arch Dermatol*. 2001;137(9):1208–1213
107. Nieuwenhuis K, de Laat PC, Janmohamed SR, Madern GC, Oranje AP. Infantile hemangioma: treatment with short course systemic corticosteroid therapy as an alternative for propranolol. *Pediatr Dermatol*. 2013;30(1):64–70
108. Sloan GM, Reinisch JF, Nichter LS, Saber WL, Lew K, Morwood DT. Intralesional corticosteroid therapy for infantile hemangiomas. *Plast Reconstr Surg*. 1989;83(3):459–467
109. Chowdri NA, Darzi MA, Fazili Z, Iqbal S. Intralesional corticosteroid therapy for childhood cutaneous hemangiomas. *Ann Plast Surg*. 1994;33(1):46–51
110. Chen MT, Yeong EK, Horng SY. Intralesional corticosteroid therapy in proliferating head and neck hemangiomas: a review of 155 cases. *J Pediatr Surg*. 2000;35(3):420–423
111. Buckmiller LM, Francis CL, Glade RS. Intralesional steroid injection for proliferative parotid hemangiomas. *Int J Pediatr Otorhinolaryngol*. 2008;72(1):81–87
112. Prasetyono TO, Djoenaedi I. Efficacy of intralesional steroid injection in head and neck hemangioma: a systematic review. *Ann Plast Surg*. 2011;66(1):98–106
113. Zarem HA, Edgerton MT. Induced resolution of cavernous hemangiomas following prednisolone therapy. *Plast Reconstr Surg*. 1967;39(1):76–83
114. Kushner BJ. The treatment of periorbital infantile hemangioma with intralesional corticosteroid. *Plast Reconstr Surg*. 1985;76(4):517–526
115. Herlihy EP, Kelly JP, Sidbury R, Perkins JA, Weiss AH. Visual acuity and astigmatism in periocular infantile hemangiomas treated with oral beta-blocker versus intralesional corticosteroid injection. *J AAPOS*. 2016;20(1):30–33
116. Goyal R, Watts P, Lane CM, Beck L, Gregory JW. Adrenal suppression and failure to thrive after steroid injections for periocular hemangioma. *Ophthalmology*. 2004;111(2):389–395
117. Weiss AH. Adrenal suppression after corticosteroid injection of periocular hemangiomas. *Am J Ophthalmol*. 1989;107(5):518–522
118. Shorr N, Seiff SR. Central retinal artery occlusion associated with periocular corticosteroid injection for juvenile hemangioma. *Ophthalmic Surg*. 1986;17(4):229–231
119. Ruttum MS, Abrams GW, Harris GJ, Ellis MK. Bilateral retinal embolization associated with intralesional corticosteroid injection for capillary hemangioma of infancy. *J Pediatr Ophthalmol Strabismus*. 1993;30(1):4–7
120. Egbert JE, Schwartz GS, Walsh AW. Diagnosis and treatment of an ophthalmic artery occlusion during an intralesional injection of corticosteroid into an eyelid capillary hemangioma. *Am J Ophthalmol*. 1996;121(6):638–642
121. Egbert JE, Paul S, Engel WK, Summers CG. High injection pressure during intralesional injection of corticosteroids into capillary hemangiomas. *Arch Ophthalmol*. 2001;119(5):677–683
122. Chan H, McKay C, Adams S, Wargon O. RCT of timolol maleate gel for superficial infantile hemangiomas in 5- to 24-week-olds. *Pediatrics*. 2013;131(6). Available at: [www.pediatrics.org/cgi/content/full/131/6/e1739](http://www.pediatrics.org/cgi/content/full/131/6/e1739)
123. Pope E, Chakkittakandiyil A. Topical timolol gel for infantile hemangiomas: a pilot study. *Arch Dermatol*. 2010;146(5):564–565
124. Chakkittakandiyil A, Phillips R, Frieden IJ, et al. Timolol maleate 0.5% or 0.1% gel-forming solution for infantile hemangiomas: a retrospective, multicenter, cohort study. *Pediatr Dermatol*. 2012;29(1):28–31
125. Chambers CB, Katowitz WR, Katowitz JA, Binenbaum G. A controlled study of topical 0.25% timolol maleate gel for the treatment of cutaneous infantile capillary hemangiomas. *Ophthalm Plast Reconstr Surg*. 2012;28(2):103–106
126. Frommelt P, Juern A, Siegel D, et al. Adverse events in young and preterm infants receiving topical timolol for infantile hemangioma. *Pediatr Dermatol*. 2016;33(4):405–414
127. McMahon P, Oza V, Frieden IJ. Topical timolol for infantile hemangiomas: putting a note of caution in “cautiously optimistic”. *Pediatr Dermatol*. 2012;29(1):127–130
128. Coppens G, Stalmans I, Zeyen T, Casteels I. The safety and efficacy of glaucoma medication in the pediatric

- population. *J Pediatr Ophthalmol Strabismus*. 2009;46(1):12–18
129. Guo S, Ni N. Topical treatment for capillary hemangioma of the eyelid using beta-blocker solution. *Arch Ophthalmol*. 2010;128(2):255–256
  130. Ni N, Langer P, Wagner R, Guo S. Topical timolol for periocular hemangioma: report of further study. *Arch Ophthalmol*. 2011;129(3):377–379
  131. Moehrle M, Léauté-Labrèze C, Schmidt V, Röcken M, Poets CF, Goelz R. Topical timolol for small hemangiomas of infancy. *Pediatr Dermatol*. 2013;30(2):245–249
  132. Yu L, Li S, Su B, et al. Treatment of superficial infantile hemangiomas with timolol: evaluation of short-term efficacy and safety in infants. *Exp Ther Med*. 2013;6(2):388–390
  133. Danarti R, Ariwibowo L, Radiono S, Budiyanto A. Topical timolol maleate 0.5% for infantile hemangioma: its effectiveness compared to ultrapotent topical corticosteroids - a single-center experience of 278 cases. *Dermatology*. 2016;232(5):566–571
  134. Oranje AP, Janmohamed SR, Madern GC, de Laat PC. Treatment of small superficial haemangioma with timolol 0.5% ophthalmic solution: a series of 20 cases. *Dermatology*. 2011;223(4):330–334
  135. Gomulka J, Siegel DH, Drolet BA. Dramatic shift in the infantile hemangioma treatment paradigm at a single institution. *Pediatr Dermatol*. 2013;30(6):751–752
  136. Weibel L, Barysch MJ, Scheer HS, et al. Topical timolol for infantile hemangiomas: evidence for efficacy and degree of systemic absorption. *Pediatr Dermatol*. 2016;33(2):184–190
  137. Olson RJ, Bromberg BB, Zimmerman TJ. Apneic spells associated with timolol therapy in a neonate. *Am J Ophthalmol*. 1979;88(1):120–122
  138. Burnstine RA, Felton JL, Ginther WH. Cardiorespiratory reaction to timolol maleate in a pediatric patient: a case report. *Ann Ophthalmol*. 1982;14(10):905–906
  139. Kiryazov K, Stefova M, Iotova V. Can ophthalmic drops cause central nervous system depression and cardiogenic shock in infants? *Pediatr Emerg Care*. 2013;29(11):1207–1209
  140. Semkova K, Kazandjjeva J. Topical timolol maleate for treatment of infantile haemangiomas: preliminary results of a prospective study. *Clin Exp Dermatol*. 2013;38(2):143–146
  141. Boos MD, Castelo-Soccio L. Experience with topical timolol maleate for the treatment of ulcerated infantile hemangiomas (IH). *J Am Acad Dermatol*. 2016;74(3):567–570
  142. Greene AK. Management of hemangiomas and other vascular tumors. *Clin Plast Surg*. 2011;38(1):45–63
  143. Couto RA, Maclellan RA, Zurakowski D, Greene AK. Infantile hemangioma: clinical assessment of the involuting phase and implications for management. *Plast Reconstr Surg*. 2012;130(3):619–624
  144. Batta K, Goodyear HM, Moss C, Williams HC, Hiller L, Waters R. Randomised controlled study of early pulsed dye laser treatment of uncomplicated childhood haemangiomas: results of a 1-year analysis. *Lancet*. 2002;360(9332):521–527
  145. Mulliken JB, Fishman SJ, Burrows PE. Vascular anomalies. *Curr Probl Surg*. 2000;37(8):517–584
  146. Charlesworth R. The toddler: affective development. In: *Understanding Child Development*. 6th ed. Delmar Learning; 1994:304
  147. Santrock JW. The self and identity. In: *Child Development*. 7th ed. McGraw-Hill; 1996:378–385
  148. Neisser U. Memory development: new questions and old. *Dev Rev*. 2004;24(1):154–158
  149. Bowers RE, Graham EA, Tomlinson KM. The natural history of the strawberry nevus. *Arch Dermatol*. 1960;82(5):667–680
  150. Laubach HJ, Anderson RR, Luger T, Manstein D. Fractional photothermolysis for involuted infantile hemangioma. *Arch Dermatol*. 2009;145(7):748–750
  151. Witman PM, Wagner AM, Scherer K, Waner M, Frieden IJ. Complications following pulsed dye laser treatment of superficial hemangiomas. *Lasers Surg Med*. 2006;38(2):116–123
  152. Scheepers JH, Quaba AA. Does the pulsed tunable dye laser have a role in the management of infantile hemangiomas? Observations based on 3 years' experience. *Plast Reconstr Surg*. 1995;95(2):305–312
  153. Kessels JP, Hamers ET, Ostertag JU. Superficial hemangioma: pulsed dye laser versus wait-and-see. *Dermatol Surg*. 2013;39(3, pt 1):414–421
  154. Liu LS, Sowa A, Antaya RJ. Educating caregivers about the natural history of infantile hemangiomas. *Acta Paediatr*. 2015;104(1):9–11
  155. Zweegers J, van der Vleuten CJ. The psychosocial impact of an infantile haemangioma on children and their parents. *Arch Dis Child*. 2012;97(10):922–926
  156. Minzer-Conzetti K, Garzon MC, Haggstrom AN, et al. Information about infantile hemangiomas on the Internet: how accurate is it? *J Am Acad Dermatol*. 2007;57(6):998–1004
  157. Takahashi K, Mulliken JB, Kozakewich HP, Rogers RA, Folkman J, Ezekowitz RA. Cellular markers that distinguish the phases of hemangioma during infancy and childhood. *J Clin Invest*. 1994;93(6):2357–2364
  158. Agency for Healthcare Research and Quality. Treating infantile hemangiomas in children. Available at: <https://effectivehealthcare.ahrq.gov/topics/infantile-hemangioma/consumer>. Accessed November 27, 2018
  159. Bernabeu-Wittel J, Pereyra J, Corb R, Ruiz-Canela J, Tarilonte A M, Conejo-Mir J. Teledermatology for infantile hemangiomas. Comment on: Chang LC, Haggstrom AN, Drolet BA, et al for the Hemangioma Investigator Group. Growth characteristics of infantile hemangiomas: implications for management. *Pediatrics*. 2008;122:360–367. Available at: <http://pediatrics.aappublications.org/content/122/2/360.comments>
  160. Martin K, Blei F, Chamlin SL, et al. Propranolol treatment of infantile hemangiomas: anticipatory guidance for parents and caretakers [published correction appears in *Pediatr*

- Dermatol.* 2013;30(2):280]. *Pediatr Dermatol.* 2013;30(1):155–159
161. Munden A, Butschek R, Tom WL, et al. Prospective study of infantile haemangiomas: incidence, clinical characteristics and association with placental anomalies. *Br J Dermatol.* 2014;170(4):907–913
162. Moyakine AV, Herwegen B, van der Vleuten CJM. Use of the Hemangioma Severity Scale to facilitate treatment decisions for infantile hemangiomas. *J Am Acad Dermatol.* 2017;77(5):868–873
163. Mull JL, Chamlin SL, Lai JS, et al. Utility of the Hemangioma Severity Scale as a triage tool and predictor of need for treatment. *Pediatr Dermatol.* 2017;34(1):78–83
164. Haggstrom AN, Beaumont JL, Lai JS, et al. Measuring the severity of infantile hemangiomas: instrument development and reliability. *Arch Dermatol.* 2012;148(2):197–202