

# Evidence-Based Guidelines for Management of Diabetic Macular Edema

Sophie J. Bakri, MD<sup>1</sup>, Jeremy D. Wolfe, MD<sup>2</sup>, Carl D. Regillo, MD<sup>3</sup>, Harry W. Flynn Jr, MD<sup>4</sup>, and Charles C. Wykoff, MD, PhD<sup>5</sup>

## Abstract

**Purpose:** The purpose of this article is to provide a data-driven set of best practices to consider in the management of diabetic macular edema (DME). **Methods:** The current discussion and recommendations represent the authors' interpretations of data from selected references based on perceived relevance and study design. **Results:** DME is a common cause of visual impairment globally. The underlying progressive retinal microvascular damage is associated with upregulation of VEGF and a multitude of other inflammatory pathways. Three clinically relevant subcategories of DME can be identified: central-involved DME (CIDME) with preserved visual acuity, CIDME with associated visual loss, and non-CIDME. Management approaches may include observation, laser photocoagulation, intravitreal pharmacotherapy with anti-VEGF agents or corticosteroids, or a combination of these, and may vary depending on the specific type of DME and associated severity of diabetic retinopathy. Additional factors to consider in the management of patients with DME include the appropriate use of imaging and recognition of the chronic nature of the underlying disease process in many eyes. **Conclusions:** DME management is complex. Intravitreal pharmacotherapies are the current cornerstone of treatment for CIDME and appear poised to remain so for the foreseeable future.

## Keywords

corticosteroids, diabetic macular edema, diabetic retinopathy, macular laser, optical coherence tomography, optical coherence tomography angiography, vascular endothelial growth factor, widefield fluorescein angiography

## Introduction

Diabetes mellitus (DM) is a growing global challenge. In 2016 the World Health Organization estimated that approximately 1 in 12 adults were affected.<sup>1</sup> In the United States, the prevalence is estimated at 1 in 8.<sup>2</sup> Progressive microvascular damage to the retina, in the form of diabetic retinopathy (DR), is one of the most common end-organ manifestations of DM.<sup>3</sup> Subsequent local ischemia can lead to exudation of fluid, protein, and lipid following breakdown of the blood-retinal barrier and upregulation of a host of cytokines including VEGF.<sup>4</sup> Resultant diabetic macular edema (DME) and proliferative diabetic retinopathy (PDR) are common causes of blindness in many countries, often affecting working-age populations,<sup>3</sup> the key economic drivers of local societies.

For decades, laser-based modalities have been the cornerstones of management for DME and PDR.<sup>5</sup> However, pharmacologic management of DME is now first-line therapy for many clinical situations. Six pharmaceutical agents encompassing 2 mechanistic classes are used regularly for the treatment of DME. Engineered proteins including the FDA-approved ranibizumab (Lucentis; Genentech)<sup>6</sup> and aflibercept (Eylea; Regeneron Pharmaceuticals, Inc),<sup>7</sup> as well as the non-FDA-approved

bevacizumab (Avastin; Genentech)<sup>8</sup> block the activity of VEGF. Alternatively, the FDA-approved dexamethasone (Ozurdex; Allergan)<sup>9</sup> and fluocinolone acetonide (Iluvien; Alimera Sciences)<sup>10</sup> implants, as well as non-FDA-approved triamcinolone acetonide,<sup>11</sup> are corticosteroid agents. The current manuscript aims to provide a data-driven set of best practices to consider in the management of DME.

<sup>1</sup> Department of Ophthalmology, Mayo Clinic, Rochester, MN, USA

<sup>2</sup> Associated Retinal Consultants, Oakland University William Beaumont School of Medicine, Royal Oak, MI, USA

<sup>3</sup> Retina Service, Wills Eye Hospital, Philadelphia, PA, USA

<sup>4</sup> Department of Ophthalmology, Bascom Palmer Eye Institute, University of Miami School of Medicine, Miami, FL, USA

<sup>5</sup> Retina Consultants of Houston, Blanton Eye Institute, Houston Methodist Hospital, Greater Houston Retina Research Foundation, Weill Cornell Medical College, Houston, TX, USA

## Corresponding Author:

Charles C. Wykoff, MD, PhD, Retina Consultants of Houston, Blanton Eye Institute, Houston Methodist Hospital, Greater Houston Retina Research Foundation, Weill Cornell Medical College, 6560 Fannin St, Suite 750, Houston, TX 77030, USA.

Email: ccwmd@houstonretina.com

## Management Consideration for 3 Clinically Relevant DME Subcategories

Historically, a threshold for treating DME was set by the Early Treatment Diabetic Retinopathy Study (ETDRS) as clinically significant macular edema (CSME).<sup>12</sup> More clinically relevant today, however, is classification of DME as either central-involved DME (CIDME) or non-CIDME.<sup>3</sup> Central involvement is most accurately determined by optical coherence tomography (OCT) demonstrating foveal involvement of intraretinal or subretinal fluid with concurrent thickening affecting the 1 mm diameter central subfield thickness (CST) (Figure 1).

In cases of non-CIDME, the results of the ETDRS trial remain relevant to current practice and appropriately applied laser photocoagulation to the macula remains a validated option for treatment. Within the ETDRS, macular laser (focal and grid application) significantly reduced the risk of moderate visual loss by approximately 50%, a protective effect that was independent of baseline visual acuity (VA). Critically, while mean baseline VA in DME pharmaceutical trials has ranged from 20/50 to 20/80, approximately 85% of eyes enrolled in the ETDRS trial were 20/40 or better and approximately 63% were 20/25 or better; furthermore, just 7% of ETDRS eyes were worse than 20/63.<sup>12</sup> Despite its proven value, however, macular laser treatment has limitations and possible untoward effects. For example, focal macular laser for DME has shown limited effectiveness at improving mean VA<sup>6,7,11</sup> in the management of CIDME.

In cases of CIDME, there are 2 key subcategories: those with preserved VA and those with associated VA loss. Limited data exist to guide treatment of CIDME with preserved VA, defined as VA better than 20/32. Such eyes were not eligible for any of the phase 3 trials leading to FDA approval of the current pharmaceutical agents<sup>6,7,9,13</sup> or the Diabetic Retinopathy Clinical Research (DRCR) Network Protocol I<sup>11</sup> or Protocol T<sup>8</sup> trials. Data from the fully enrolled DRCR Network phase 3 Protocol V, which randomized treatment-naïve eyes with 20/25 or better VA and CIDME to either prompt anti-VEGF dosing, prompt macular laser, or observation, may serve to guide management of these eyes and is anticipated to release data in 2019.<sup>14</sup>

Current options for management include close clinical observation vs intravitreal pharmaceutical management, vs focal macular laser vs a combination of these options. Nevertheless, supporting earlier pharmaceutical intervention, better baseline VA at the time of initiation of intravitreal pharmaceutical therapy for DME is associated with better outcomes,<sup>15</sup> a correlation that has demonstrated remarkable consistency across many exudative retinal diseases.<sup>16-18</sup>

In eyes with CIDME and VA loss, intravitreal pharmaceutical delivery is generally first-line therapy. Numerous well-designed, randomized, phase 3 clinical trials have demonstrated significant benefit compared to observation or macular laser,<sup>6,7,9,13</sup> and anti-VEGF therapies are the current mainstay of therapy. A single phase 3 trial, DRCR Network Protocol T, compared available anti-VEGF agents through 2 years of management.<sup>8</sup> Among

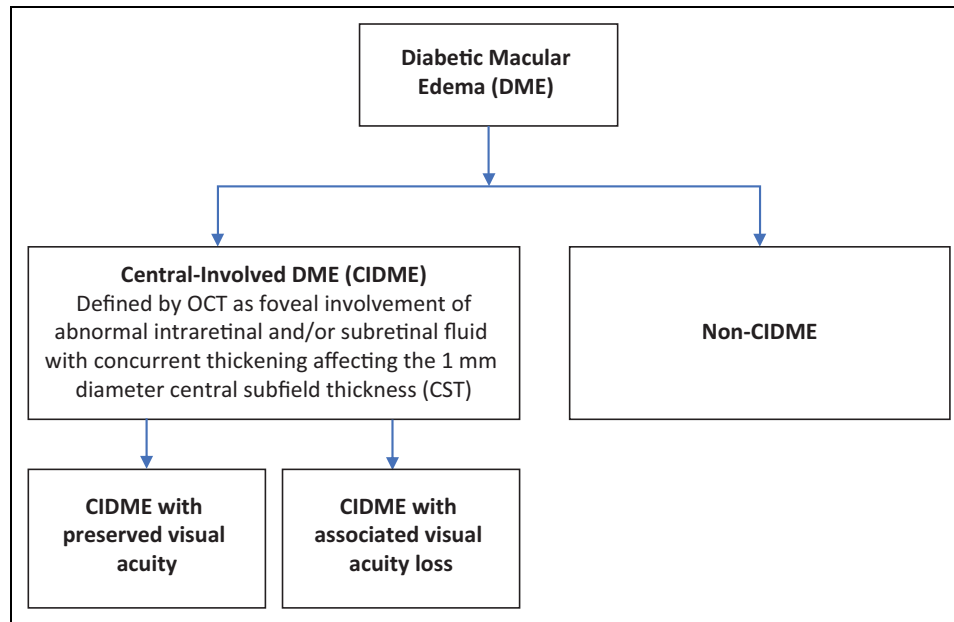
eyes with baseline VA of 20/32 to 20/40, all 3 agents achieved similar VA benefit, gaining approximately 1.5 lines by 6 months, and maintained these gains through 2 years. Among this population with baseline VA of 20/40 or better, however, anatomic benefit was superior both with aflibercept and ranibizumab compared with bevacizumab, as manifested by significantly less CST improvement with bevacizumab compared with the other agents. Among eyes with baseline VA of 20/50 or worse, while all 3 medications achieved robust VA gains, 2 to 3 lines by month 6, and maintained these gains through 2 years, aflibercept achieved both the greatest VA gain and CST reduction, improvements that were statistically significantly greater than those achieved with bevacizumab dosing both at 1 and 2 years. Although aflibercept outperformed ranibizumab 0.3 mg visually at 1 year in eyes with worse baseline VA, there was no significant visual or anatomic difference between the 2 drugs at year 2.

When managing CIDME with VA loss, data from prospective clinical trials are available to support both fixed and individualized dosing approaches. Four large phase 3 trials have validated fixed dosing with monthly ranibizumab or aflibercept,<sup>17,19</sup> or 5 monthly doses followed by every-other-month dosing with aflibercept.<sup>19</sup> Among large prospective trials using individualized dosing strategies, all have initiated therapy with a series of loading doses. RESTORE utilized 3 monthly doses of ranibizumab followed by monthly visits with as-needed (PRN) re-treatment.<sup>20</sup> Protocol T employed 6 monthly loading doses, unless VA improved to 20/20 with a normalized CST with no improvement or worsening for 2 injections, followed by PRN re-treatment; eyes with persistent DME at month 6 received protocol-required focal laser.

While PRN re-treatment criteria in the context of neovascular AMD are often consistent and triggered by any intraretinal or subretinal fluid, what constitutes DME requiring re-treatment has been highly variable between trials, highlighting the field's incomplete understanding of what amount, type, and location of DME can be safely observed and what fluid should be re-treated. While some trials have relied solely on VA, others have used a combination of VA and anatomy to drive re-treatment decisions.

During RESTORE, PRN re-treatments were based exclusively on VA, treatment being suspended if VA was 20/20 at 2 consecutive visits, or if there was no further VA improvement at 2 consecutive visits.<sup>20</sup> In Protocol T, treatment was suspended during the PRN phase if predefined stability criteria were met—no improvement or worsening at 2 consecutive injections in either VA (defined as a change of 5 or more letters) or anatomy (defined as a change of 10% or more in CST) and treatments were resumed if either vision or anatomy worsened.

Prospective data can also be used to support a treat-and-extend (TREX) approach to DME management. TREX-DME enrolled 150 eyes and reported similar improvements monthly compared with TREX-managed eyes using ranibizumab through 1 year of dosing, with anatomy being the primary driver determining the interval between treatments.<sup>21</sup>



**Figure 1.** Diabetic macular edema classification. OCT indicates optical coherence tomography.

### Long-Term Dosing Requirements in the Management of DME

The management burden for eyes with CIDME through 2 years of treatment is substantial and should be communicated with patients. For example, regardless of randomized arm, through 2 years of the DRCR Network Protocol T, patients underwent a mean of 23 clinical visits and received a mean of 15 to 16 intravitreal injections.<sup>8</sup> However, after an initial period of intensive anti-VEGF therapy for CIDME, several analyses have suggested that less-frequent anti-VEGF dosing may be effective at maintaining visual and anatomic gains in most patients, and that a clinically meaningful proportion of patients can maintain quiescent disease without ongoing treatment through at least 2 additional years of follow-up. For example, the DRCR Network Protocol I,<sup>22</sup> Open-Label Extension (OLE),<sup>23</sup> and ENDURANCE<sup>24,25</sup> studies have all reported that mean VA gains obtained with frequent ranibizumab or aflibercept dosing were maintained with individualized dosing resulting in a substantially reduced treatment frequency.

When data from the OLE<sup>23</sup> and ENDURANCE trials,<sup>25</sup> representing the fourth through fifth years of DME management, are considered together, 3 clinically relevant points can be distilled. First, approximately 25% of patients received no additional anti-VEGF dosing and did not experience DME recurrence. Second, indicating that the underlying disease process continues to be active in a substantial proportion of patients, both populations received approximately 3-4 intravitreal injections annually for control of DME. Third, both studies documented worsening of DR, including progression from nonproliferative (NPDR) to proliferative DR, in a clinically relevant proportion of eyes when anti-VEGF dosing

frequencies were reduced, a similar finding as observed in the second year of Protocol T when injection frequencies were reduced.<sup>26</sup> The long-term management of eyes with baseline CIDME necessitates regular clinical follow-up and evaluation for recurrence of DME, as well as progression of DR.

### When to Consider Incorporating Intravitreal Corticosteroids

While basic science as well as clinical data indicate that VEGF plays a substantial role in DME pathophysiology, there are alternative inflammatory pathways involved. Aqueous and vitreous analyses have identified elevated levels of numerous cytokines beyond VEGF among patients with DME compared with nondiabetics.<sup>27,28</sup> Anti-VEGF agents inhibit VEGF exclusively, while steroids are capable of modulating a multitude of inflammatory pathways including blockade of VEGF. The clinical relevance of this may be manifested in the finding of persistent DME following repeated anti-VEGF dosing.

For example, the DRCR Network Protocol T reported that after 2 years, the rates of persistent DME ranged from 44% with aflibercept to 68% with bevacizumab.<sup>29</sup> Therefore, many clinicians seek alternative treatments beyond anti-VEGF monotherapy in an attempt to further reduce CST and optimize VA. However, intravitreal steroids are commonly employed as second-line agents after anti-VEGF therapy because of concerns regarding cataract acceleration and intraocular pressure (IOP) elevation. According to the American Society of Retina Specialists 2017 Preferences and Trends Survey, when asked after how many anti-VEGF injections retina specialists would consider incorporating steroids, 38% of US specialists

responded 4-5 injections, and 28% responded 6-9 injections; less than 2% responded 1 injection.<sup>30</sup>

Multiple trial programs can inform our use of steroids in DME management. The DRCR Network Protocol I randomized 854 eyes equally to 4 arms: sham injection with prompt macular laser, triamcinolone (4 mg) with prompt macular laser, or ranibizumab with prompt or deferred macular laser.<sup>11</sup> Among the entire study population, both ranibizumab arms gained approximately 2 lines of VA and outperformed the sham and triamcinolone arms, both of which gained less than 1 line of VA through 1 year.

From an anatomic perspective, however, reductions in CST in the triamcinolone arm were similar to both ranibizumab arms and greater than sham. Furthermore, among 273 pseudophakic eyes at baseline, VA improvement in the triamcinolone arm was comparable to that in the ranibizumab arm at just under 2 lines of VA gained at 1 year. IOP elevation and cataract acceleration were both significantly more common in the triamcinolone arms; 50% of triamcinolone-treated eyes experienced a clinically relevant IOP elevation or were initiated on IOP-lowering medications compared with 9% to 11% of the other arms.

The 3-year, randomized MEAD trial led to FDA approval of the dexamethasone (0.7 mg) (DEX) implant.<sup>9</sup> Having received a mean of 4.1 injections over 3 years, the percentage of patients achieving  $\geq 15$ -letter VA improvement was greater with the DEX implant (22%) than sham (12%;  $P < .018$ ) and mean CST reduction was also greater with the DEX implant. From a safety perspective, cataract progression was higher in eyes treated with DEX (68%) vs sham (20%). IOP increases  $\geq 10$  mmHg from baseline occurred in 28%, and 4% of DEX and sham patients, respectively. IOP-lowering medications were prescribed in 42%, and 9% of DEX and sham patients, respectively. The incidence of glaucoma surgery due to steroid effect was 0.3%, or 1 patient within the DEX group.<sup>31</sup> Repeated DEX injections within MEAD did not appear to increase the severity of the IOP increases observed. Of note, patients within the MEAD trial could not be re-treated with DEX earlier than every 6 months. In practice, retina specialists typically treat with DEX as needed, which could be as often as every 2-4 months, depending on retinal thickness on OCT.

The 3-year, randomized FAME trial led to Food and Drug Administration (FDA) approval of the fluocinolone implant (0.19 mg, FAc), which can release steroid for up to 3 years. Having received a mean of 1.3 injections over 3 years, the percentage of patients achieving  $\geq 15$ -letter VA improvement was greater with the FAc implant (29%) than sham (19%;  $P = .018$ ).<sup>10</sup> From a safety perspective, 82% compared with 51% of phakic FAc and sham patients developed cataracts over 3 years, although this did not impair long-term VA outcomes following cataract extraction. IOP-lowering medications were used in 37% compared with 12% of FAc and sham-treated patients respectively over 3 years. While 4.8% of patients in the FAc group underwent incisional glaucoma surgery, notably, no patient treated in the FAc arm who received a prior ocular steroid required IOP-lowering surgery during FAME<sup>32</sup>; this

finding led to the FDA-approved labeling that FAc is indicated in “patients who have been previously treated with a course of corticosteroids and did not have a clinically significant rise in intraocular pressure.”

There remains a relatively limited amount of clinical trial data to guide the use of steroids in the management of patients incompletely responsive to anti-VEGF dosing. In the phase 2 DRCR Network Protocol U, after a run-in phase of 3 monthly ranibizumab injections, 116 eyes with persistent DME were randomized to either combination therapy with the dexamethasone implant and ranibizumab or ranibizumab (0.3 mg) monotherapy.<sup>33</sup> At 24 weeks, mean improvement in VA was not significantly different between the arms: 2.7 letters in the combination arm vs 3.0 letters in the monotherapy arm ( $P = .73$ ). However, more patients in the combination group improved by more than 15 letters ( $P = .03$ ), and patients in the combination arm had a greater decrease in CST ( $P < .001$ ). Clinically relevant IOP increases were more common in the combination arm ( $P < .001$ ). Interestingly, one-third of patients in the run-in phase were ineligible for randomization as their DME had sufficiently resolved following 3 additional ranibizumab injections, indicating a potential value of continuing monthly intravitreal anti-VEGF injections when at first there may be a limited response.

## Imaging in DME Management

Optimal DME management often employs multimodal imaging. Noninvasive OCT is the cornerstone of guiding DME management decisions, being used to confirm the presence of DME, quantify retinal thickness, and evaluate the effectiveness of intervention. For these reasons, patients with DME typically undergo OCT imaging at most, if not all, office encounters. In addition, OCT can be used to visualize individual retinal layers including specifically evaluating photoreceptor integrity through characterization of the external limiting membrane and ellipsoid zone as well as evaluating the more generalized disorganization of inner layers, which may have prognostic potential.<sup>34,35</sup>

Color fundus photography, fluorescein angiography (FA), and ultra-widfield (UW) imaging are adjunct modalities that can deliver valuable information. Physicians use photographs to document clinical findings, such as hemorrhage, lipid, and cotton-wool spots, that can help to stage the level of DR. Physicians can compare images longitudinally to look for DR progression and use images as a tool for patient education. Angiography can be used to evaluate retinal perfusion and vascular leakage.

Physicians may initiate DME treatment differently depending on multiple features, including whether vascular leakage is focal or diffuse and central or noncentral. Beyond the posterior pole, physicians can utilize ultra-widfield fluorescein angiography (UWFA) to more completely understand the severity of retinopathy and further guide treatment<sup>36</sup>; UWFA imaging may demonstrate neovascularization and nonperfusion in the periphery that may not otherwise be apparent, and this may alter classification and prognostication compared with clinical

exam or more-limited posterior pole fundus photography alone.<sup>36-39</sup> As physicians expand the use of anti-VEGF agents into the management of DR, it is likely that we may utilize a combination of UWFA and photography to guide therapy and tailor treatment intervals. Furthermore, in the dawning era of information technology and artificial intelligence,<sup>40</sup> such images may be particularly relevant; it is not difficult to imagine a scenario in which software algorithms immediately determine the diabetic retinopathy severity scale (DRSS) level and risk of progression according to a set of clinically relevant endpoints for a given patient at a given visit.

OCT angiography (OCTA), acquired through multiple, rapid-repeating B-scans, provides reliable, high-resolution, and efficient, noninvasive images of the retinal vasculature without intravascular dye injection.<sup>41</sup> Currently, although primarily a research tool, FDA-approved OCTA systems are commercially available. In the near term, 2 key advances appear likely with OCTA. First, OCTA is capable of detecting DR changes, such as enlargement of the foveal avascular zone and decreased capillary density, even before clinical signs of NPDR are apparent on examination or photography.<sup>42,43</sup> Such insights may enable prediction of progression to clinically apparent DR, or even serve as a screening tool for DM itself. Second, given the unique quantitative opportunities with OCTA, including precisely defining areas of nonperfusion<sup>44</sup> and capillary density parameters,<sup>45,46</sup> such imaging may allow more accurate reclassification of DR stages beyond the ETDRS DRSS and may inform response to pharmacologic therapy.<sup>47</sup>

## Surgical Intervention for DME

For decades, authors have debated the role of the vitreous-retina attachment in DME pathogenesis.<sup>48</sup> Animal studies have suggested that pars plana vitrectomy (PPV) increases vitreous oxygenation, and that this may decrease VEGF load.<sup>49</sup> Some surgeons advocate that PPV for DME may be beneficial. In terms of considering PPV for DME, it is worthwhile categorizing patients into those with and without retinal traction due to vitreomacular traction (VMT) and/or epiretinal membrane (ERM). While there are limited randomized clinical trials comparing PPV for DME with sham or laser therapy, there are no randomized trials comparing PPV with anti-VEGF pharmacologic therapy.

A 2017 meta-analysis of completed randomized trials reported<sup>50</sup> that while PPV produced both structural and functional benefit in eyes with DME, this functional benefit was not significantly better than that achieved with laser treatment, and the benefits of PPV seemed to decline over time. The DRCR Network has reported a nonrandomized study on the outcomes of PPV in patients with VMT associated with DR<sup>51</sup> in which 28% to 49% of eyes experienced VA improvement, and 13% to 31% experienced VA worsening. At this time, PPV may be considered in select patients with apparently causative macular traction related to either VMT or ERM.

## Real-World Dosing Frequencies and Outcomes

The FDA registration trials for ranibizumab (RISE/RIDE)<sup>6</sup> and aflibercept (VIVID/VISTA)<sup>19</sup> demonstrated that DME patients treated with fixed dosing gained roughly 2 lines of vision (10 letters) at 1 year. However, recommendations based on clinical trial protocols can be challenging to implement in routine clinical settings. Patients with DME are often in poor health and require complex medical care, so much so that many DME patients have difficulty adhering to frequent office visits, especially given that this disease often manifests within a working-age population.

In a health care claims database analysis, patients with DME averaged 25.5 health care visit days each year,<sup>52</sup> of which 4.4 visits were attributed to ophthalmic care. Supporting the perspective that anti-VEGF dosing in the real world appears to be substantially less than that given during registration trials on a population basis, 1 limited EMR study found that 95% of the participants received 6 or fewer anti-VEGF injections in the first year of treatment.<sup>53</sup>

While multiple studies have demonstrated that less-than-monthly treatment with anti-VEGF agents for DME can result in meaningful VA improvement, visual gains across multiple trials have been positively correlated with the number of injections, especially in the first year of treatment. Therefore, consistent dosing until maximal visual and anatomic improvement have been achieved is generally recommended.

## International Approaches to DME Management

Approaches to treating DME vary broadly from one country to another. Economics and resources play critical roles in determining management algorithms as well as resource allocation. In the developed world, treatment options are typically similar to the United States, although algorithms may vary somewhat, depending on guidelines often set by governmental agencies and regulations related to off-label use of bevacizumab and ziv-aflibercept.

In developing countries, where there may be limited access to imaging technology and intravitreal therapies, focal laser treatment may be used more frequently; it is worth noting that among eyes in the ETDRS study with 20/40 or worse VA,<sup>12</sup> approximately 40% gained 6 or more letters. Laser therapy is not only more affordable, but can have a longer duration of effect, and may be particularly worth considering when access to intravitreal therapies is limited.

## Limitations and Conclusions

Rather than a comprehensive review of all reported data on DME management, the current manuscript summarizes selected references based on perceived relevance and study design. Second, the conclusions of the incorporated references represent the authors' interpretations of the data. Finally, and

most critically, the current manuscript focuses solely on the management of DME, without addressing underlying DR; the pharmacotherapies used to treat DME can also have a significant impact on slowing DR progression, and in many cases reversing DR severity, and the field continues to move toward intervention at earlier stages of the disease.

DME management is complex, requiring clinical integration of multiple factors on an individualized basis including distinct subtypes, 6 potential intravitreal pharmacotherapies to employ, and recognition of the chronic nature of the underlying disease process in many eyes. While intravitreal pharmacotherapies are the current mainstay of treatment for CIDME and appear poised to remain so for the foreseeable future, DME treatments have changed over time and will continue to evolve. Ongoing trials, new pharmaceuticals, novel drug targets, and innovative devices hold great promise to continue to advance clinical options.

### Acknowledgment

The authors thank Jill Blim for administrative assistance in coordinating this manuscript.

### Ethical Approval

The current study is a summary of published literature and did not involve direct patient care.

### Statement of Informed Consent

Informed consent was not required due to the nature of the study.

### Declaration of Conflicting Interests

The author(s) declared the following potential conflicts of interest with respect to the research, authorship, and/or publication of this article: SJB: Consultant: Allergan, Genentech, Novartis, EyePoint Pharmaceuticals, and Zeiss. Research support: Apellis and Lowy Foundation. JDW: Consultant: Allergan, Genentech, and Regeneron Pharmaceuticals. Research support: Allergan, Apellis Pharmaceutical, Clearside Biomedical, Iconic Therapeutics, Genentech, Regeneron Pharmaceuticals, and Oxurion. Speaker: Allergan, Genentech, and Regeneron Pharmaceuticals. CCW: Consultant: Alimera Sciences, Allergan, Bayer, Clearside Biomedical, Genentech, Novartis, ONL Therapeutics, and Regeneron Pharmaceuticals. Research support: Allergan, Apellis Pharmaceutical, Clearside Biomedical, Iconic Therapeutics, Genentech, Regeneron Pharmaceuticals, DRCR Network, Novartis, Ophthotech, and Tyrogenex. Speaker: Regeneron Pharmaceuticals. HWF: Member of the DRCR Network Data Safety Monitoring Committee; opinions expressed in this manuscript do not represent the DRCR Network, but are the authors' opinions. CDR: Research support: Allergan, Alcon, Apellis, Aerpio, Clearside Biomedical, Iconic Therapeutics, Genentech, Regeneron, Novartis, DRCR Network, and Ophthotech. Consultant: Allergan, Alcon, Iconic, Genentech, Novartis, GSK, Shire, and Notal.

### Funding

The author(s) received no financial support for the research, authorship, and/or publication of this article.

### References

1. World Health Organization. Global report on diabetes. 2016. [http://apps.who.int/iris/bitstream/10665/204871/1/9789241565257\\_eng.pdf?ua=1&ua=1](http://apps.who.int/iris/bitstream/10665/204871/1/9789241565257_eng.pdf?ua=1&ua=1). Accessed April 17, 2019.
2. Menke A, Casagrande S, Geiss L, Cowie CC. Prevalence of and trends in diabetes among adults in the United States, 1988-2012. *JAMA*. 2015;314(10):1021-1029. doi:10.1001/jama.2015.10029
3. Solomon SD, Chew E, Duh EJ, et al. Diabetic retinopathy: a position statement by the American Diabetes Association. *Diabetes Care*. 2017;40(3):412-418. doi:10.2337/dc16-2641
4. Simo R, Sundstrom JM, Antonetti DA. Ocular Anti-VEGF therapy for diabetic retinopathy: the role of VEGF in the pathogenesis of diabetic retinopathy. *Diabetes Care*. 2014;37(4):893-899. doi:10.2337/dc13-2002
5. American Academy of Ophthalmology. *Preferred Practice Pattern: Diabetic Retinopathy*. San Francisco, CA: American Academy of Ophthalmology; 2016.
6. Nguyen QD, Brown DM, Marcus DM, et al. Ranibizumab for diabetic macular edema: results from 2 phase III randomized trials: RISE and RIDE. *Ophthalmology*. 2012;119(4):789-801. doi:10.1016/j.ophtha.2011.12.039
7. Korobelnik JF, Do DV, Schmidt-Erfurth U, et al. Intravitreal aflibercept for diabetic macular edema. *Ophthalmology*. 2014;121(11):2247-2254. doi:10.1016/j.ophtha.2014.05.006
8. Wells JA, Glassman AR, Ayala AR, et al. Aflibercept, bevacizumab, or ranibizumab for diabetic macular edema: two-year results from a comparative effectiveness randomized clinical trial. *Ophthalmology*. 2016;123(6):1351-1359. doi:10.1016/j.ophtha.2016.02.022
9. Boyer DS, Yoon YH, Belfort R Jr, et al. Three-year, randomized, sham-controlled trial of dexamethasone intravitreal implant in patients with diabetic macular edema. *Ophthalmology*. 2014;121(10):1904-1914. doi:10.1016/j.ophtha.2014.04.024
10. Campochiaro PA, Brown DM, Pearson A, et al. Sustained delivery fluocinolone acetonide vitreous inserts provide benefit for at least 3 years in patients with diabetic macular edema. *Ophthalmology*. 2012;119(10):2125-2132. doi:10.1016/j.ophtha.2012.04.030
11. Diabetic Retinopathy Clinical Research Network, Elman MJ, Aiello LP, et al. Randomized trial evaluating ranibizumab plus prompt or deferred laser or triamcinolone plus prompt laser for diabetic macular edema. *Ophthalmology*. 2010;117(6):1064-1077.e1035. doi:10.1016/j.ophtha.2010.02.031
12. Photocoagulation for diabetic macular edema. Early Treatment Diabetic Retinopathy Study report number 1. Early Treatment Diabetic Retinopathy Study Research Group. *Arch Ophthalmol*. 1985;103(12):1796-1806. doi:10.1001/archophth.1985.01050120030015
13. Campochiaro PA, Brown DM, Pearson A, et al. Long-term benefit of sustained-delivery fluocinolone acetonide vitreous inserts for diabetic macular edema. *Ophthalmology*. 2011;118(4):626-635.e2. doi:10.1016/j.ophtha.2010.12.028
14. Diabetic Retinopathy Clinical Research Network. DRCR Protocol V. Treatment for Central-Involved Diabetic Macular Edema in Eyes With Very Good Visual Acuity Study. <https://clinicaltrials>

- .gov/ct2/show/NCT01909791. Updated March 7, 2019. Accessed April 16, 2019.
15. Bressler SB, Qin H, Beck RW, et al. Factors associated with changes in visual acuity and central subfield thickness at 1 year after treatment for diabetic macular edema with ranibizumab. *Arch Ophthalmol*. 2012;130(9):1153-1161. doi:10.1001/archophthalmol.2012.1107
  16. Writing Committee for the UK Age-Related Macular Degeneration EMR Users Group. The neovascular age-related macular degeneration database: multicenter study of 92 976 ranibizumab injections: report 1: visual acuity. *Ophthalmology*. 2014;121(5):1092-1101. doi:10.1016/j.ophtha.2013.11.031
  17. Brown DM, Nguyen QD, Marcus DM, et al. Long-term outcomes of ranibizumab therapy for diabetic macular edema: the 36-month results from two phase III trials: RISE and RIDE. *Ophthalmology*. 2013;120(10):2013-2022. doi:10.1016/j.ophtha.2013.02.034
  18. Wykoff CC, Marcus DM, Midena E, et al. Intravitreal aflibercept injection in eyes with substantial vision loss after laser photocoagulation for diabetic macular edema: subanalysis of the VISTA and VIVID randomized clinical trials [published online December 22, 2016]. *JAMA Ophthalmol*. 2016. doi:10.1001/jamaophthalmol.2016.4912
  19. Heier JS, Korobelnik JF, Brown DM, et al. Intravitreal aflibercept for diabetic macular edema: 148-week results from the VISTA and VIVID studies. *Ophthalmology*. 2016;123(11):2376-2385. doi:10.1016/j.ophtha.2016.07.032
  20. Mitchell P, Bandello F, Schmidt-Erfurth U, et al. The RESTORE study: ranibizumab monotherapy or combined with laser versus laser monotherapy for diabetic macular edema. *Ophthalmology*. 2011;118(4):615-625. doi:10.1016/j.ophtha.2011.01.031
  21. Payne JF, Wykoff CC, Clark WL, et al. Randomized trial of treat and extend ranibizumab with and without navigated laser for diabetic macular edema: TREX-DME 1 year outcomes. *Ophthalmology*. 2017;124(1):74-81. doi:10.1016/j.ophtha.2016.09.021
  22. Elman MJ, Ayala A, Bressler NM, et al. Intravitreal ranibizumab for diabetic macular edema with prompt versus deferred laser treatment: 5-year randomized trial results. *Ophthalmology*. 2015;122(2):375-381. doi:10.1016/j.ophtha.2014.08.047
  23. Boyer DS, Nguyen QD, Brown DM, et al. Outcomes with as-needed ranibizumab after initial monthly therapy: long-term outcomes of the phase III RIDE and RISE trials. *Ophthalmology*. 2015;122(12):2504-2513e2501. doi:10.1016/j.ophtha.2015.08.006
  24. Wykoff CC, Le RT, Khurana RN, et al. Outcomes with as-needed aflibercept and macular laser following the phase III VISTA DME trial: ENDURANCE 12-month extension study. *Am J Ophthalmol*. 2017;173:56-63. doi:10.1016/j.ajo.2016.09.029
  25. Wykoff CC, Ou WC, Khurana RN, et al. Long-term outcomes with as-needed aflibercept in diabetic macular oedema: 2-year outcomes of the ENDURANCE extension study. *Br J Ophthalmol*. 2018;102(5):631-636. doi:10.1136/bjophthalmol-2017-310941
  26. Bressler SB, Liu D, Glassman AR, et al. Change in diabetic retinopathy through 2 years: secondary analysis of a randomized clinical trial comparing aflibercept, bevacizumab, and ranibizumab. *JAMA Ophthalmol*. 2017;135(6):558-568. doi:10.1001/jamaophthalmol.2017.0821
  27. Funk M, Schmidinger G, Maar N, et al. Angiogenic and inflammatory markers in the intraocular fluid of eyes with diabetic macular edema and influence of therapy with bevacizumab. *Retina*. 2010;30(9):1412-1419. doi:10.1097/IAE.0b013e3181e095c0
  28. Funatsu H, Noma H, Mimura T, Eguchi S, Hori S. Association of vitreous inflammatory factors with diabetic macular edema. *Ophthalmology*. 2009;116(1):73-79. doi:10.1016/j.ophtha.2008.09.037
  29. Bressler NM, Beaulieu WT, Glassman AR, et al. Persistent macular thickening following intravitreal aflibercept, bevacizumab, or ranibizumab for central-involved diabetic macular edema with vision impairment: a secondary analysis of a randomized clinical trial. *JAMA Ophthalmol*. 2018;136(3):257-269. doi:10.1001/jamaophthalmol.2017.6565
  30. Stone TW, ed. *ASRS 2017 Preferences and Trends Membership Survey*. Chicago, IL: American Society of Retina Specialists; 2017. [https://www.asrs.org/content/documents/\\_2017-asrs-pat-survey-results.pdf](https://www.asrs.org/content/documents/_2017-asrs-pat-survey-results.pdf). Accessed April 16, 2019.
  31. Maturi RK, Pollack A, Uy HS, et al. Intraocular pressure in patients with diabetic macular edema treated with dexamethasone intravitreal implant in the 3-year MEAD study. *Retina*. 2016;36(6):1143-1152. doi:10.1097/IAE.0000000000001004
  32. Parrish RK II, Campochiaro PA, Pearson PA, Green K, Traverso CE; FAME Study Group. Characterization of intraocular pressure increases and management strategies following treatment with fluocinolone acetonide intravitreal implants in the FAME trials. *Ophthalmic Surg Lasers Imaging Retina*. 2016;47(5):426-435. doi:10.3928/23258160-20160419-05
  33. Maturi RK, Glassman AR, Liu D, et al. Effect of adding dexamethasone to continued ranibizumab treatment in patients with persistent diabetic macular edema: a DRCR Network phase 2 randomized clinical trial. *JAMA Ophthalmol*. 2018;136(1):29-38. doi:10.1001/jamaophthalmol.2017.4914
  34. Sun JK, Lin MM, Lammer J, et al. Disorganization of the retinal inner layers as a predictor of visual acuity in eyes with center-involved diabetic macular edema. *JAMA Ophthalmol*. 2014;132(11):1309-1316. doi:10.1001/jamaophthalmol.2014.2350
  35. Sun JK, Radwan SH, Soliman AZ, et al. Neural retinal disorganization as a robust marker of visual acuity in current and resolved diabetic macular edema. *Diabetes*. 2015;64(7):2560-2570. doi:10.2337/db14-0782
  36. Wessel MM, Aaker GD, Parlitsis G, Cho M, D'Amico DJ, Kiss S. Ultra-wide-field angiography improves the detection and classification of diabetic retinopathy. *Retina*. 2012;32(4):785-791. doi:10.1097/IAE.0b013e3182278b64
  37. Silva PS, Dela Cruz AJ, Ledesma MG, et al. Diabetic retinopathy severity and peripheral lesions are associated with nonperfusion on ultrawide field angiography. *Ophthalmology*. 2015;122(12):2465-2472. doi:10.1016/j.ophtha.2015.07.034
  38. Patel RD, Messner LV, Teitelbaum B, Michel KA, Hariprasad SM. Characterization of ischemic index using ultra-widefield fluorescein angiography in patients with focal and diffuse recalcitrant diabetic macular edema. *Am J Ophthalmol*. 2013;155(6):1038-1044.e2. doi:10.1016/j.ajo.2013.01.007
  39. Diabetic Retinopathy Clinical Research Network. DRCR network protocol AA. Peripheral diabetic retinopathy (DR) lesions on

- ultrawide-field fundus images and risk of DR worsening over time. *Jaeb Center for Health Research*. <https://public.jaeb.org/drcrnet/stdy/239>. Accessed April 16, 2019.
40. Gulshan V, Peng L, Coram M, et al. Development and validation of a deep learning algorithm for detection of diabetic retinopathy in retinal fundus photographs. *JAMA*. 2016;316(22):2402-2410. doi:10.1001/jama.2016.17216
  41. Kashani AH, Chen CL, Gahm JK, et al. Optical coherence tomography angiography: A comprehensive review of current methods and clinical applications. *Prog Retin Eye Res*. 2017;60:66-100. doi:10.1016/j.preteyeres.2017.07.002
  42. de Carlo TE, Chin AT, Bonini Filho MA, et al. Detection of microvascular changes in eyes of patients with diabetes but not clinical diabetic retinopathy using optical coherence tomography angiography. *Retina*. 2015;35(11):2364-2370. doi:10.1097/IAE.0000000000000882
  43. Dimitrova G, Chihara E, Takahashi H, Amano H, Okazaki K. Quantitative retinal optical coherence tomography angiography in patients with diabetes without diabetic retinopathy. *Invest Ophthalmol Vis Sci*. 2017;58(1):190-196. doi:10.1167/iovs.16-20531
  44. Sambhav K, Abu-Amero KK, Chalam KV. Deep capillary macular perfusion indices obtained with OCT angiography correlate with degree of nonproliferative diabetic retinopathy. *Eur J Ophthalmol*. 2017;27(6):716-729. doi:10.5301/ejo.5000948
  45. Lin AD, Lee AY, Zhang Q, et al. Association between OCT-based microangiography perfusion indices and diabetic retinopathy severity. *Br J Ophthalmol*. 2017;101(7):960-964. doi:10.1136/bjophthalmol-2016-309514
  46. Soares M, Neves C, Marques IP, et al. Comparison of diabetic retinopathy classification using fluorescein angiography and optical coherence tomography angiography. *Br J Ophthalmol*. 2017;101(1):62-68. doi:10.1136/bjophthalmol-2016-309424
  47. Lee J, Moon BG, Cho AR, Yoon YH. Optical coherence tomography angiography of DME and its association with anti-VEGF treatment response. *Ophthalmology*. 2016;123(11):2368-2375. doi:10.1016/j.ophtha.2016.07.010
  48. Nasrallah FP, Jalkh AE, Van Coppenolle F, et al. The role of the vitreous in diabetic macular edema. *Ophthalmology*. 1988;95(10):1335-1339. doi:10.1016/S0161-6420(88)33004-6
  49. Stefansson E, Landers MB III, Wolbarsht ML. Increased retinal oxygen supply following pan-retinal photocoagulation and vitrectomy and lensectomy. *Trans Am Ophthalmol Soc*. 1981;79:307-334.
  50. Jackson TL, Nicod E, Angelis A, Grimaccia F, Pringle E, Kanavos P. Pars plana vitrectomy for diabetic macular edema: a systematic review, meta-analysis, and synthesis of safety literature. *Retina*. 2017;37(5):886-895. doi:10.1097/IAE.00000000000001280
  51. Diabetic Retinopathy Clinical Research Network Writing Committee, Haller JA, Qin H, et al. Vitrectomy outcomes in eyes with diabetic macular edema and vitreomacular traction. *Ophthalmology*. 2010;117(6):1087-1093.e3. doi:10.1016/j.ophtha.2009.10.040
  52. Wallick CJ, Hansen RN, Campbell J, Kiss S, Kowalski JW, Sullivan SD. Comorbidity and health care resource use among commercially insured non-elderly patients with diabetic macular edema. *Ophthalmic Surg Lasers Imaging Retina*. 2015;46(7):744-751. doi:10.3928/23258160-20150730-09
  53. Holekamp NM, Campbell J, Almony A, et al. Vision outcomes following anti-vascular endothelial growth factor treatment of diabetic macular edema in clinical practice. *Am J Ophthalmol*. 2018;191:83-91. doi:10.1016/j.ajo.2018.04.010