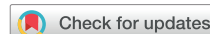

Guidelines for Performance, Interpretation, and Application of Stress Echocardiography in Ischemic Heart Disease: From the American Society of Echocardiography



Patricia A. Pellikka, MD, FASE, Chair, Adelaide Arruda-Olson, MD, PhD, FASE, Farooq A. Chaudhry, MD, FASE,* Ming Hui Chen, MD, MMSc, FASE, Jane E. Marshall, RDCS, FASE, Thomas R. Porter, MD, FASE, and Stephen G. Sawada, MD, Rochester, Minnesota; New York, New York; Boston, Massachusetts; Omaha, Nebraska; Indianapolis, Indiana

Keywords: Echocardiography, Stress, Guidelines, Imaging, Ischemic heart disease, Stress test, Pediatrics

This document is endorsed by the following ASE International Alliance Partners: Argentine Federation of Cardiology, Argentine Society of Cardiology, ASEAN Society of Echocardiography, Association of Echocardiography and Cardiovascular Imaging of the Interamerican Society of Cardiology, Australasian Sonographers Association, Canadian Society of Echocardiography, Chinese Society of Echocardiography, Cuban Society of Cardiology Echocardiography Section, Department of Cardiovascular Imaging of the Brazilian Society of Cardiology, Indian Academy of Echocardiography, Indian Association of Cardiovascular Thoracic Anaesthesiologists, Indonesian Society of Echocardiography, Iranian Society of Echocardiography, Israeli Working Group on Echocardiography, Italian Association of CardioThoracic and Vascular Anaesthesia and Intensive Care, Japanese Society of Echocardiography, Korean Society of Echocardiography, Mexican Society of Echocardiography and Cardiovascular Imaging, National Association of Cardiologists of Mexico, National Society of Echocardiography of Mexico, Philippine Society of Echocardiography, Saudi Arabian Society of Echocardiography, Venezuelan Society of Cardiology, Vietnamese Society of Echocardiography.

TABLE OF CONTENTS

I. Introduction	3		
II. Methodology	3		
a. Imaging	3		
b. Format for Image Display	5		
		c. Use of an Ultrasound Enhancing Agent	7
		III. Stress Testing Methods	8
		a. Exercise Stress Testing	8
		b. Pharmacologic Stress Testing	9

From Mayo Clinic, Rochester, Minnesota (P.A.P. and A.A.O.); Icahn School of Medicine at Mount Sinai, New York, New York (F.A.C.); Boston Children's Hospital, Harvard Medical School, Boston, Massachusetts (M.H.C.); Massachusetts General Hospital, Boston, Massachusetts (J.E.M.); University of Nebraska Medical Center, Omaha, Nebraska (T.R.P.); Indiana University School of Medicine, Indianapolis, Indiana (S.G.S.).

The following authors reported no actual or potential conflicts of interest in relation to this document: Ming Hui Chen, MD, MMSc, FASE; Jane E. Marshall, RDCS, FASE; Stephen G. Sawada, MD. The following authors reported relationships with one or more commercial interests: Farooq A. Chaudhry, MD, FASE, received a research grant, a restricted fellowship grant, and consulted for Bracco Diagnostics, a research grant from GE Healthcare, and consulted for Lantheus Medical Imaging; Patricia A. Pellikka, MD, FASE, served on the advisory board for Bracco Diagnostics and received research grants from GE Healthcare and Lantheus Medical Imaging, with money paid to her institution; Thomas R. Porter, MD, FASE, received a research grant and served on the speaker's bureau for Bracco Diagnostics, and received a research grant from Lantheus Medical Imaging. Dr. Adelaide Arruda-Olson was supported by the National Heart, Lung, and Blood Institute of the National Institutes of Health (award K01HL124045). The content is solely the responsibility of the authors and does not necessarily represent the official views of the National Institutes of Health.

*The American Society of Echocardiography and the Writing Group sadly note the passing of Dr. Farooq A. Chaudhry in August 2017, while this document was being written. It was our honor to work with Dr. Chaudhry on a topic that was very dear to him throughout his esteemed career.

Reprint requests: American Society of Echocardiography, Meridian Corporate Center, 2530 Meridian Parkway, Suite 450, Durham, NC 27713 (Email: ase@asecho.org).

Attention ASE Members:

Visit www.aseuniversity.org to earn free continuing medical education credit through an online activity related to this article. Certificates are available for immediate access upon successful completion of the activity. Nonmembers will need to join the ASE to access this great member benefit!

0894-7317/\$36.00

Copyright 2019 Published by Elsevier Inc. on behalf of the American Society of Echocardiography.

<https://doi.org/10.1016/j.echo.2019.07.001>

Abbreviations

ACC = American College of Cardiology
AQ = Acoustic quantification
ASE = American Society of Echocardiography
ASO = Arterial switch operation
BP = Blood pressure
CABG = Coronary artery bypass grafting
CAD = Coronary artery disease
CK = Color kinesis
CMR = Cardiac magnetic resonance
d-TGA = Dextro-loop transposition of the great arteries
DSE = Dobutamine stress echocardiography
ECG = Electrocardiogram
EF = Ejection fraction
ESE = Exercise stress echocardiography
FFR = Fractional flow reserve
HR = Heart rate
ICU = Intensive care unit
IHD = Ischemic heart disease
KD = Kawasaki disease
LA = Left atrial
LAD = Left anterior descending coronary artery
LBBB = Left bundle branch block
LDL = Low-density lipoprotein
LV = Left ventricular/ventricle
LVO = Left ventricular opacification
LVOT = Left ventricular outflow tract
MACE = Major adverse cardiovascular event
MI = Mechanical index
MR = Mitral regurgitation
MRI = Magnetic resonance imaging
mSv = Millisieverts
PET = Positron emission tomography
PROMISE = Prospective Multicenter Imaging Study for Evaluation of Chest Pain
PSS = Post-systolic shortening
PW = Pulsed-wave
ROC = Receiver-operator curves
RTMCE = Real-time myocardial contrast echocardiography
RV = Right ventricular
RWM = Regional wall motion
SPECT = Single-photon emission computed tomography

STE = Speckle-tracking echocardiography
STICH = Surgical Treatment of Ischemic Heart Failure
TAPSE = Tricuspid annular plane systolic excursion
TDI = Tissue Doppler imaging
TR = Tricuspid regurgitation
TTE = Transthoracic echocardiograms
UEA = Ultrasound enhancing agents
VLMI = Very low MI
WMSI = Wall motion score index
2D = Two-dimensional
3D = Three-dimensional

IV. Image Interpretation	10
a. Pathophysiology and Detection of Regional Wall Motion Abnormalities in Coronary Disease	10
b. Grading of Regional Function	11
c. Assessment During Stress and in Recovery	11
d. Assessment of Right Ventricular Function	12
e. Modality-specific Differences in the Regional and Global Left Ventricular Response to Stress	13
f. Reporting	13
g. Perfusion Imaging Assessment with Ultrasound Enhancing Agent	14
V. Quantitative Analysis Methods	15
VI. Accuracy	19
a. Blood Pressure Response to Stress	19
b. Microvascular Disease	20
c. Impact of Perfusion Imaging	20
d. Coronary Flow Reserve	20
e. Three-Dimensional Stress Echocardiography	20
VII. Risk Stratification and Prognosis	21
a. Extent and Severity of Wall Motion Abnormalities	21
b. Transient Ischemic LV Dilatation	21
c. RV Ischemia	21
d. Stress Echocardiography in Patients with Dyspnea	22
e. Stress Echocardiography in Patients with Left Bundle Branch Block	22
f. Preoperative Risk Stratification	23
g. Impact of Contrast on Prognosis	24
VIII. Assessment of Myocardial Viability	24
a. Assessment of Contractile Reserve	24
b. DSE Protocols for Assessing Viability	24
c. Interpretation of Wall Motion Response for Assessment of Viability	25
d. Accuracy of DSE for Detection of Viability	25
e. Quantitative Methods for Assessment of Viability	25
f. Current Considerations in Assessment of Viability	26
IX. Comparison with Other Imaging Modalities	26
X. Radiation-Induced Coronary Artery Disease	28
XI. Stress Echocardiography in Pediatric Patients and Congenital Heart Disease	28
a. Pediatric Cardiac Transplantation	28

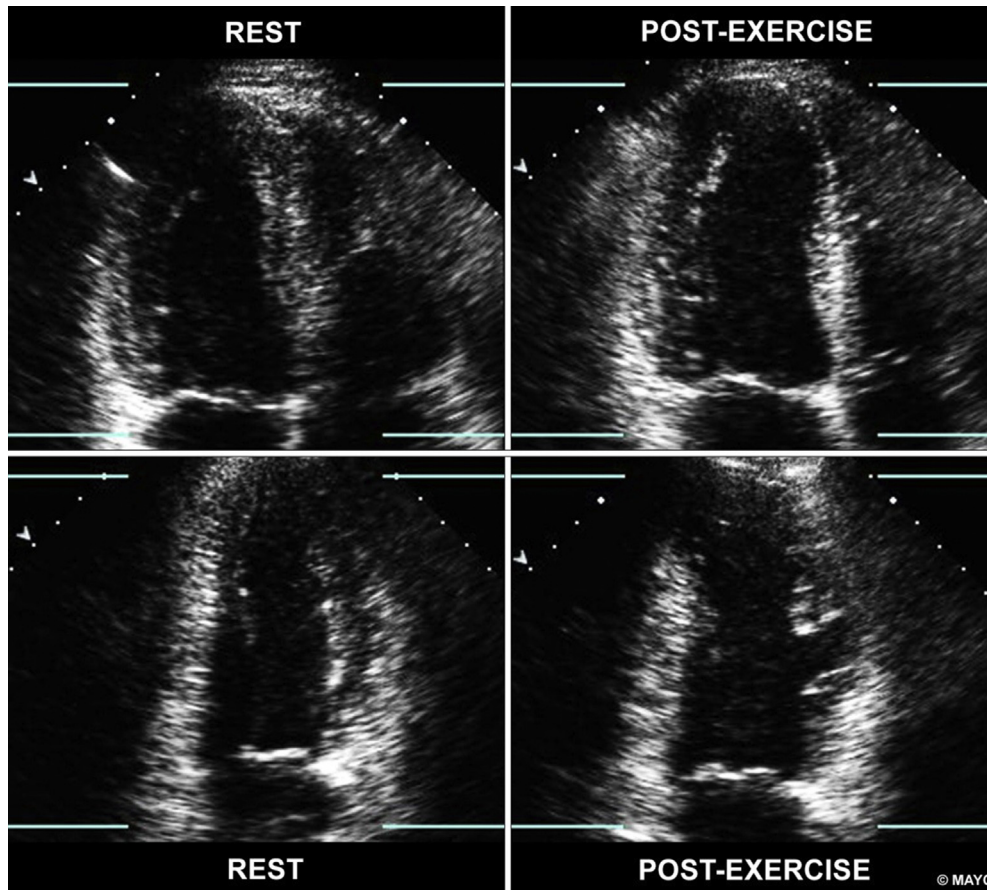


Figure 1 Side-by-side viewing of apical 4- and 2-chamber images, at rest and immediately post-exercise. In the four-chamber view, the left ventricle is shown on the left-hand side of the screen. With exercise, the LV cavity dilates (right quadrants) and there are regional wall motion abnormalities in the LAD territory (also seen in [Video 1](#), available online at www.onlinejase.com).

b. Kawasaki Disease	28
c. Anomalous Origin of a Coronary Artery	31
d. Transposition of the Great Arteries, Status Post Arterial Switch Operation	31
e. Familial Hypercholesterolemia	31
XII. Training Requirements and Maintenance of Competency	31
a. Sonographer Training	31
b. Physician Training	31
c. Training for Contrast Perfusion Imaging	32
d. Training for Pediatric Stress Echocardiography	32
XIII. Appropriate Use Criteria and Stress Echocardiography	32
XIV. Summary	32

I. INTRODUCTION

Since the 2007 publication of the American Society of Echocardiography (ASE) guidelines for stress echocardiography,¹ new information has become available about the methodology of stress echocardiography, including test protocols, standards for interpretation (including quantitative methods of assessment and applica-

tion of strain rate imaging), appropriateness of testing, comparison with other modalities for assessing ischemic heart disease (IHD), safety of stress echocardiography, application of the technique in children and special populations, prognostic value, and role of ultrasound enhancing agents (UEA) and perfusion imaging. This updated document includes this new information and summarizes current practice recommendations and training requirements. Additionally, a class of recommendation and level of evidence for diagnostic strategies using stress echocardiography have been added. These recommendations are made according to the 2015 American College of Cardiology/American Heart Association clinical practice guidelines.² Specific recommendations and main points are identified in bold. Although stress echocardiography may be applied in the assessment of many diverse cardiac conditions,^{3,4} the current document describes its applications in IHD. Supplementary online content of this document includes 32 illustrative video clips and their legends (see [Videos 1-32](#), available online at www.onlinejase.com) for readers interested in visual examples of normal, ischemic, contrast, perfusion, and viability stress echocardiograms, as well as quantitative methods of analysis (for additional data, see [Supplementary Tables 1-5](#)).

II. METHODOLOGY

a. Imaging

The baseline resting echocardiogram performed prior to initiation of stress should include a screening assessment of cardiac structure and

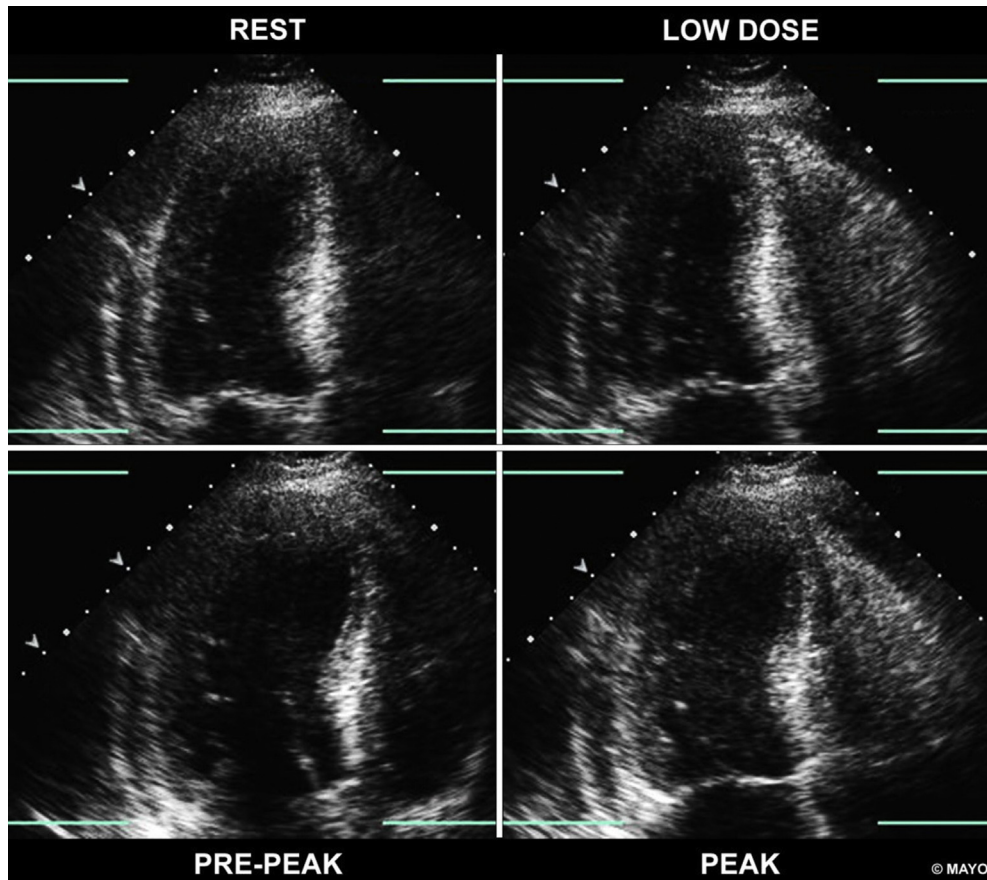


Figure 2 Side-by-side viewing of apical 4-chamber images during a DSE. In the four-chamber view, the left ventricle is shown on the left-hand side of the screen. Images were acquired at rest, low dose, pre-peak and peak stress. Ischemia is manifested as an increase in end-systolic size with stress (also shown in [Video 2](#), available online at www.onlinejase.com).

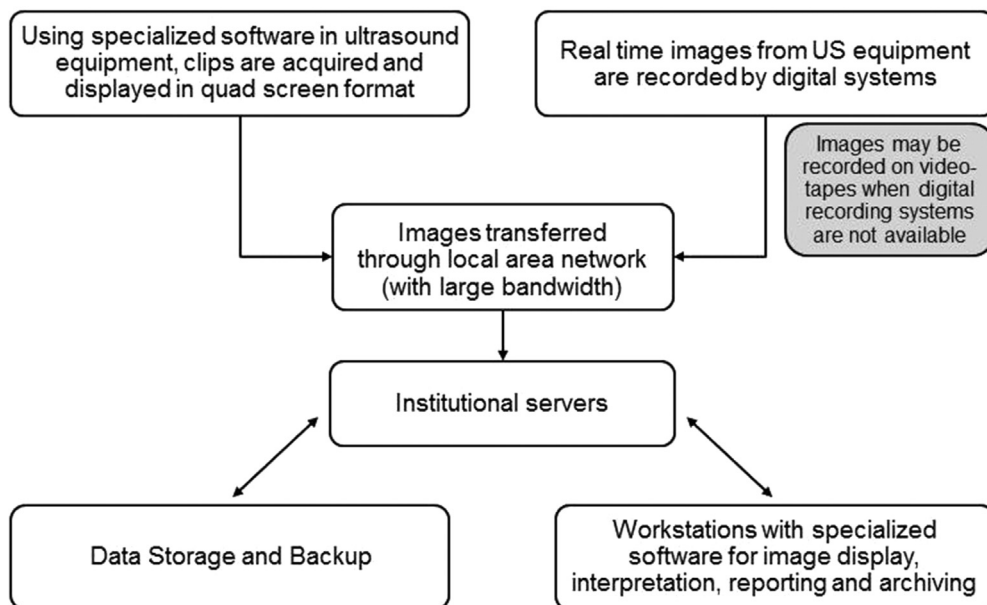


Figure 3 Systems architecture from a stress echocardiography laboratory. The digital images may be transferred from the ultrasound system through a computer network to departmental servers, then to computer workstations for their offline analysis and interpretation. Network systems with large bandwidth and servers with large archiving capacity are required. Serial stress examinations may be digitally archived and retrieved for side-by-side comparison of images.

Table 1 Optimal machine settings and UEA administration techniques for LVO during stress echocardiography

Imaging technique	Gain/Frame rate	Mechanical index	UEA administration	Key additional points
B-mode harmonic	<70% Gain Time gain compensation set higher in near field Frame rate: 20-30 Hz	MI < 0.3 for harmonic B-mode	0.1 ml IV Definity* 0.2-0.4 ml IV Optison* 0.5-1.0 ml IV Lumason* 3-5% Definity Infusion 10% Optison/Lumason Infusion	Lower frame rate prevents apical destruction; also, can move focus to near field Lower doses required at peak stress
Very low MI Imaging	<70% Gain Time gain compensation set higher in near field Frame rate: 20-25 Hz	MI < 0.2 for very low MI pulse sequence schemes MI 0.8-1.0 flashes to clear myocardial contrast and improve border delineation Focus at mitral valve plane	0.1 ml IV Definity* 0.2-0.4 ml IV Optison* 0.5-1.0 ml IV Lumason* 3-5% Definity infusion 10% Optison/Lumason infusion	With very low MI pulse sequence schemes, myocardial contrast can be cleared with high 0.8-1.0 MI "flash" impulses (5-10 frames) Lower doses and lower overall gain settings needed at peak stress

*Each bolus should be followed by a 5-10 ml IV saline flush administered over 20 seconds.

function, including segmental and global ventricular function, chamber sizes, wall thickness, and cardiac valves, unless echocardiography has recently been performed. These baseline echocardiographic images may demonstrate causes of cardiac symptoms including pericardial effusion, hypertrophic cardiomyopathy, active myocardial ischemia, aortic dissection, or takotsubo/stress cardiomyopathy, and may occasionally obviate the need for stress testing. The presence of any condition that may make stress unsafe (e.g., severe valvular heart disease in a symptomatic patient) should be noted. In such circumstances, the stress portion of the test may be postponed or canceled, a decision that should be individualized for each patient scenario. Tissue harmonic imaging provides the best resolution of endocardial borders and should be used. B-color can also improve visual discrimination of endocardial borders and should also be used as needed.

Standard views for assessment of regional wall motion and thickening include the parasternal long- and short-axis images and apical 4- and 2-chamber views. Additional views that are desirable are the apical long axis view, which shows the same walls as the parasternal long-axis view, but may be of better quality in some patients, and a short-axis view of the apex, which may be obtained from with the parasternal window, apical window, or both. Acquisition and display of the apical images with the left ventricle on the left-hand side is frequently illustrated in this document. This allows acquisition of 4-chamber, long-axis, and 2-chamber views with a simple 90° clockwise rotation of the transducer. All segments can be seen very quickly with this maneuver. Occasionally, subcostal views may provide additive information.

b. Format for Image Display

In the current era, ultrasound systems provide direct digital output for display of images. Stress imaging software allows for acquisition and side-by-side display of rest and stress images, which maximizes accuracy of interpretation. This is particularly helpful when resting wall motion abnormalities are present. Most laptop and larger systems have such software. Work stations and image review software typically allow simultaneous viewing of at least 4 images, each image representing a single cardiac cycle that may be replayed in a continuous loop, adjusted for heart rate (HR), so that rest and stress images

appear synchronous, playing at similar speeds (Figure 1, Videos 1-2, available online at www.onlinejase.com). It has previously been demonstrated that the accuracy of interpretation of stress echocardiography is improved by visualization of more than a single cardiac cycle in each view.⁵ This is particularly true for stress images, as respiratory artifact, arrhythmia, and translational motion of the heart can compromise visualization of a wall or portion of a view. Thus, multiple cardiac cycles should be reviewed for each view, particularly at peak stress. This was previously accomplished with videotape but can now be accomplished with digital recording software (Video 3, available online at www.onlinejase.com). Compared to videotape, the digital recording has the advantages of improved image resolution, avoidance of image degradation over time, and conservation of physical space that would be needed for storage of videotape. However, if digital recording software is unavailable, another approach is to display one rest image and three stress images in the remaining quadrants, with one quadrant display for each view. For treadmill exercise studies, three immediate post-exercise cardiac cycles should be displayed with one rest image for each view if a continuous video record is unavailable (Video 4, available online at www.onlinejase.com). For multistage bicycle, pharmacologic, and pacing studies it is also preferable to have more than one peak stress image from each view available for review. Additional images obtained in the early recovery period may enhance the sensitivity of dobutamine stress echocardiography (DSE) and exercise stress echocardiography (ESE), particularly in patients with concentric remodeling and very small left ventricular (LV) cavities. Recovery imaging may also identify regions with stunning.

For DSE, the images from the peak stress stage are usually compared to rest, low dose, and intermediate dose or pre-peak images (Figure 2, Video 2, available online at www.onlinejase.com); however, some laboratories prefer to show rest, low dose, peak stress, and early recovery stages in the quad-screen format. For bicycle exercise, as images are acquired during exercise, the images from low to intermediate workload stages should be compared to those of rest and peak stress. With any form of stress echocardiography, wall motion abnormalities are sometimes more apparent in immediate or early recovery. Therefore, it is recommended that all imaging views are repeated at that time.

Table 2 Summary of stress testing modalities

	Exercise	Inotropes and/or Chronotropes	Vasodilator
	Bicycle/Treadmill	Dobutamine (synthetic catecholamine)	Dipyridamole/Adenosine
Physiology	- Preserves integrity of the electro-mechanical response	- Stimulates beta-1 adrenoceptors with the effect of increased heart rate and/or contractility	- Increases coronary blood flow through effects on adenosine A _{2A} receptors
Test selection	- Preferred stress for patients who can attain an adequate level of exercise for known or suspected CAD - Bicycle stress is preferred for assessment of diastolic function	- Performed when a patient is unable to exercise and for known or suspected CAD - Preferred choice for assessment of myocardial viability	- Preferred test for myocardial perfusion
Characteristics	- Increases myocardial oxygen demand	-Increases myocardial oxygen demand	- Increases coronary blood flow
Hemodynamic response			
Heart rate	↑↑	↑↑	↑
Stroke volume	↑↑ through Frank-Starling mechanism	↓ or no change	No significant change
Systolic blood pressure	↑↑ by 50%	↑	↓
Contractility	↑	↑ 4 to 5-fold	No change
Myocardial blood flow	↑	↑	↑ 3 to 5 times that of resting blood flow
Contraindications	- Unstable or complicated acute coronary syndrome - Serious cardiac arrhythmias (VT, complete A-V block). - Moderate to severe systemic hypertension (resting systolic blood pressure >180 mmHg)	- Hemodynamically significant LV outflow tract obstruction - Unstable or complicated acute coronary syndrome - Serious cardiac arrhythmias (VT, complete A-V block) - Severe systemic hypertension (resting systolic blood pressure >180 mmHg)	- Pronounced active bronchospastic airway disease (cause bronchospasm) - Significant hypotension (since these drugs lower the blood pressure) - Unstable or complicated acute coronary syndrome - Serious cardiac arrhythmias (VT, complete A-V block)

Bruce protocol:				
Stage	Grade (percent)	Speed (mph)	Total time (min)	METS*
1	10	1.7	3	5
2	12	2.5	6	7
3	14	3.4	9	10
4	16	4.2	12	13
5	18	5	15	15
6	20	5.5	18	18
7	22	6	21	20

* metabolic equivalents - 1 MET = 3.5 mL O₂/kg/min

Figure 4 Bruce treadmill exercise protocol.

Supine Bicycle Protocol

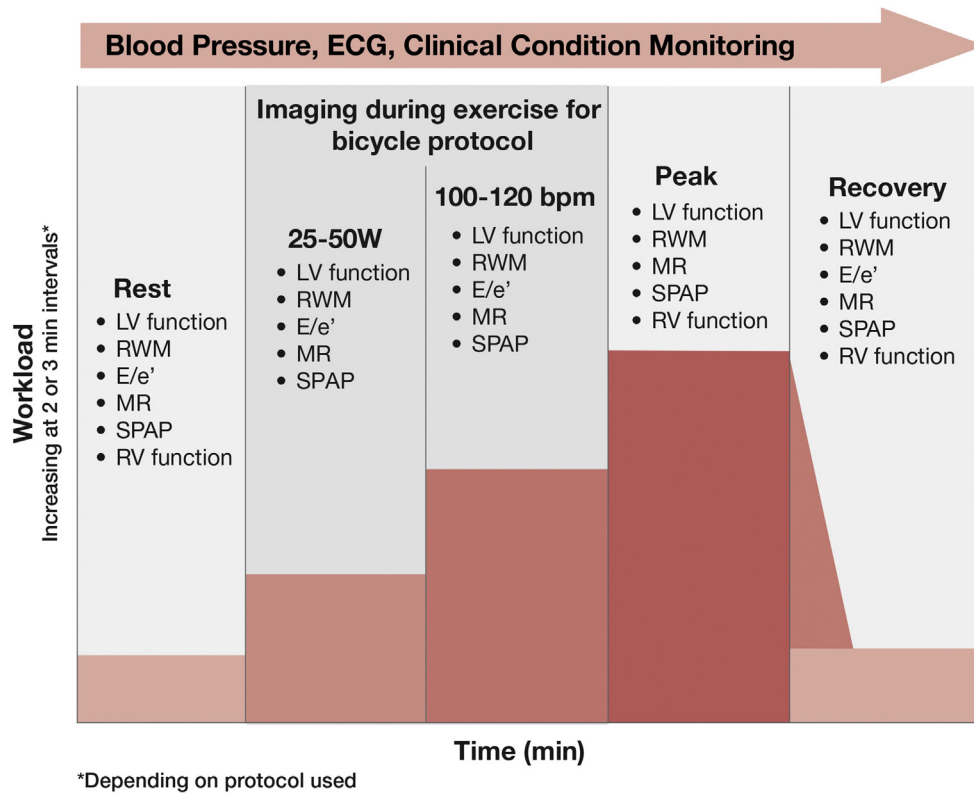
Stage	1	2	3	4	5	6	7	8	9	10
Watts	25	50	75	100	125	150	175	200	225	250
METS	2.4	3.7	4.9	6.1	7.3	8.6	9.8	11.0	12.2	13.5
Stage length	2	2	2	2	2	2	2	2	2	2
Total time	2	4	6	8	10	12	14	16	18	20

Patient pedals at a constant rate of 60 revolutions per minute
Resistance increases at each stage

Figure 5 Commonly used bicycle exercise protocol.

The digital images may be transferred from the ultrasound system through a computer network to departmental servers, then to computer workstations for their offline analysis and interpretation. Network systems with large bandwidth and servers with large

archiving capacity are required. Serial stress examinations may be digitally archived and retrieved for side-by-side comparison of images. An example of the systems architecture from a stress echocardiography laboratory is displayed in [Figure 3](#).



Diagnostic end-points	Causes of test cessation	Abnormal test
<ul style="list-style-type: none"> • Workload at least 80% predicted for age and sex • Marked ECG positivity • Obvious echo positivity • Severe chest pain 	<ul style="list-style-type: none"> • Intolerable symptoms • Muscular exhaustion • Severe hypertension (220/120 mmHg) • Symptomatic hypotension • Arrhythmias (SVT, new AF, frequent or complex ventricular ectopy) 	<ul style="list-style-type: none"> • Symptoms: angina, syncope or near-syncope, fatigue at low workload • Ischemia <ul style="list-style-type: none"> - New or worsening RWMA • Arrhythmias • Other**

**E/septal e' > 15, pulmonary hypertension, or ischemic mitral regurgitation may also develop in some patients

Figure 6 The various stages and parameters that can be assessed for the ESE examination are shown. Endpoints are provided (lower panel). Adapted from Lancellotti P, Pellikka PA, Budts W, Chaudhry FA, Donal E, Dulgheru R, et al. The clinical use of stress echocardiography in non-ischaemic heart disease: recommendations from the European Association of Cardiovascular Imaging and the American Society of Echocardiography. *Eur Heart J Cardiovasc Imaging* 2016;17:1191-1229, by permission of the European Association of Cardiovascular Imaging.

Key Points

1. For treadmill exercise protocols, images obtained at rest and immediately after exercise should be compared side-by-side using quad-screen format.
2. For pharmacologic stress echocardiography, images from peak stress stages should be compared to rest, low dose, and pre-peak or early recovery stages using quad-screen format.
3. Obtaining data from multiple cardiac cycles at peak stress enhances the accuracy of test interpretation. For continuous recording of rest and stress images, the use of digital recording software is preferable to recording on videotape.

c. Use of an Ultrasound Enhancing Agent

There are now three approved ultrasound enhancing agents for improving endocardial border delineation. The use of UEAs has greatly

improved image quality and reader confidence of interpretation, as well as the feasibility of stress echocardiography.⁶⁻¹⁰ Abundant literature supports the safety of the use of these agents in nonpregnant adults. Anaphylactoid reactions are rare but laboratories using UEA must be familiar with recognizing and treating these.¹¹ The UEA may be administered either as small boluses (0.1 ml for Definity; 0.2-0.4 ml for Optison, and 0.5-1.0 ml for Lumason) or as a dilute continuous infusion (ranging from 3-10%; see Table 1). When used for left ventricular opacification (LVO), current guidelines recommend its use whenever two or more contiguous segments or any coronary territory cannot be adequately visualized.^{12,13} Segmental visualization is critical for the detection of coronary artery disease (CAD). Visualization of all segments at rest and during stress is optimal for determining the extent of inducible ischemia or presence of infarction. The 2018 ASE guidelines¹¹ outline specific protocols for UEA administration.

The administration (whether by bolus or continuous infusion) should be sufficient to opacify the entire LV cavity without swirling artifact in the apex or attenuation of basal segments due to acoustic shadowing. To achieve these goals, the mechanical index (MI) should be reduced to less than 0.3, and either a harmonic low MI setting (0.2-0.3) or very low MI (<0.2) fundamental non-linear pulse sequence scheme should be used.¹³ The very low MI (VLMI) multi-pulse sequence schemes prevent microbubble destruction, enhance the signal from microbubbles, and reduce signal from artifacts and background tissue, allowing excellent delineation of endocardial borders (Videos 5 and 6, available online at www.onlinejase.com). Since VLMI imaging pulse sequence schemes detect non-linear fundamental frequency signals, there is significantly less far field attenuation in difficult to image patients, resulting in improved basal segment delineation when compared to standard low MI harmonic imaging (Videos 7 and 8, available online at www.onlinejase.com). Specific machine settings for rest and stress image acquisition, and UEA administration are given in Table 1.

Key Points

1. UEAs should be utilized during stress echocardiography whenever two or more contiguous segments cannot be visualized or a coronary artery territory cannot be completely visualized (Class of Recommendation I; Level of Evidence B).
2. Use of very low dose bolus injections (0.1 ml of Definity, 0.2-0.4 ml of Optison, and 0.5-1.0 ml of Lumason) followed by slow saline flushes is optimal for reducing cavity shadowing. Alternatively, Definity has been given as a 3-5% dilution in normal saline, and Optison has been infused as a 10% dilution. (Class of Recommendation I, Level of Evidence C).
3. VLMI imaging pulse sequence schemes that detect non-linear fundamental frequency responses at <0.2 MI are recommended for optimal LVO and reduced basal segment attenuation (Videos 5-8, available online at www.onlinejase.com). Brief high MI (>0.8) impulses (5-15 frames) can be used to clear the myocardium and improve endocardial border resolution.¹⁰ (Class of Recommendation IIa, Level of Evidence B)

III. STRESS TESTING METHODS

Exercise and pharmacologic testing modalities, including physiologic effect, test selection, hemodynamic response, and contraindications are compared in Table 2.

a. Exercise Stress Testing

If the patient is able to exercise, then exercise stress is considered the test of choice for most assessments of myocardial ischemia because it preserves the normal electromechanical response and can provide important prognostic information about functional status. Treadmill or bicycle (upright or supine) exercise can be used in ESE. For treadmill testing, the Bruce protocol (Figure 4) is utilized most often in the echocardiography lab and images are obtained at rest, immediately after peak exercise, and at recovery.¹⁴ The patient exercises at 3-minute stages of progressively increasing difficulty until exercise-limiting symptoms, or significant abnormalities in blood pressure, heart rhythm, or ST segments are noted.¹⁵ It is critical to obtain the post-exercise images as soon as possible (within 1-2 minutes) since wall motion changes may normalize.¹⁶ Satisfactory quality images obtained within this time frame should be considered diagnostic. Although heart rate recovers rapidly in some patients after exercise, this is prognostically a good sign and does

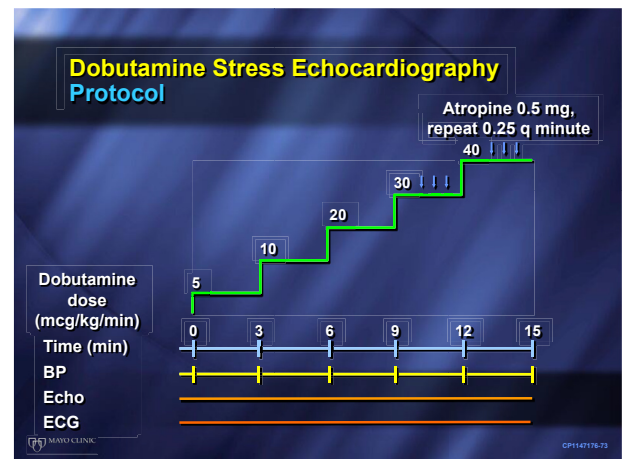


Figure 7 A commonly used DSE protocol is shown. Continuous imaging allows determination of the heart rate at which ischemia first develops (ischemic threshold).

not diminish the utility of ESE. For bicycle stress, the initial workload begins at 25 watts and increases every 2 to 3 minutes until limiting symptoms or arrhythmias occur, or if significantly abnormal findings are observed on the echocardiographic images obtained during exercise¹⁷ (Figure 5). Although some centers terminate exercise when 85% of the age-predicted maximum heart rate is achieved, continuing exercise to the development of symptoms increases the sensitivity of testing, and may uncover abnormalities that occur only at a high workload. The achieved workload and percent of the predicted workload for age and sex should be recorded; failure to achieve at least 80% of the predicted workload may diminish the sensitivity of the test for prediction of ischemia. Atropine has been administered in conjunction with ESE in an attempt to prolong the tachycardia and facilitate the detection of ischemia.¹⁷ However, it has been demonstrated that heart rate still declines exponentially during recovery and atropine administration therefore is not advised during exercise testing. One of the most advantageous aspects of supine bicycle stress is that cardiac function can be evaluated frequently during incremental levels of exercise, particularly in patients with resting wall motion abnormalities and also applied to the assessment of myocardial viability.¹⁸ Several studies have evaluated the use of low level ESE to test for viable myocardium. The low level exercise study uses a 3 minute/25 watts protocol, monitoring heart rate (HR), wall motion, and blood pressure (BP) every minute. Viability is indicated by the stress-induced development of myocardial thickening of segments that are severely hypokinetic to akinetic at rest. To determine if there is viability, careful observation for myocardial thickening of these segments is required during the low level of stress and avoidance of a rapid rise in HR that might produce an ischemic response.¹⁹⁻²¹ Stress echocardiography has an accuracy similar to that of positron emission tomography (PET) in detecting reversible dysfunction in patients with hibernating myocardium.²²

In addition to coronary flow reserve assessment, the cardiac hemodynamic response to exercise also can be evaluated to distinguish the symptoms of ischemia versus symptoms caused by diastolic dysfunction.²³⁻²⁶ Abnormal diastolic function changes may occur before systolic wall motion abnormalities. Diastolic parameters can be recorded near peak exercise or, when detection of ischemia is the primary test objective, after wall motion has been assessed. Obtaining the diastolic parameters shortly after peak exercise may allow for less heart rate-mediated fusing of the mitral E and A waves and therefore improved measurement accuracy. Diastolic function parameters that should be

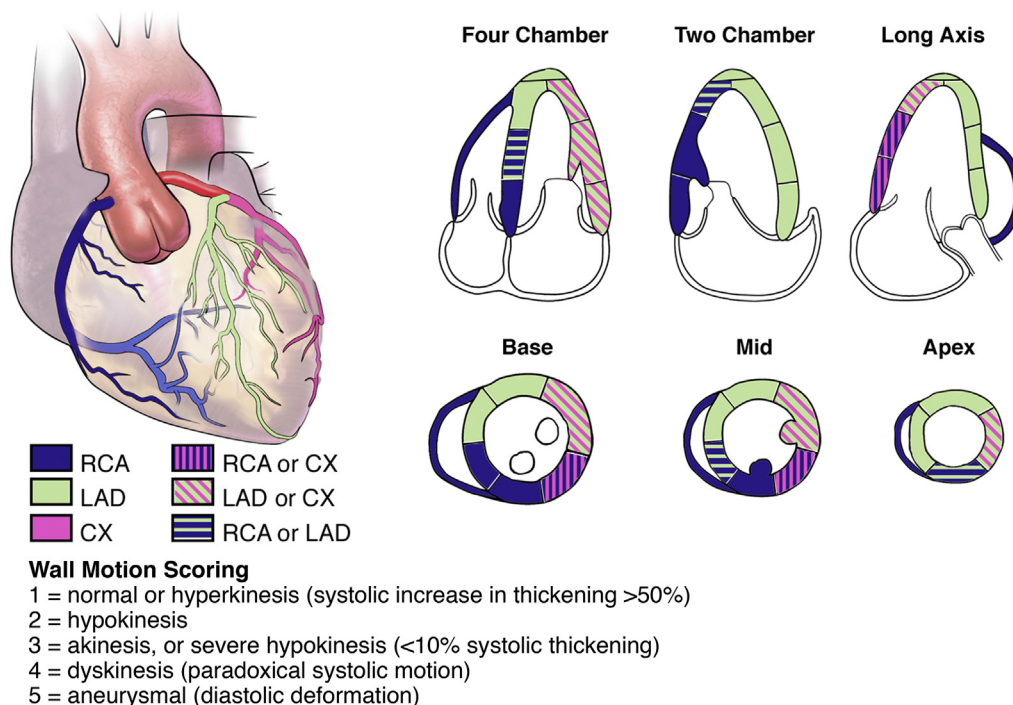


Figure 8 Typical distributions of the right coronary artery (RCA), the LAD, and the circumflex coronary artery (CX). The arterial distribution varies among patients. Some segments have variable coronary perfusion.⁴⁷ Adapted with permission from Lang et al.⁴⁷ The scoring system for segmental scores is tabulated.

obtained at rest and stress, particularly in the patient referred for evaluation of dyspnea, include mitral inflow E and A velocities, mitral annular e' velocities, and peak velocity of tricuspid regurgitation (TR). (Class of recommendation IIa, Level of evidence B). Average E/e' >14 or septal E/e' >15 with exercise indicates increased filling pressure; TR velocity must be considered in the context of increased pulmonary blood flow. Pulmonary vein velocities, mitral deceleration time, and left atrial (LA) volume index can also be useful, particularly if a transthoracic echocardiogram has not already been performed. Color Doppler assessment of mitral regurgitation (MR) at baseline and during peak exercise can allow detection of ischemic mitral regurgitation. Figure 6 illustrates the various stages and parameters that can be assessed for ESE.⁴ ESE is extremely safe with little risk of serious harm.^{27,28} Arrhythmias or BP abnormalities may occur but usually resolve quickly after test termination.

b. Pharmacologic Stress Testing

Pharmacologic stress testing (dobutamine or vasodilator) is an alternative modality for myocardial ischemia assessment when a patient is unable to exercise. DSE is also the most commonly used modality for myocardial viability assessment by stress echocardiography. Dobutamine is usually delivered in graded doses starting at 5 µg/kg/min and increasing at 3-minute intervals to 10, 20, 30 and 40 µg/kg/min^{29,30} (Figure 7).⁴ Low dose dobutamine, with a beginning dose as low as 2.5 µg/kg/min, may facilitate recognition of myocardial viability in abnormal segments.³¹ When target HR cannot be achieved with dobutamine alone, atropine can be added to increase the sensitivity of DSE, particularly in patients taking beta-blockers and in those with single-vessel disease.³² Failure to achieve target heart rate reduces the sensitivity of DSE for detection of ischemia. Atropine is delivered in doses of 0.25 to 0.50 mg at 1 min intervals, as needed to achieve target heart rate, to a total of 1.0 to 2.0 mg. The smaller dosage increment (0.25 mg) is suggested in elderly patients, patients with small body habitus, and in

those close to the target heart rate. The minimum dose should be used to avoid side effects, including central nervous system toxicity, and a lower total dose (1.0 mg) is recommended in patients with prior neuropsychiatric symptoms or body mass index less than 24 kg/m².³³ Atropine delivery at the 20 or 30 µg/kg/min dose of dobutamine, rather than the 40 µg/kg/min dose, facilitates achieving the target HR (85% of the age-predicted maximum HR) earlier with fewer side effects and shortens the testing time, particularly if HR is not increasing as expected.^{34,35} Endpoints for termination of the test include achievement of the target HR, hypotension, new or worsening wall motion abnormalities, significant arrhythmias, severe hypertension, and intolerable symptoms.³⁰ Withholding beta-blockers will facilitate achievement of the target HR but may be accompanied by hypertension or arrhythmias, depending on the indication for the medication. Elimination of the beta-blocker effect would require withholding these agents for 5 half-lives, a practice that is rarely performed. Beta-blockers may be administered to reverse the effects of dobutamine and may increase the test sensitivity when delivered at peak stress or recovery.^{30,36} Pharmacologic stress testing has been shown to be very safe, and may be supervised by physicians or specially trained registered nurses.²⁷ Patients may develop minor arrhythmias such as atrial or ventricular premature beats, or more significant arrhythmias such as atrial fibrillation and/or nonsustained ventricular tachycardia. These arrhythmias usually resolve after stopping the infusion, although they may persist and require pharmacologic therapy.³⁷ If sustained ventricular tachycardia occurs, this is most likely due to ischemia.

Stress testing with vasodilators (dipyridamole or adenosine) may be performed for assessment of ischemia, myocardial perfusion, and myocardial viability.³⁸ These agents are contraindicated in patients with reactive airway obstruction or severe hypotension. Dipyridamole is safely given up to 0.84 mg/kg over 6 to 10 minutes. Atropine administration or handgrip exercise at peak infusion increases test sensitivity. Adenosine, in concert with contrast

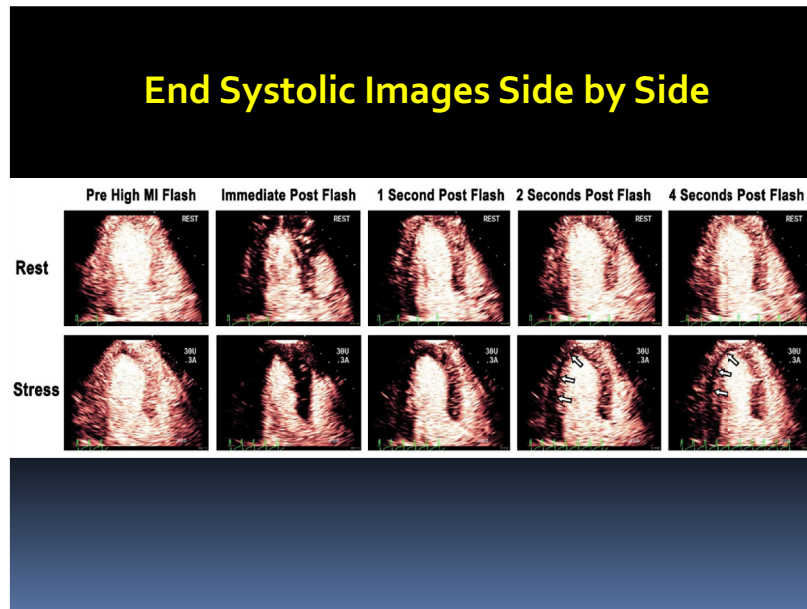


Figure 9 Demonstration of myocardial contrast replenishment following a high MI impulse during a continuous infusion of UEA during VLMI imaging. Images are acquired near end-systole. Under resting conditions (top panel), replenishment of myocardial contrast should occur within four seconds. Under stress conditions (bottom panel), replenishment should occur within two seconds. There is a delay in replenishment in the basal to mid inferolateral segments (arrows).

echocardiography, can also be used to assess myocardial perfusion. The adenosine infusion rate is 140 $\mu\text{g}/\text{kg}/\text{min}$ over 4 to 6 minutes to a maximum of 60 mg. Adenosine has a shorter half-life and thus, shorter action time than dipyridamole. DSE rather than vasodilator stress echocardiography is preferred by most because of higher sensitivity for detection of CAD unless perfusion can also be assessed.

Contraindications for all stress testing modalities include acute coronary syndromes, severe cardiac arrhythmias, malignant hypertension, significant left ventricular outflow tract (LVOT) obstruction, and symptomatic severe aortic stenosis.

Key Points

1. Exercise stress tests are more physiologic than pharmacologic stress tests and include the prognostically important finding of the patient's exercise capacity. Thus, if a patient can exercise, this is the preferred stress modality. (Class of recommendation I, level of evidence A)
2. Bicycle stress echocardiography (upright or supine) is technically more feasible for assessment of both coronary flow reserve and diastology.
3. DSE is a preferred alternative test for evaluation of myocardial ischemia when a patient cannot exercise.
4. Diagnostic endpoints include achievement of at least 80% of the age- and sex-predicted workload for exercise testing and target HR for DSE.

IV. IMAGE INTERPRETATION

a. Pathophysiology and Detection of Regional Wall Motion Abnormalities in Coronary Disease

Visual assessment of wall motion (wall thickening and inward endocardial excursion) remains the primary method of analysis of stress echocardiograms. Myocardial regions supplied by obstructed coro-

nary arteries are identified by a reduction in wall motion (hypokinesis) with stress relative to function at rest in the same region or relative to function with stress in regions with normal coronary blood supply. In the resting state, the inner half of the myocardium (subendocardium) contributes proportionately more to total systolic thickening and receives more blood flow than the outer half of the myocardium (subepicardium). Even in the absence of coronary obstruction, stress-induced tachycardia results in relative reduction of subendocardial blood flow compared to the subepicardium. In the presence of both coronary obstruction and tachycardia, subendocardial blood flow is further reduced, resulting in a corresponding reduction in wall thickening and endocardial excursion.^{39,40} In the presence of severe coronary obstruction, ischemia with biochemical abnormalities and more persistent wall motion abnormalities (myocardial stunning) may result, which improves detection of disease when post-stress imaging is employed.

Analysis of regional wall function must include assessment of wall thickening rather than just assessment of the extent of wall motion. Wall thickening should be preserved in basal inferior and basal septal segments that have decreased motion due to tethering to mitral-aortic fibrous structures as opposed to being caused by ischemia. Assessment of wall thickening may also aid in detection of smaller ischemic areas that are tethered to nonischemic myocardial regions, which become hyperkinetic with stress.

Work stations and software used for analysis of stress echocardiograms should provide various means of improving visual assessment of the extent of wall thickening and wall motion. A cursor can be used to mark the location of the endocardial border in diastole to provide a fixed reference point for assessment of systolic thickening and motion. Software that provides a mask or colorized end-diastolic image and depicts the extent of systolic endocardial excursion as an alternate color may assist in assessment of the extent of wall thickening and in identification of abnormalities due to excessive cardiac translational motion rather than ischemia (Video 9, available online at www.onlinejase.com).

Table 3 Normal and ischemic responses for the various stress modalities

Stress method	Normal response	Ischemic response	Normal response	Ischemic response
	Regional	Regional	Global	Global
Treadmill	Hyperkinesis post-exercise compared to rest	Hypokinesis compared to rest	Increase in EDV Decrease in ESV Increase in EF	Increase in EDV Increase in ESV Decrease in EF in left main, multivessel disease
Supine Bicycle	Hyperkinesis with exercise but less than with treadmill, dobutamine	Hypokinesis compared to rest	Small increase in EDV Decrease in ESV Modest increase in EF	Increase in EDV Increase in ESV Decrease in EF in left main, multivessel disease
Dobutamine	Marked hyperkinesis Increased velocity of contraction compared to rest and low dose	Hypokinesis and decreased velocity of contraction compared to low dose, and usually compared to rest	Decrease in EDV Marked decrease in ESV Marked increase in EF	Decrease in EF, cavity dilatation are infrequent with left main, multivessel disease
Vasodilator	Hyperkinesis with stress compared to rest	Hypokinesis compared to rest	Decrease in EDV Decrease in ESV Increase in EF	Decrease in EF, cavity dilatation are infrequent with left main, multivessel disease
Atrial Pacing	Mild hyperkinesis or no change in function compared to rest	Hypokinesis compared to rest	Decrease in EDV Decrease in ESV No change in EF	Decrease in EDV No change or increase in ESV Decrease in EF with left main, multivessel disease

In addition to decreasing the amplitude of contraction, ischemia delays the onset of contraction (tardokinesis), decreases the velocity of contraction, and results in post-systolic contraction. These abnormalities are more easily detected using quantitative techniques, but they may also be detected by visual assessment using digital technology. Delay in the onset of contraction and relaxation of ischemic segments may range from less than 50 to more than 100 milliseconds.⁴¹ The increased frame rates provided by current ultrasound systems have the necessary temporal resolution to permit visual recognition of delayed contraction by the trained observer (Video 10, available online at www.onlinejase.com).^{42,43} Visual assessment of the timing of contraction has been shown to improve sensitivity and interobserver agreement.⁴⁴

Software used for analysis of stress echocardiograms should enable the interpreter to compare the timing of segmental contraction on a frame-by-frame basis between rest and stress views and allow the interpreter to limit review to early systole to detect delays in onset of contraction.^{45,46} Although review of systolic frames is essential, complete cardiac cycles both at rest and stress should always be acquired and reviewed. Differentiation of tardokinesis and post-systolic shortening from other conditions that cause dyssynchrony of wall motion, such as early relaxation of the septum (Video 11, available online at www.onlinejase.com), left bundle branch block (LBBB), and right ventricular pacing, may require review of the full cardiac cycle.

b. Grading of Regional Function

For assessment of regional myocardial function, either the 16- or 17-segment model of the LV may be used.⁴⁷ (Figure 8) In clinical practice in which regional wall motion (RWM) and thickening are assessed,

the 16-segment model is commonly used. The 17-segment model, which includes the apical cap, an area beyond the LV cavity, is recommended if myocardial perfusion is evaluated or if echocardiography is compared with another imaging modality.⁴⁷

To assess wall motion, each segment should be analyzed individually and ideally, in multiple views. The function of each segment is graded at rest and with stress according to a five-point scoring system. Scores are as follows: normal or hyperkinesis = 1 (systolic increase in thickness >50%), hypokinesis = 2 (<40%), severe hypokinesis or akinesis = 3 (<10%), dyskinesis (paradoxical systolic motion away from the center of the LV) = 4, and aneurysmal (diastolic deformation) = 5, as previously recommended¹ (Figure 9). Although recent guidelines did not recommend the separate classification according to the presence of aneurysm,⁴⁸ its presence should be noted when evident, because of prognostic and therapeutic implications.⁴⁹ The wall motion score index (WMSI) should be derived by dividing the sum of the scores of individual segments by the number of segments visualized. Assessment of regional function at rest should make note of segments that have substantially decreased diastolic wall thickness (<70% of the thickness in normal segments or absolute thickness ≤6 mm), which is indicative of transmural infarction and scar.⁵⁰

c. Assessment During Stress and in Recovery

Dobutamine, bicycle, pacing, and vasodilator stress modalities enable imaging to be performed during both early and late stages of stress, which can improve assessment of the severity of coronary disease and enhance test sensitivity. The development of wall motion abnormalities during early stages of stress indicates the presence of severe coronary obstruction with little or no myocardial perfusion reserve.⁵¹ The

Table 4 Recommendations for reporting results of stress echocardiogram

- Baseline regional wall motion assessment
 - Number, location and severity of regional (or global) wall motion abnormalities
 - Presence of wall thinning or increased thickness
 - Assessment of ejection fraction
- Stress regional wall motion assessment
 - Number, location and severity of regional (or global) wall motion abnormalities
 - Estimate of ejection fraction response to stress
 - Estimate of end-systolic size response to stress
 - Stress response may include various stages of stress, especially if resting wall motion abnormalities are present
 - Adequacy of imaging
 - Use of UEA, including agent administered and dose
- Type of stress testing protocol
 - Doses of agent(s) for pharmacologic stress
 - Adequacy of stress
- Workload for exercise stress, and the adequacy of this workload according to norms for the patient's age and sex
- Whether target heart rate was achieved for dobutamine stress testing
- If the ischemia was not detected but stress was inadequate, a statement that this could affect the sensitivity for detection of ischemia should be included
 - Heart rate and blood pressure at each stage
 - ECG findings, including presence or absence of ischemia, and any arrhythmia
 - Cardiac symptoms
- Diagram or graphic display of wall motion at rest and with stress is recommended
- Additional findings noted on the resting images should be described if the patient has not already had a transthoracic echocardiogram.
- In patients referred for evaluation of the exertional dyspnea, additional information such as assessment of E/e', right ventricular systolic pressure, and/or oxygen saturation (by pulse oximeter) at rest and with stress may be beneficial
- Overall interpretation
 - Normal, ischemia, fixed wall motion abnormality, or combination

comparison of images obtained at low vs. peak stress has diagnostic value for detection of intermediate grades of coronary obstruction using dobutamine or bicycle stress.^{52,53} In the presence of moderate coronary obstruction with some preservation of perfusion reserve, an increase in myocardial thickening and wall motion is seen with a low level of exercise or a low dose of dobutamine, corresponding to an increase in blood flow. At high levels of stress, the combination of tachycardia and coronary obstruction results in a marked decline of subendocardial flow, with a corresponding decrease in regional function. Identification of this biphasic wall motion response, manifested by improvement of myocardial function at a low level of stress and subsequent worsening of function at a high level of stress can improve the sensitivity of stress echocardiography (Video 12, available online at www.onlinejase.com). Assessment for a biphasic response during dobutamine or bicycle stress should be performed for optimal detection of viability and ischemia. (Class of recommendation I, level of evidence B.)

Continuous monitoring of wall motion during bicycle exercise or pharmacologic stress enables determination of the ischemic threshold, the heart rate at which wall motion abnormalities first occur. This information can be used to estimate the severity and extent of disease, and to risk stratify patients with known or suspected coronary disease. Wall motion abnormalities occurring at a low heart rate or rate-pressure product usually indicate the presence of severe stenosis or multivessel disease.

Images obtained in the recovery period after cessation of stress may provide additional useful information. The persistence of wall motion abnormalities in the recovery period may be due to stunning and is an indicator of more severe ischemia.^{54,55} With DSE, ischemic wall motion abnormalities may initially be seen in the recovery period when function appears normal at peak stress. An example of a post-stress

wall motion abnormality is shown in Video 13 (available online at www.onlinejase.com). For this reason, an additional round of early post-stress imaging is recommended in patients who have no obvious wall motion abnormalities during dobutamine stress. Late recovery imaging should be considered in those with severe, extensive stress-induced wall motion abnormalities to assess for resolution of these abnormalities. It is an advantage of the modality of stress echocardiography that such signs of ischemia can be monitored during recovery, not feasible with nuclear perfusion imaging.

d. Assessment of Right Ventricular Function

Investigations focusing on the value of right ventricular (RV) function assessment with stress for detection of coronary disease have primarily utilized the apical 4-chamber view. Dedicated RV views, with the transducer located more medially may be required. The dedicated RV view demonstrates the RV lateral wall, which is primarily supplied by the marginal branches of the right coronary artery.⁵⁶ Assessment of RV lateral wall motion toward the interventricular septum and measurement of tricuspid annular plane systolic excursion (TAPSE) with M-mode echocardiography or peak systolic velocity of the tricuspid annulus (using tissue Doppler imaging) in the apical 4-chamber view can be useful for detection of right CAD.^{57,58} A decline in tricuspid annular motion of >4 mm with exercise has reasonable sensitivity for proximal right coronary artery obstruction (Video 14, available online at www.onlinejase.com). A decline in annular motion with dobutamine stress can be an indicator of RV ischemia but marked declines in RV preload and afterload induced by dobutamine may also result in little or no increase in annular motion from baseline.⁵⁷⁻⁵⁹ RV dilatation and reduction in global RV systolic function with stress is uncommon, but can occur with extensive, multivessel ischemia or with exercise-induced pulmonary hypertension.

Table 5 Specific technical considerations for optimizing myocardial contrast replenishment analysis

Typical location of artifact	Artifact/Problem	Sonographer correction method	Key additional points
Apex - myocardium	Reduced contrast	Increase near field TGC under resting conditions.	If resting wall motion is normal, perfusion should be normal, so a defect in this setting is an artifact.
Basal segment -myocardium	Reduced myocardial contrast	Foreshorten apical windows to get basal segments in the near field.	If resting wall motion is normal, perfusion is normal and therefore there should be no resting contrast defects in the absence of wall motion abnormalities. Foreshortened windows can be used in any apical window to better visualize basal segment perfusion.
Reduced myocardial contrast globally	Inadequate continuous infusion or bolus injection	Check IV site to ensure not obstructed; increase infusion rate; ensure contrast is not too dilute and is staying adequately mixed.	Could switch to a small bolus if using a continuous infusion.
LV cavity contrast	Shadowing of basal/mid segments	Slow down infusion or reduce bolus size and flush rate. Slightly increase for field time gain compensation.	Infusion (compared to bolus) reduces shadowing problems and allows for more rapid correction of the problem
Rib shadows in apical 2-chamber view	Cannot visualize basal and mid segment of anterior wall	Have one side by side loop for the inferior wall, and a second side by side loop examining a foreshortened anterior focused view.	Could also use parasternal short-axis window to examine anterior segments.

Key Point

1. The RV free wall should be included in apical 4-chamber images for assessment of lateral wall and tricuspid annular motion when right CAD is suspected. Right ventricular lateral wall and tricuspid annular motion should be assessed for detection of RV ischemia. (Level of evidence I, class of recommendation B)

e. Modality-specific Differences in the Regional and Global Left Ventricular Response to Stress

In addition to the evaluation of segmental LV function, the global LV response to stress should be assessed. Stress-induced changes in LV shape, cavity size, and global contractility can indicate the presence or absence of ischemia.^{60,61} The modality-specific differences in regional and global LV response to stress need to be considered when assessing for ischemia. Table 3 lists different modalities of stress and the general responses of regional and global function that are seen in normal subjects and in those with obstructive CAD.⁶¹⁻⁷⁴ A normal stress echocardiogram is defined by the presence of normal global and regional wall motion both at rest and with stress. The normal response to dobutamine stress is a marked increase in regional and global contractility (hyperkinesis) and a prominent decrease in LV cavity size due to reduced preload and afterload. The decrease in LV cavity size during DSE may be observed even when significant ischemic wall motion abnormalities develop.⁶¹ In normal subjects, treadmill exercise typically results in reductions in end-systolic cavity dimension but generally produces lesser increases in contractility compared to dobutamine. Compared to dobutamine and treadmill exercise, the normal response to bicycle stress is a lesser increase in contractility

and a less prominent decrease in cavity size due to both higher preload and afterload relative to the two other forms of stress. The absence of hyperkinesis, particularly with treadmill, dobutamine, and vasodilator stress, can indicate the presence of coronary artery obstruction but lack of hyperkinesis is not always specific for obstructive disease. Lack of hyperkinesis may also be due to microvascular disease, a hypertensive response to exercise, or may reflect an underlying cardiomyopathy. An ischemic response is defined by development of a new wall motion abnormality with stress in a segment with normal wall motion at rest or worsening of function with stress in a segment with a resting wall motion abnormality.

A severe resting wall motion abnormality with no change with stress (including no biphasic response) is considered a fixed wall motion response and represents a transmurally infarcted region or one with a limited epicardial rim of viability. In the presence of left main coronary artery or multivessel obstruction, a stress-induced decrease in ejection fraction (EF) or increase in end-systolic cavity size are more commonly seen with exercise than with dobutamine or vasodilator stress (Video 15, available online at www.onlinejase.com).⁶¹ It should be noted that akinesis becoming dyskinesis is generally considered to represent a mechanical response of an infarcted segment rather than ischemia.^{75,76}

f. Reporting

Recommendations for reporting are shown in Table 4. The number, location, and severity of wall motion abnormalities should be diagrammed at rest and with stress. When resting wall motion abnormalities are present, the response not only to peak stress, but to an intermediate stage, should be included for a bicycle or pharmacologic

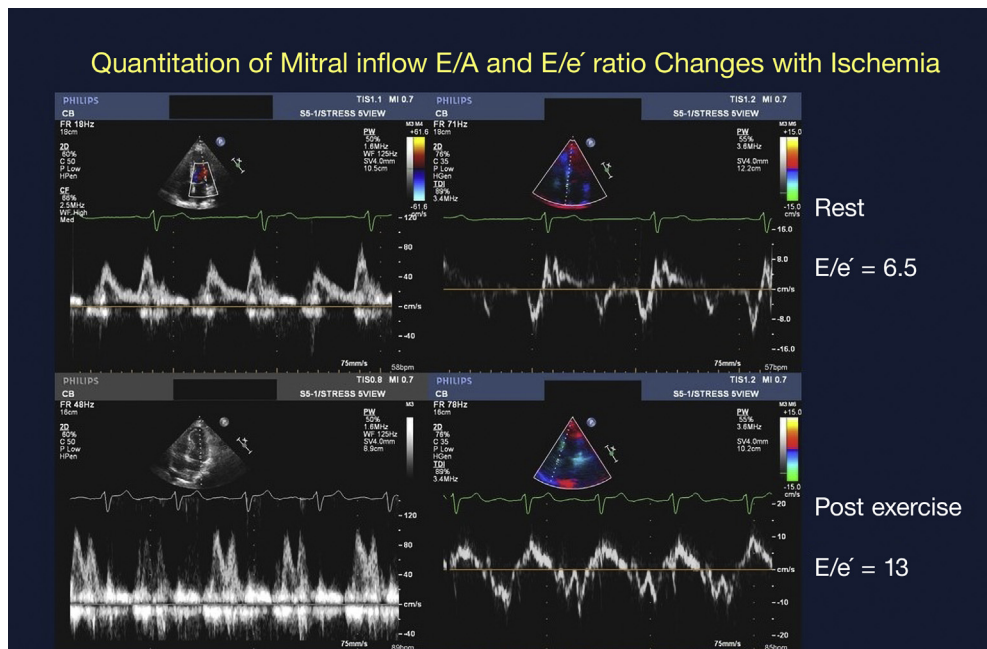


Figure 10 Quantitation of mitral inflow E/A and E/e' ratio changes with ischemia. Top panel shows mitral inflow Doppler and septal annulus tissue Doppler recordings at rest with E velocity < A velocity, and E/e' ratio of 6.5. Bottom panel shows recordings post-exercise with E velocity > A velocity, and E/e' ratio of 13.

stress study in which imaging is performed during stress. Interpretation must summarize the extent, severity, and location of abnormalities, and correlation with coronary anatomy. High-risk findings, including stress-induced wall motion abnormalities in more than one coronary artery distribution, and cavity dilatation should also be noted. The physician interpreter may choose not to grade equivocal resting or stress-induced wall motion abnormalities on the wall motion scoring diagram in lieu of a statement noting the equivocal nature of these abnormalities and possible non-ischemic causes. These abnormalities may include lack of hyperkinesis or decrease in end-systolic cavity size in the setting of a hypertensive response to stress, abnormal basal inferolateral wall motion in a patient with mitral prolapse, dyssynchronous septal motion with RV pacing or LBBB, systolic anterior motion of the interventricular septum after open-heart surgery, and pseudodyskinesis of the inferolateral wall in a patient with diaphragmatic elevation.

The report should also include the protocol used, the exercise time or peak dose of the pharmacologic agent, the maximum HR achieved, the BP response, the maximum HR-systolic BP product, the exercise capacity, and whether the level of stress was adequate. The reasons for test termination, cardiac symptoms, side effects if a pharmacologic agent was used, and the results of the stress electrocardiogram (ECG), including the presence of any arrhythmias, should also be noted.

If the patient has not had a resting transthoracic echocardiogram, findings of the baseline screening echocardiogram, including the presence of increased LV wall thickness, valvular abnormalities, or pericardial effusion, as well as the appearance of the proximal aorta should be described. If the patient has had a prior stress echocardiogram, this study should be reviewed and a comparative statement should be included in the report.

g. Perfusion Imaging Assessment with Ultrasound Enhancing Agent

Although single-photon emission computed tomography (SPECT) is still considered by the majority of cardiologists as the diagnostic tool

of choice to assess myocardial perfusion during stress testing, both radionuclide SPECT and PET are limited by reduced spatial resolution, high costs, and significant radiation exposure to the patient and allied health professionals working with the patient.⁷⁷⁻⁷⁹ The radiation exposure to the patient often exceeds 10 millisieverts (mSv), and repeated studies over time have led to cumulative exposures exceeding 100 mSv.⁷⁹ The nine million radionuclide SPECT myocardial perfusion imaging studies performed annually have been estimated to contribute to over 7,400 cancer cases annually in the US.⁷⁸ SPECT is also limited by attenuation artifacts, which can hamper interpretation in both the anterior (breast attenuation) and inferior (diaphragmatic attenuation) walls.⁷⁷ Importantly, especially during vasodilator stress, radionuclide tracers primarily detect myocardial blood volume changes, which are less sensitive than myocardial blood flow changes in detecting physiologically relevant coronary stenoses.⁸⁰

With real-time myocardial contrast echocardiography (RTMCE) using UEAs, real-time VLMI pulse sequence schemes using amplitude modulation (with or without phase modulation) have been developed that enhance the non-linear response from microbubbles at an MI < 0.2 while simultaneously canceling linear responses from myocardium and tissue.^{81,82} Thus, the imaging modality as well as the dose of UEA are not different from those required for enhancing LVO. Pulse sequence schemes for assessing myocardial perfusion reduce microbubble destruction, reduce far-field attenuation when using fundamental non-linear imaging, and increase the signal enhancement from microbubbles, allowing the simultaneous assessment of myocardial perfusion and wall motion during stress echocardiography.⁸² From a physiologic perspective, RTMCE has the ability to monitor myocardial blood flow changes during all types of stress imaging, as opposed to blood volume changes that are detected with cardiac magnetic resonance (CMR) or SPECT vasodilator stress imaging.⁸⁰ Because of this, stress perfusion imaging with RTMCE has the potential to improve the detection of a physiologically relevant coronary

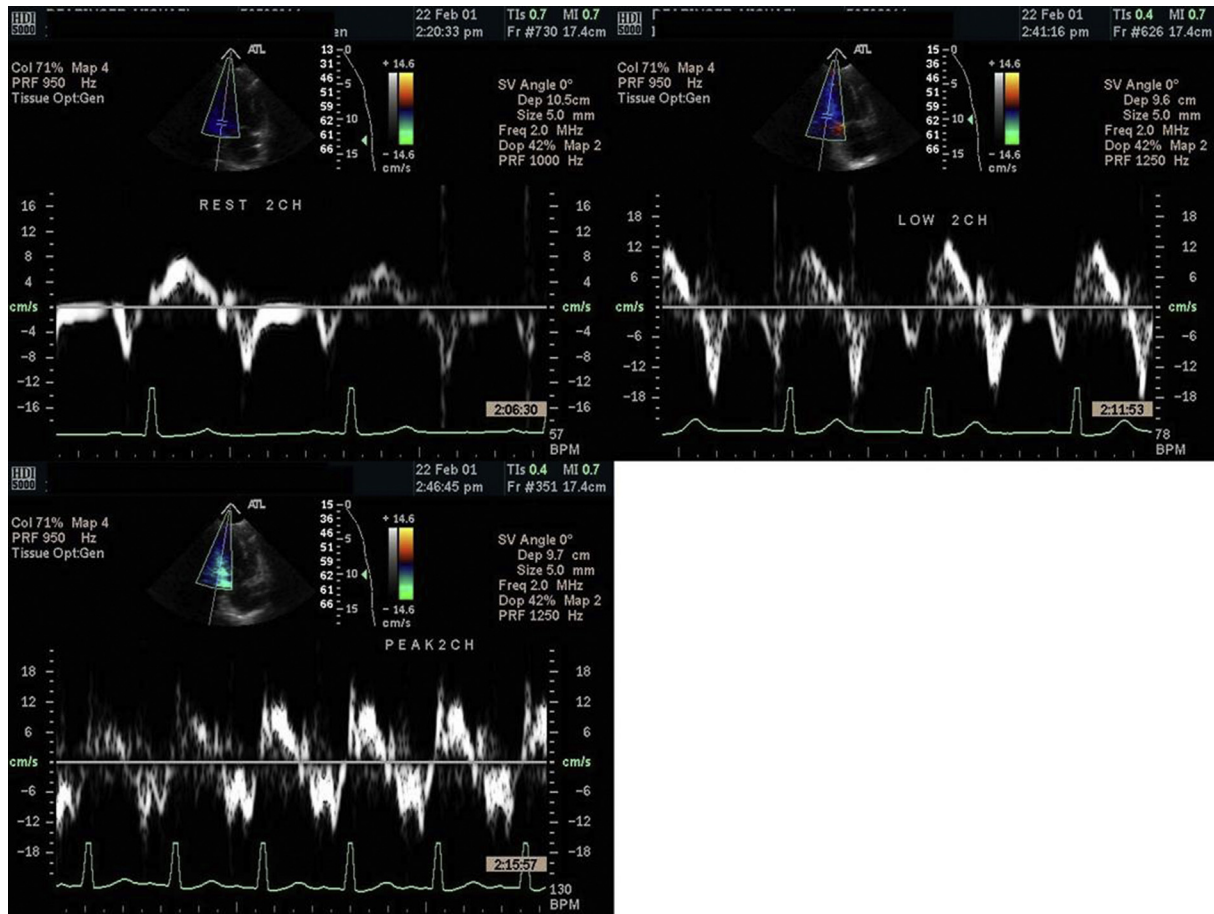


Figure 11 TDI of inferior ischemia. Rest: upper left; low dose: upper right; and peak dose: lower left. Spectral Doppler recordings of basal inferior tissue velocities with dobutamine stress in a patient with right CAD. There is a biphasic response in both systolic and early diastolic velocities. Rest: ($s' = 8$ cm/s, $e' = 10$ cm/s); Low: ($s' = 14$ cm/s, $e' = 18$ cm/s); Peak: ($s' = 11.5$, $e' = 13$ cm/s).

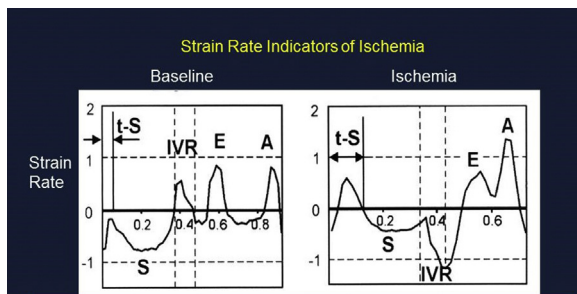


Figure 12 Strain rate indicators of ischemia adapted from Pislaru C, *et al*⁹⁹ Ischemia results in a (1) longer time to onset of systolic shortening, (t-S) known as tardokinesis; (2) reduced systolic strain and strain rate(s); and (3) post-systolic shortening [further shortening during isovolumic relaxation (IVR)]. E is reduced with reduced relaxation in ischemia. Adapted from Pislaru C, Abraham TP, Belohlavek M. Strain and strain rate echocardiography. *Curr Opin Cardiol* 2002;17:443-54, with permission from Wolters Kluwer Health, Inc.

stenosis, leading to a better assessment of risk when compared to SPECT imaging or conventional wall motion analysis (Figure 9, Videos 16 and 17, available online at www.onlinejase.com).⁸³⁻⁸⁷

The key component of myocardial perfusion imaging analysis with real-time myocardial contrast perfusion imaging is being able to analyze replenishment in all segments. This is dependent upon several

technical factors, as well as an understanding of the relationship between perfusion and function at rest and during stress (Table 5). Obtaining adequate resting perfusion images is vital, and it is recommended that a continuous infusion of contrast be utilized. A key physiologic premise is that if resting myocardial wall thickening is normal, perfusion is normal. Therefore, any technical factor must be corrected (e.g., apical near field gain, basal segment attenuation) prior to stress testing. If not corrected, the same defect will reappear during stress imaging, and one will not know if the defect is an artifact or a true perfusion defect. Unlike resting conditions, a perfusion defect can occur in the absence of a wall motion abnormality during any form of stress testing (Videos 18-22, available online at www.onlinejase.com). Despite its tremendous proven potential, perfusion imaging with RTMCE is not an FDA approved technique. As a result, in the U.S., RTMCE has been utilized routinely only at a small number of experienced centers.

V. QUANTITATIVE ANALYSIS METHODS

The development of reproducible, accurate, and easy to use quantitative analysis techniques that can be routinely applied in stress echocardiography has been a major focus of investigation.¹ The requirement for expertise and the subjectivity of visual assessment of LV wall motion initially provided the impetus for investigation of

Table 6 Quantitation: Doppler strain and strain rate imaging advantages and limitations

Advantages	Limitations
Can be acquired with lower-quality 2D images High frame rates (≥ 100 fps)	Angle dependent Need to adjust placement of sample volumes manually with translational motion with stress
Quantify timing and magnitude of contraction, relaxation	Reduced signal quality with stress and lateral wall signal quality (due to decreased resolution)
Strain and strain rate assess regional myocardial function (versus TDI)	Higher than optimal interobserver variability (10-20%) ^{104,105}
Strain rate reflects velocity of contraction, which may be ideal parameter for use with dobutamine	Data mostly limited to pharmacologic stress
	Optimal parameter for detection of ischemia has not been defined
	Generally limited to assessment of longitudinal function in the apical views
	Non-automated, time and labor-intensive analysis to quantify parameters in multiple segments

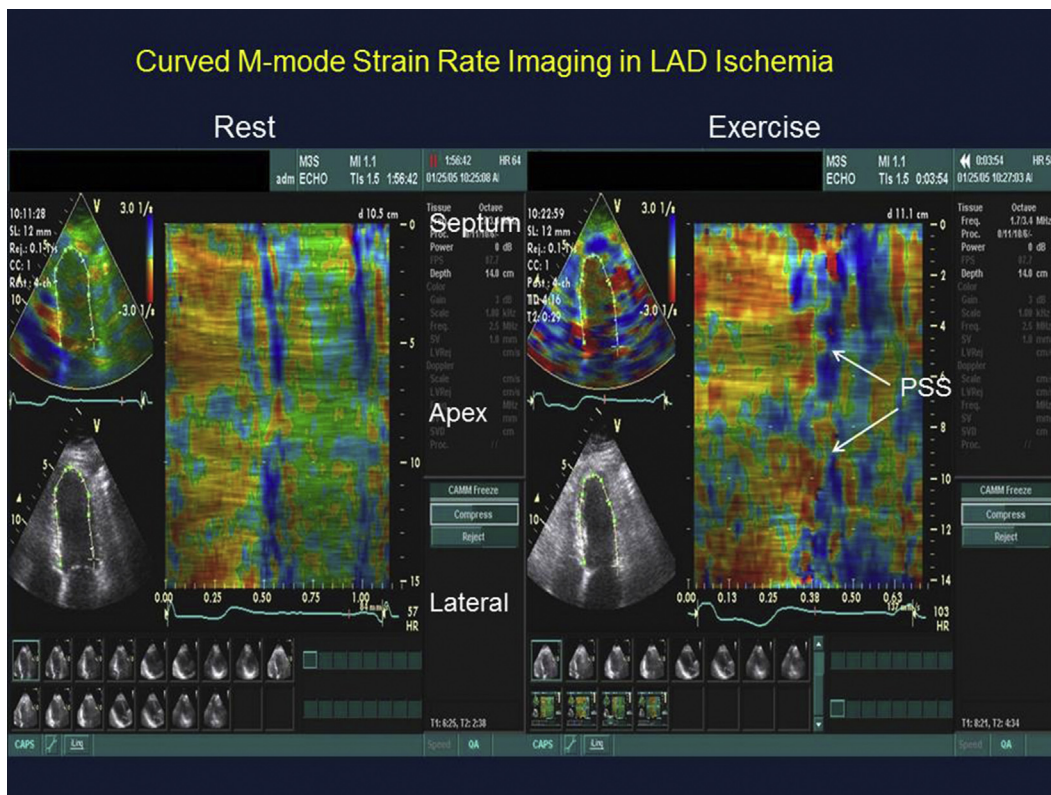


Figure 13 Curved M-mode strain rate Imaging in LAD Ischemia. Color-coded curved M-mode images display Doppler strain rate during the cardiac cycle on the horizontal axis and segment location for each view vertically (top to bottom) with the apex at midline of the vertical axis. Increasing rates of shortening are depicted in yellow to brown to red hues from rest to stress, and increasing rates of lengthening in diastole are depicted in increasing intensities of blue. Absence of contraction or relaxation is depicted in green. At rest, systolic strain rate is relatively homogeneous (brown to light red in all segments except for the apex). Strain rate is artifactually low at the apex because of the angle of interrogation. With exercise, the basal septal and lateral segments become hyperdynamic (red hue) during systole while the mid-apical septal and lateral segments demonstrate delayed onset of contraction and reduced strain rate during systole with prominent post-systolic shortening (PSS).

quantitative methods. Additionally, quantitative analysis may increase the sensitivity of detection of coronary disease. Measurement of LV volumes and ejection fraction is not routinely employed in most stress laboratories because of time constraints and challenges in reproducibility with stress when images are technically difficult. However, in selected cases, measurement of ejection fraction and end-systolic vol-

ume may provide confirmatory evidence of an abnormal global response to stress.

Rest to early post-exercise change in mitral E velocity has been shown to be useful for detection of CAD.^{88,89} An increase in E velocity due to increased LV filling pressure may occur in those with extensive ischemia, and the development of impaired LV relaxation resulting in a decrease in

Table 7 Quantitation by 2D speckle-tracking: Advantages and challenges for clinical application

Advantages	Challenges for clinical application
Relatively non-angle dependent (compared with DSI)	Lower frame rates compared with DSI (40-100/sec) may result in underestimation of strain, strain rate at high heart rates
Better signal-to-noise ratio (compared to DSI)	Dependent on 2D image quality, lower feasibility than visual analysis
Can assess longitudinal, circumferential, radial strain	Out-of-plane motion
Rapid, semi-automated analysis	Current studies primarily limited to dobutamine stress (Uncertain feasibility with exercise stress)
Ease of analysis of global and regional peak systolic strain in polar map format	Optimal parameter for detection of ischemia not defined
	Variability among vendors and different generations of software (Global strain values with current generation software shown to be reproducible)
	Uncertain accuracy and reproducibility of regional strain, especially in the posterior circulation
	Load dependence of strain
	Uncertain if speckle-tracking can be used with contrast

DSI, Doppler strain imaging.

Table 8 Requirements and challenges to application of speckle-tracking echocardiography with stress

Requirement for reasonable quality 2D images
Feasibility of STE needs to be tested with exercise stress
Feasibility needs to be tested with UEA
Adequate training of sonographers and physicians
Optimize imaging for strain assessment – depth, sector width selection
Knowledge of causes of poor tracking
Manual adjustment of regions of interest
Adequate frame rates (minimum of 30 frames/cardiac cycle) to enable tracking at high heart rates
Additional studies to define normal response to dobutamine and exercise stress
Additional studies to identify best parameter for CAD detection
Strain rate – potentially optimal parameter when combined with dobutamine stress; frame rate limitations relative to Doppler strain imaging
Strain – account for loading conditions
Post-systolic shortening – ? optimal threshold value for detection of disease; would need automation of measurement to be applicable
Other timing parameters – ? optimal parameter for detection of disease; need high frame rates, would need automation of measurement to be applicable
Additional studies to assess intervender reproducibility of regional strain, strain rate values

E velocity may be seen with less extensive ischemia. Assessment of diastolic function with stress may be beneficial in the evaluation of patients with unexplained dyspnea using the combination of Doppler measurement of mitral E velocity and tissue Doppler measurement of mitral annulus e' velocities in the apical 4-chamber view during bicycle exercise or after treadmill exercise. These variables are usually measured at a heart rate of 100-110 beats per minute during exercise or in recovery to avoid fusion of E and A waves. An increase in E/ e' ratio to >14 for the average E/ e' or >15 for septal E/ e' with exercise correlates with an increase in LV filling pressure, which can be due to stress-induced ischemia or inadequate rate of relaxation in subjects with diastolic dysfunction from myocardial disorders^{23,90} (Figure 10). Septal e' is most commonly measured, but lateral e' is preferred in some patients such as those with localized medial mitral annulus calcification or septal wall motion abnormalities. Assessment of changes in mitral E/A and E/ e' ratios with exercise is a useful supplement to wall motion analysis for detection of ischemia and increases in LV filling pressure.

Acoustic quantification (AQ) utilizes integrated backscatter detection of the blood-tissue interface for endocardial border tracking throughout the cardiac cycle. The color kinesis (CK) method was

developed from AQ to enable automated, quantitative assessment of regional function at rest and with stress. Each frame of endocardial excursion in systole is encoded with a different color, resulting in a series of different colored bands with the thickness of each representing the extent of endocardial excursion that occurred during that time interval. CK has not been widely applied because of the requirement for proprietary software, labor intensive quantitation, and necessity for high-quality images.^{91,92}

The high sampling rates (≥ 100 frames/sec) afforded by Doppler echocardiography enable assessment of both the timing and magnitude of contraction and relaxation. Both pulsed-wave (PW) and color Doppler techniques of tissue Doppler imaging (TDI) of myocardial segments have been investigated during dobutamine stress. Limitations include the need to individually sample each myocardial segment, requirement for segment-specific normal values because of the normal base to apex gradient in velocities, differences in normal velocities between the PW and color Doppler methods, and the need to minimize the angle between the direction of motion and Doppler interrogation. Abnormalities in the rest to stress changes in ejection velocity or isovolumic acceleration, maximal post-systolic velocity, and early diastolic

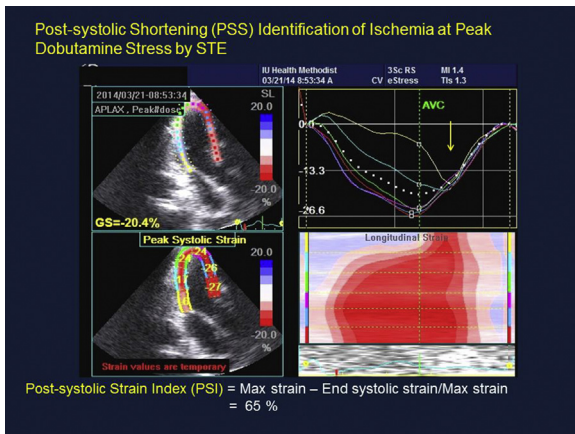


Figure 14 Post-systolic shortening identification of ischemia at peak dobutamine stress. Peak stress systolic strain values (left lower panel), segmental strain values during the cardiac cycle (upper right), and curved M-mode recording (lower right) from the patient with stress-induced inferolateral wall motion abnormality shown in [Video 23](#) (available online at www.onlinejase.com). The inferolateral segments show reduced peak systolic strain. The basal inferolateral segment shows marked post-systolic shortening (yellow arrows). Proximal right coronary artery stenosis was identified by coronary angiography.

velocity have been reported as markers of ischemia.⁹³⁻⁹⁶ Quantitation of systolic velocities with dobutamine stress has shown comparable accuracy with wall motion assessment.^{93,97,98} Assessment of tricuspid annular velocity with stress can be used to detect right CAD.⁵⁷ The time and labor intensive nature of data acquisition and analysis and requirement for segment-specific normal values has largely confined the use of TDI of myocardial segments to research settings. However, TDI can be a useful adjunct in selected cases ([Figure 11](#)).

The limitations of measuring myocardial velocities with TDI prompted investigation of the value of color Doppler assessment of myocardial deformation using strain and strain rate imaging. Measurement of strain (change in myocardial length divided by initial length) and strain rate (the change of strain over time) enables quantitative assessment of contraction and relaxation of individual myocardial segments. Assessment of strain and strain rate by color Doppler is usually performed in the apical views for assessment of longitudinal function. Longitudinally oriented fibers predominate in the subendocardium, which is the region where supply-demand mismatch is greatest during stress-induced ischemia. In contrast to tissue velocities, strain and strain rate are less susceptible to the effects of translational motion and tethering and unlike tissue velocities, regional strain and strain rate values reflect local myocardial function. Strain rate is less load sensitive than strain. Both strain and strain rate measures (as derived from Doppler methods) are dependent on insonation angle. Strain is expressed as % change in length with systolic shortening expressed as negative values. Strain rate is expressed in units of 1/s and is conventionally expressed as positive numbers.

The high temporal resolution of Doppler-derived strain and strain rate data permits assessment of ischemia-induced abnormalities in both the timing and magnitude of myocardial contraction and relaxation. Ischemia delays the onset of shortening, reduces the speed and magnitude of systolic shortening, results in post-systolic shortening during isovolumic relaxation, and decreases the speed and magnitude of early diastolic lengthening. ([Figure 12](#)).⁹⁹ [Supplemental Table 1](#) (available at www.onlinejase.com) summarizes the studies that have

investigated the feasibility and diagnostic value of Doppler strain imaging for detection of coronary disease. Ischemia-induced reductions in systolic strain rate, delay in the time to onset of relaxation, and indices assessing the magnitude of post-systolic shortening (PSS) have been found to be the most useful parameters for detection of disease.¹⁰⁰⁻¹⁰³ Doppler strain imaging has not consistently demonstrated incremental diagnostic value beyond visual assessment of wall motion. The advantages and limitations of Doppler strain imaging are shown in [Table 6](#).

Visual assessment of curved M-mode images utilizes the information provided by strain rate imaging without the requirement for time consuming, detailed analysis of strain rate plots. The M-mode technique has higher feasibility than quantitative Doppler strain imaging.^{102,106} The transition from systolic shortening to diastolic lengthening is well demarcated by an abrupt color change that enables quick visual assessment of regional delays in the cessation of contraction and onset of relaxation ([Figure 13](#)).¹⁰⁰ A limited number of studies have shown that visual assessment of curved M-mode images has supplemental diagnostic and prognostic value to visual assessment of wall motion.^{102,106,107} Curved M-mode images can be easily obtained following completion of the stress exam on images where two-dimensional (2D) and TDI information were simultaneously acquired. However, the process of deriving these images and arranging them for physician review takes several minutes. Visual assessment of cardiac motion should be used to distinguish artifact from true abnormalities in strain rate. The feasibility of imaging with exercise, the ease and speed with which images can be generated, and the limited time required for image review are advantages of curved M-mode strain rate imaging, but further validation is required.

Assessment of myocardial deformation using 2D speckle-tracking echocardiography (STE) is the most recently developed quantitative technique. The motion of speckle patterns unique to a region of myocardium is tracked frame by frame throughout the cardiac cycle, enabling quantitation of systolic shortening and diastolic lengthening. Semi-automated software that automatically defines regions of interest for each echocardiographic view enables assessment of strain in multiple segments simultaneously. The relative lack of angle dependency, improved signal-to-noise ratio, less time-intensive analysis, and feasibility of measurement of strain and strain rate in multiple dimensions are advantages of STE compared to Doppler strain imaging; however, frame rates with STE are lower (50 to 90 frames/sec) than rates achievable with Doppler strain imaging (≥ 100 /sec), potentially decreasing the accuracy of assessment of timing parameters and leading to underestimation of peak strain ([Table 7](#)). The majority of clinical studies have focused on assessment of longitudinal strain utilizing apical views. Ischemia has been shown to affect longitudinal strain earlier than radial strain.¹⁰⁸ Peak systolic strain values at rest and with stress can be displayed side by side in polar map format for rapid assessment of changes in strain. Studies have reported the feasibility and diagnostic value of STE with pharmacologic stress ([Supplemental Table 2](#); available at www.onlinejase.com). Global peak longitudinal systolic strain is the quantitative parameter most often investigated. In most studies, ischemia was identified by significant declines in global strain from low to peak dose. However, decreases in strain from rest to low dose have been shown in normal subjects, presumably due to reduction in diastolic volume with high dose dobutamine and inadequate frame rates in the setting of tachycardia.^{109,110} Studies have compared the value of multiple strain parameters for detection of CAD.^{104,111-114} The optimal STE parameter for detection of ischemia remains uncertain. In general,

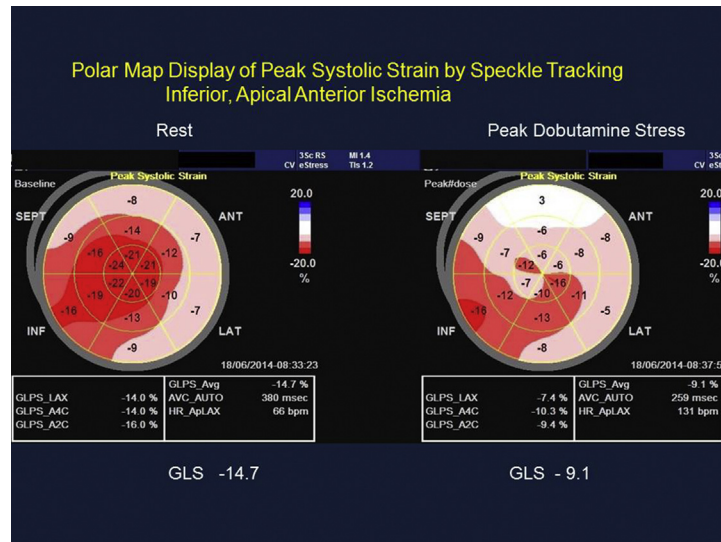


Figure 15 Polar maps of rest (left) and stress (right) peak systolic strain in the same patient (Videos 24 and 25, available online at www.onlinejase.com) with 2D echocardiographic evidence of extensive ischemia. There is a marked decrease in global strain from rest to peak stress (−14.7 to −9.1%) with reduction in regional strain in the anteroseptal, inferoapical, apical, anterior, and anterolateral segments and no change in strain with dobutamine in the inferolateral segments. This patient had multivessel CAD.

STE has not shown an incremental increase in accuracy compared to visual assessment.¹¹³⁻¹¹⁶ The requirements for and challenges to the clinical application of STE to stress echocardiography are listed in Table 8.¹⁰⁹ The reproducibility of regional strain values has not been well validated and inter-vendor differences in measurement are the subject of ongoing investigation. Figures 14 and 15, and Videos 23-25 (available online at www.onlinejase.com) illustrate detection of CAD using STE. Blood pressure changes during stress should be considered when interpreting strain responses because loading conditions may influence strain values.^{117,118}

VI. ACCURACY

Multiple studies have demonstrated the excellent accuracy of stress echocardiography using coronary arteriography as the gold standard for comparison. Stress testing with imaging has a greater accuracy than the exercise electrocardiogram. The prior version of the ASE stress echocardiography guideline document reported an average sensitivity of 88% and average specificity of 83% for stress echocardiography for detection of coronary artery stenosis.¹ Publications of original research studies from 2007-2017 identified by Pub Med search using the strategy: stress echocardiography and CAD, not prognosis, English language, are summarized in Supplemental Table 3 (available at www.onlinejase.com). As with all stress testing modalities, the sensitivity for detection of IHD is greater when multivessel rather than single vessel disease is present.

Several meta-analyses have compared the accuracy of nuclear perfusion imaging and stress echocardiography. These tests had similar sensitivities for detection of CAD but stress echocardiography had higher specificity.¹¹⁹ For the detection of left main or multivessel CAD, stress echocardiography had greater sensitivity compared with nuclear myocardial perfusion imaging, which compares relative differences in perfusion and may miss ischemia that is balanced or global.¹²⁰ Another meta-analysis revealed that dipyridamole and DSE had similar sensitivity and specificity for detection of CAD.¹²¹

Key Points

1. Multiple studies have demonstrated the excellent accuracy of stress echocardiography using coronary arteriography as the gold standard for comparison.
2. For detection of CAD, stress echocardiography has similar sensitivity to tomographic nuclear perfusion imaging. However, stress echocardiography has higher specificity. For detection of left main or multivessel CAD, stress echocardiography has greater sensitivity.

a. Blood Pressure Response to Stress

Abnormal blood pressure response to stress may lead to early discontinuation of the test. Cut points to define a hypertensive response during DSE have been defined as systolic blood pressure ≥ 182 mmHg and diastolic blood pressure ≥ 96 mmHg¹²² and for exercise as peak systolic blood pressure ≥ 220 mmHg.¹²³ It was previously suggested that patients with stress-induced hypertensive responses (ESE or DSE) were more likely to have abnormal stress echocardiogram results and these abnormalities were less specific for the diagnosis of significant CAD.¹²⁴ However, using the cut-points for hypertensive response defined above, patients with hypertensive responses to exercise were not more likely to have abnormal ESE findings than those with normal blood pressure. The majority of patients who have abnormal ESE results and undergo coronary angiography have obstructive CAD.¹²⁵ Patients with hypertensive responses during DSE were more likely to have stress-induced myocardial ischemia compared to those with normal BP response, but were not more likely to have false-positive DSE results.¹²⁶ However, severe CAD is less likely to be present in patients with a hypertensive response during DSE compared to those who have a normal blood pressure response. Hence, it should not be assumed that the development of wall motion abnormalities in the setting of a hypertensive BP response during stress is simply due to the hypertensive BP response itself, or that these positive stress findings signify a false-positive result. Such patients should be evaluated or managed like any patient who has positive stress findings.

Key Point

1. Patients who experience hypertensive responses to stress should be evaluated or managed like any patient who has positive stress findings.

b. Microvascular Disease

A variety of mechanisms have been suggested for the development of wall motion abnormalities in the absence of significant angiographic coronary stenosis including microvascular abnormalities, endothelial dysfunction, vasospasm, and small vessel CAD. Abnormal coronary flow reserve and abnormal stress test results have been associated with the presence of amyloidosis deposits in intramyocardial vessels.^{105,127} Strongly false-positive stress echocardiograms have frequently involved atypical and mid LV segments, features that are similar to echocardiographic findings of apical ballooning syndrome.¹²⁸ Invasive assessment of coronary vasomotor reactivity showed that coronary microvascular dysfunction is highly prevalent in patients with apical ballooning syndrome.¹²⁹ Hence, microvascular disease, endothelial dysfunction, small vessel CAD, vasospasm, amyloidosis, and apical ballooning syndrome should be considered in the differential diagnosis of false-positive stress echocardiograms.^{105,127,130} Importantly, a prognostic study demonstrated that outcomes of patients with false-positive stress results were similar to those with true-positive results.¹²⁵ Patients with false-positive results on stress echocardiography should receive intensive risk factor management and careful clinical follow-up.

Key Point

1. The outcomes of patients with false-positive stress results are similar to those with true-positive results. Patients with false-positive results on stress echocardiograms should receive intensive risk factor management and careful follow-up.

c. Impact of Perfusion Imaging

Perfusion imaging with myocardial contrast echocardiography has been performed in thousands of patients during DSE, treadmill exercise stress, or vasodilator stress echocardiography.^{7-10,12,13,77,81,82,84,86,87,131-161} In the setting of DSE or vasodilator stress echocardiography, perfusion analysis of end-systolic images has been shown to improve CAD detection when compared to wall motion analysis alone.⁹² The improvement appears to be related to the ischemic cascade, which has shown that perfusion abnormalities occur prior to wall motion abnormalities (Video 21, available online at www.onlinejase.com).^{81,162} The first multi-center studies comparing perfusion imaging with myocardial contrast echocardiography and radionuclide SPECT demonstrated a similar sensitivity and specificity between the two techniques in detecting angiographic CAD, regardless of stenosis severity.⁸⁵⁻⁸⁷ Since the initial studies, real-time VLMI imaging techniques have been developed that permit imaging at frame rates of 20 Hertz. The higher resolution of perfusion echocardiography has permitted improved detection of ischemia in patients with LBBB when compared to radionuclide SPECT imaging,¹³⁸ and thus may be useful in patient populations with resting non-ischemic wall motion abnormalities such as ventricular paced rhythms. Perfusion abnormalities during demand stress have also been correlated with fractional flow reserve measure-

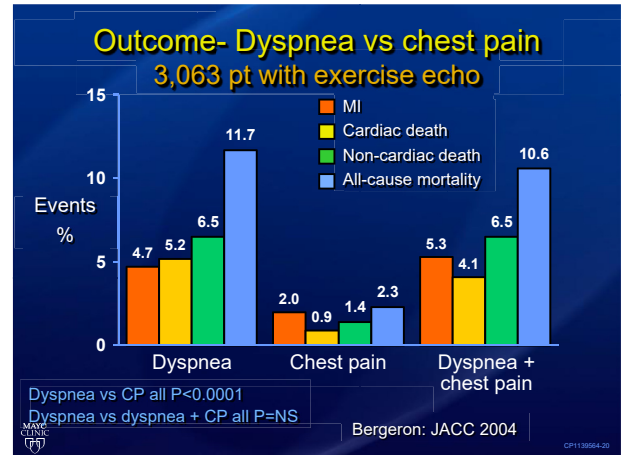


Figure 16 Outcome during follow up for patients undergoing ESE for evaluation of dyspnea alone, chest pain alone, and combined dyspnea and chest pain. Adapted from Bergeron et al.¹⁹⁰

ments using invasive hemodynamics. Here the correlations are not as good and reflect differences in what the two techniques are measuring. Fractional flow reserve (FFR) is determined by measuring a pressure gradient across a given stenosis in the catheterization laboratory and does not take into account the impact of capillary resistance changes in response to stress.^{159,160,163} Because RTMCE is measuring capillary blood velocity and blood volume, stress-induced abnormalities may develop prior to the development of an FFR abnormality when stenosis is in the 50-80% range.^{160,161}

Key Point

1. When properly performed, perfusion imaging with VLMI imaging (RTMCE) appears to improve detection of coronary artery stenoses during DSE or vasodilator stress imaging. If performing myocardial perfusion imaging, VLMI imaging should be used with real time high MI flash replenishment techniques for simultaneous perfusion and wall motion assessment (Level of Evidence IIa, Class of Recommendation B).

d. Coronary Flow Reserve

Assessment of coronary flow reserve by echocardiography uses coronary Doppler velocity assessment with pharmacologic stress.^{3,164} The Doppler velocity signal should be obtained in the mid-distal left anterior descending coronary artery (LAD) by transthoracic echocardiography using a high-frequency ultrasound probe; when performed by experienced operators the feasibility of LAD imaging is high.¹⁶⁵⁻¹⁶⁸ The posterior descending coronary artery and the left circumflex coronary artery have been imaged with lower success rates. Most studies have used vasodilator stress for assessment of coronary flow reserve. DSE has been used but it may be technically challenging to obtain LAD Doppler signals at fast heart rates.¹⁶⁹

e. Three-Dimensional Stress Echocardiography

Three-dimensional (3D) stress echocardiography has been performed with both exercise and pharmacologic stress with good feasibility and accuracy for the detection of angiographic CAD.^{170,171} Advantages of 3D imaging include rapid acquisition of a complete dataset at peak stress, optimal visualization of the LV apex, which

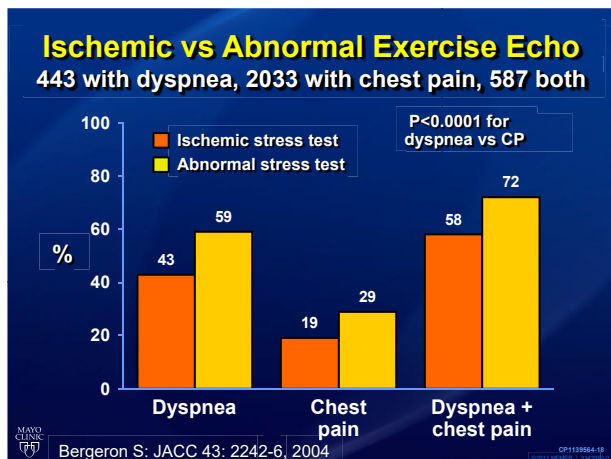


Figure 17 Ischemia by stress echocardiography, including the exercise-induced change in WMSI was independently predictive of cardiac events and mortality during follow up in patients referred for evaluation of chest pain or dyspnea. Adapted from Bergeron et al.¹⁹⁰

may be foreshortened with conventional apical views, and truly tomographic imaging of all segments. Challenges have been related to the lower frame rates and decreased spatial resolution. Optimal side-by-side display of rest and stress images has also been accomplished but is not widely available.¹⁷²

VII. RISK STRATIFICATION AND PROGNOSIS

Stress echocardiography is routinely used for the diagnosis of flow-limiting CAD in patients with anginal symptoms or equivalent. However, an equally important objective of non-invasive stress testing is to identify patients at risk for future cardiac events and to assess prognosis. The application of prognostic testing is based on the premise that patients identified as being at the highest risk of adverse events can be intervened upon to alter the natural history of their disease process, thereby improving prognosis. Risk stratification using stress echocardiography has been demonstrated in multiple studies. However, limited data using any modality have demonstrated that application of testing changes outcomes.¹⁷³

Numerous studies have demonstrated that a normal stress echocardiogram (normal regional wall motion at rest and with stress) is associated with a benign prognosis.¹⁷⁴⁻¹⁷⁷ The low event rate of 0.9%/year over the ensuing year approaches that of a normal age-matched population and also of patients with normal coronary angiograms. Furthermore, outcome after a normal stress echocardiogram compares favorably with that after normal myocardial SPECT imaging (thallium-201, technetium-99 or sestamibi) with all associated with a benign prognosis.¹⁷⁸ Exercise capacity¹⁷⁸⁻¹⁸⁰ and heart rate response¹⁸¹ can be used to further stratify risk in patients undergoing ESE.

Compared to a normal ESE, a normal DSE is associated with a slightly higher event rate.¹⁸² Compared to patients undergoing ESE, those undergoing DSE are generally older and have more comorbidities. Failure to achieve target heart rate during DSE is associated with a higher event rate in patients with a normal DSE.¹⁸²

Peak wall motion score index (WMSI) and EF have been identified on multivariate analysis as the best predictors of cardiac events. In a study of 1,500 patients undergoing stress echocardiography (34% treadmill, 66% dobutamine) with a follow-up of 2.7 ± 1 years,

non-fatal myocardial infarction and cardiac death occurred in 31 and 44 patients, respectively. A normal stress echocardiogram, with a WMSI of 1 during stress, conferred a benign prognosis (0.9%/year cardiac event rate), whereas intermediate WMSI (1.1-1.7) and high WMSI (≥ 1.7), as well as an ejection fraction of $\leq 45\%$ further stratified risk.¹⁷⁴ Peak stress WMSI effectively risk stratified patients into low- (0.9%/year), intermediate- (3.1%/year), and high-risk (5.2%/year) groups for cardiac events.¹⁷⁴

a. Extent and Severity of Wall Motion Abnormalities

When interpreting stress echocardiograms, both extent and severity of wall motion abnormalities should be evaluated. The ischemic extent and maximal severity are exponentially correlated with an increase in cardiovascular adverse events.^{174,183} The number of LV wall segments with new wall motion abnormalities is an indicator of the extent of ischemia, and maximal severity or magnitude of new wall motion abnormality is an index of severity of ischemia or degree of stenosis. Ischemic extent reflects the area of myocardium in jeopardy (number of segments demonstrating new wall motion abnormalities) whereas severity reflects the maximum magnitude of wall motion abnormalities. Both ischemic extent and magnitude should be evaluated with stress. The predicted event rate ranged from a low of 0.9%/year in patients without any wall motion abnormalities to as high as 6.7%/year in patients with extensive and severe wall motion abnormalities.¹⁸⁴ The extent and severity of wall motion abnormalities by stress echocardiography are both independent and cumulative predictors of prognosis.¹⁸⁵ These findings compare favorably with those using SPECT.¹⁸⁶ There is an exponential relationship between the extent and severity of stress-induced hypoperfusion event rate ($r = 0.97$ $P = .001$). Incorporating both ischemic extent and severity of wall motion abnormalities by stress echocardiography helps to accurately assess prognosis.¹⁸⁴

b. Transient Ischemic LV Dilatation

Using receiver-operator curves (ROC), the rest-to-stress LV volumes ratio of >1.7 was the best threshold for defining transient ischemic dilatation. However, this is often assessed visually by comparing rest and stress images side by side, without measurement.¹⁸³ Patients with an abnormal stress echocardiogram and transient ischemic dilatation had greater extent and severity of wall motion abnormalities, higher peak WMSI, higher percentage of multivessel disease, and greater adverse event rate (19.7%) compared to patients without dilatation with ischemia (2.9%/yr). It should be noted that a stress-induced increase in end-systolic size is more commonly observed with ESE rather than with DSE.⁶¹

c. RV Ischemia

Right ventricular function has significant prognostic implications in patients with CAD and heart failure.¹⁸⁷ With stress echocardiography, assessing RV abnormalities (ischemia or infarction) can further help risk stratify and add prognostic value to LV parameters. Peak RV WMSI provides incremental prognostic value over rest and conventional stress echocardiographic variables (global chi square increased from 141.4 to 161.8).¹⁸⁸ Thus, assessment of the RV using additional subcostal views should be considered in patients undergoing stress echocardiography for more accurate and effective risk stratification. Compared to the LV, the RV has lesser mass and lower systolic and end-diastolic pressures; therefore, unlike the LV, the RV receives

blood flow in both systole and diastole, creating more favorable coronary supply. However, despite this, given that both the RV and LV share a common septum, have overlapping blood supply, are enclosed by spiral muscle fibers, and are bound together by the pericardium, there is ventricular interdependence such that hemodynamic and functional changes of one chamber may affect the other.¹⁸⁹ The function and importance of the RV is now being increasingly recognized; as the peak RV WMSI increases, prognosis worsens. Patients with both abnormal RV and LV have worse outcomes.¹⁸⁸ When the RV WMSI is greater than 2 using a 3-segment model, the event rates were as high as 11.4%.¹⁸⁹

d. Stress Echocardiography in Patients with Dyspnea

Compared to patients presenting with chest pain alone, patients referred for ESE for evaluation of dyspnea have been shown to have a more than 2-fold higher incidence of myocardial infarction, cardiac death, non-cardiac death, and coronary revascularization¹⁹⁰ (Figure 16). Ischemia by ESE is more commonly present in patients with dyspnea than with chest pain (Figure 17). ESE provided independent prognostic information for identifying patients at risk of cardiac events and death.¹⁹⁰ Among dyspneic patients unable to exercise and referred for DSE, ejection fraction, resting wall motion abnormalities, abnormal left ventricular end-systolic volume response to stress, and failure to achieve target heart rate were independently associated with all-cause mortality.¹⁹¹

Compared with other modalities of stress testing and noninvasive cardiac imaging, stress echocardiography offers the advantage that other potential cardiac etiologies of dyspnea can also be assessed at the time of testing. Diastolic function may also be assessed at the time of a stress echocardiogram.²⁴ Diastolic dysfunction has been shown to be associated with worsened exercise capacity.¹⁹² In patients with normal systolic function and absence of exercise-induced wall motion abnormalities, the ratio of early mitral inflow diastolic velocity to early mitral annulus diastolic velocity (E/e') measured at the time of ESE has been shown to be independently associated with clinical outcomes including mortality, cardiovascular events, and heart failure or hospitalization during long-term follow-up.¹⁹³ Among patients undergoing DSE, those who developed ischemia had lower diastolic annulus velocities at baseline (5.7 ± 1.9 vs 6.4 ± 1.9 cm/sec, $P = .02$) and at peak stress (5.2 ± 1.6 vs 7.4 ± 2.4 cm/s, $P < .0001$). The increase in E/e' was greater in patients who presented with dyspnea, and E/e' at peak stress was higher in those with ischemia and persisted into recovery.¹⁹⁴ Left atrial size, another marker of increased left ventricular filling pressure as well as mitral valve disease, can be assessed at the time of stress echocardiography and used to stratify risk.^{191,192,195} Pulmonary artery systolic pressure can be measured at rest and with exercise and normal values have been established over a broad range of age.¹⁹⁶ Valvular abnormalities and cardiomyopathy, pulmonary hypertension or exercise-induced abnormalities of pulmonary pressure can also be detected during ESE or DSE in conjunction with assessment for ischemia.

Key Point

1. ESE or DSE are appropriate for evaluation of the patient presenting with exertional dyspnea. In addition to detecting ischemia, diastolic dysfunction, pulmonary hypertension and other cardiac causes of this symptom can be readily detected (Class of recommendation 1, level of evidence B).

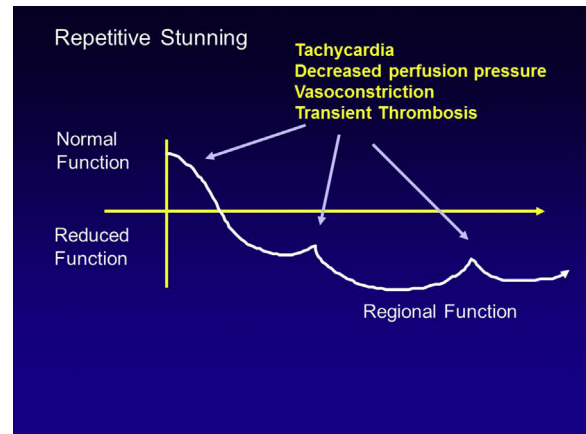


Figure 18 Repetitive stunning. Repetitive ischemic insults may lead to prolonged, chronic contractile dysfunction. Myocardial regions with baseline normal function that are subjected to ischemia may have the appearance of chronic dysfunction if functional recovery from stunning has not occurred before the next episode of ischemia.

e. Stress Echocardiography in Patients with Left Bundle Branch Block

The prevalence of CAD in patients with LBBB is between 30 and 50%.¹⁹⁷ Exercise ECG stress testing is not an option. Specificity of exercise SPECT is reduced in patients with LBBB due to a high rate of false-positive reversible perfusion defects, especially in the septum, and dipyridamole or adenosine are preferred. In contrast, stress echocardiography has a good specificity in patients with LBBB. Early studies showed a satisfactory accuracy of ESE and DSE for detection of angiographic CAD even with the inclusion of patients with limited exercise capacity and limited acoustic windows, and without the use of UEA. More recently, the prognostic value of ESE and pharmacologic stress echocardiography in patients with LBBB has been evaluated.¹⁹⁸ Five-year survival was significantly lower in patients with LBBB and an abnormal stress echocardiogram (77%) vs. patients with LBBB and a normal stress echocardiogram (92%; $P = .02$). Resting WMSI and abnormal stress echocardiogram were independently associated with cardiac death and the stress echocardiography data provided incremental prognostic information over clinical and resting echocardiographic parameters for predicting cardiac death. Patients with LBBB but with a normal ESE had a good prognosis (event rates of 0.92%/yr) whereas patients with LBBB and an abnormal stress echocardiogram had worse outcomes (mortality rate of 4.4%/yr and a major adverse cardiovascular event [MACE] rate of 3.6%/yr). The MACE rate in patients with ischemia was twice as high for patients with an abnormal stress echocardiogram vs. those with a normal stress echocardiogram and LBBB. Among patients with a normal stress echocardiogram, those with LBBB had similar mortality to those without LBBB.¹⁹⁹ Assessment of wall thickening as a marker of ischemia during stress echocardiography in patients with LBBB was more specific than assessment of myocardial perfusion with nuclear imaging.^{200,201} Compared to nuclear perfusion imaging, stress echocardiography has the added benefit that nonischemic cardiac conditions associated with LBBB, such as hypertensive heart disease, valvular heart disease, and cardiomyopathy can be recognized from the baseline echocardiographic images. Quantitative assessment of myocardial deformation may increase the prognostic value of stress echocardiography in patients with LBBB.²⁰²

Table 9 Responses of dysfunctional myocardium to dobutamine

	Low dose	High dose	Improve with revascularization
Stunned*	Improve from rest	Decrease from low dose with severe stenosis Improve from low dose, no change, decrease from low dose with mild to moderate stenosis	Yes
Hibernating**	Improve from rest, no change, decrease from rest	Decrease from low dose if initial improvement with expected severe stenosis	Yes, may be delayed or partial improvement
Remodeled***	Improve from rest, no change	Improve from low dose, no change from low with no or mild stenosis	Possibly if LV volume, wall stress decrease
Limited nontransmural infarction****	Improve from rest	No change, decrease from low dose with severe stenosis Improve from low dose, no change, decrease from low dose with mild to moderate stenosis	No
Limited nontransmural infarction with stunning, hibernation	Improve from rest	Decrease from low dose or from rest with severe stenosis Improved from low dose if stunned, no change, decrease from low dose with mild to moderate stenosis	Yes
Extensive nontransmural infarction Transmural infarction	No change	No change with severe stenosis No change with mild to moderate stenosis	No

*A proportion of stunned segments not subtended by severe stenosis may have sustained or continued improvement with higher dose dobutamine. **It is assumed that severe stenosis is always present with hibernation. A proportion of these segments will not improve with dobutamine because of limited perfusion, and/or degraded contractile proteins. ***Remodeled segments may or may not improve with dobutamine, depending on the severity of remodeling, and the degree of reduction in wall stress and cavity volume. It is assumed that remodeled segments are not supplied by obstructed vessels. ****Depending on the extent of nontransmural injury, segments with partial injury may not exhibit contractile reserve until higher dose dobutamine infusion.

The addition of perfusion analysis with UEAs has also improved the specificity of stress echocardiography in detecting significant CAD, when compared to radionuclide SPECT imaging.⁸⁵ UEAs have also been useful for evaluating wall thickening in the segments that are dyssynchronous.²⁰³

Key Points

1. ESE or DSE may be used for detection of ischemia and risk stratification in patients with LBBB (Class of recommendation I, level of evidence B).
2. In LBBB, stress echocardiography allows recognition of non-ischemic conditions also associated with LBBB.

f. Preoperative Risk Stratification

The leading cause of mortality after anesthesia and surgery is perioperative cardiac complications. For pre-operative risk stratification, exercise testing is the modality of choice in most patients who can ambulate. Exercise provides an estimate of functional capacity and hemodynamic response with exercise. However, many patients undergoing intermediate- and high-risk operations (such as vascular surgery) are unable to exercise or have abnormalities on their resting electrocardiogram precluding exercise ECG stress testing. High-risk

patients often have limited exercise capacity because of non-cardiac diseases such as peripheral artery disease, atherosclerosis, arthritis, and chronic pulmonary disease; in these, pharmacological stress testing is preferred. DSE has been shown to be useful for perioperative risk stratification in patients undergoing non-cardiac surgery, including major vascular surgery and non-vascular surgery.^{204,205} The strongest predictors of postoperative adverse events were ischemia during DSE and a history of congestive heart failure. DSE findings, including the heart rate at which ischemia develops, could be used to stratify patients at low, intermediate, and high risk for postoperative myocardial infarction and death. A normal study conferred excellent outcome. Similar to other stress imaging techniques, the positive predictive value of DSE for predicting adverse events in patients undergoing peripheral vascular surgery was 13% (range 7-42%). However, the negative predictive value, as shown in several studies, is excellent (99%) (range 93-100%).²⁰⁶⁻²¹⁰ In multiple studies and meta-analyses, the prognostic value of DSE was at least as good as that of SPECT imaging for predicting adverse post-operative events.^{209,211-214} In patients evaluated with DSE before vascular surgery and followed for 19 ± 11 months postoperatively, the presence of extensive (3 segments) stress-induced new wall motion abnormalities and previous myocardial infarction independently predicted late cardiac events.²⁰⁶

Key Points

1. In patients in whom preoperative stress testing is appropriate before noncardiac surgery, a normal DSE has been shown to be associated with an excellent outcome whereas a positive study is associated with peri-operative events.
2. The heart rate at which ischemia develops during DSE can be used for risk stratification.

g. Impact of Contrast on Prognosis

Prognostically, the incremental value of myocardial perfusion imaging over wall motion analysis in predicting patient outcome has been demonstrated in primarily single center studies with bicycle stress,¹⁴¹ treadmill exercise,¹⁴³ DSE,^{7,82,143,215} and dipyridamole stress.¹³⁵ In each of these settings, delayed replenishment of contrast during a continuous infusion of microbubbles was seen in a significant percentage of patients in the absence of wall motion abnormalities (Videos 21 and 22, available online at www.onlinejase.com), and appeared to have independent predictive value. The incremental value of perfusion imaging with VLMI has also been demonstrated in a prospective randomized comparison in over 2000 patients, where the control group received UEAs for the FDA-approved indication, and where UEAs were used with low MI harmonic imaging. In this setting, VLMI imaging not only detected perfusion defects in the absence of RWM abnormalities, but also improved the detection of RWM abnormalities due to less basal segment attenuation and better detection of subendocardial ischemia.¹⁴³

Key Points

1. When properly performed, perfusion imaging with RTMCE improves the prognostic value of bicycle, dobutamine, and vasodilator stress echocardiography.
2. VLMI multi-pulse imaging with UEAs is preferred over low MI imaging to improve the detection of regional wall motion abnormalities. (Class of Recommendation I, Level of Evidence B).

VIII. ASSESSMENT OF MYOCARDIAL VIABILITY

The recognition that ischemia-induced LV systolic dysfunction could improve with revascularization provided the rationale for the detection of viable myocardium with the potential for functional recovery. Nonrandomized investigations showed that patients with chronic ventricular dysfunction and multivessel disease have improvement of global function and prognosis with revascularization.²¹⁶ Chronic myocardial dysfunction without injury may be a manifestation of repetitive episodes of ischemia causing myocardial stunning²¹⁷⁻²¹⁹ (Figure 18). The contractile function of regions with normal resting blood flow but limited perfusion reserve is vulnerable to repeated episodes of ischemia. Chronic contractile dysfunction has also been attributed to myocardial hibernation.²¹⁸ Early descriptions of this entity emphasized the presence of a reduction of function secondary to a proportionate reduction in resting perfusion. More recent studies have shown that resting perfusion is often normal or only mildly reduced in regions with persistent contractile dysfunction, suggesting that repetitive stunning and hibernation are related processes.^{220,221} Hibernating myocardium is vulnerable to permanent injury and timely revascularization is necessary to avoid delayed or incomplete recovery of function.²²²⁻²²⁴

a. Assessment of Contractile Reserve

The presence of extensive Q waves, marked LV enlargement, grade 3 to 4 diastolic dysfunction, and echocardiographic evidence of extensive scar (≤ 0.5 - 0.6 cm wall thickness with increased echogenicity) identifies subjects with IHD who are less likely to have improvement in function with revascularization.^{50,225} However, information on viability provided by the resting echocardiogram is often insufficient for clinical decision making. Stress echocardiographic methods that utilize agents to stimulate contraction in dysfunctional but viable myocardium provide more accurate information on the potential for functional recovery. The most widely used method assesses functional responses to dobutamine stimulation. At low doses, the potent inotropic effect of dobutamine can stimulate contraction without a substantial increase in heart rate and oxygen consumption.²²⁶ Contractile reserve, that is, augmentation of contractility of a severely hypokinetic or akinetic segment, can be elicited by dobutamine when resting blood flow is modestly decreased, enabling detection of hibernating myocardium.^{227,228} In the setting of reduced resting blood flow and no or limited flow reserve, hibernating myocardium may manifest contractile reserve at a low dose stage and then show deterioration of function at higher doses due to ischemia (biphasic response). Contractile reserve can also be assessed using low level exercise, phosphodiesterase inhibitors, vasodilators (dipyridamole, adenosine, and nitroglycerin) and after induction of a premature ventricular beat.²²⁹⁻²³¹ Dobutamine is the preferred agent for viability assessment. Other agents can be utilized depending on the clinical setting. In a patient who can perform bicycle exercise, contractile reserve can be assessed during an early stage of the test. Excessive increases in myocardial oxygen demand (tachycardia or increased afterload) or significant declines in aortic diastolic pressure and coronary driving pressure should be avoided.

b. DSE Protocols for Assessing Viability

It is recommended that imaging is performed during at least two low dose stages (2.5, 5, 7.5, 10 $\mu\text{g}/\text{kg}/\text{min}$). The length of each infusion stage can be adjusted based on the observed contractile response, change in hemodynamics, and the requirements of imaging. Testing can be performed at the bedside in subjects in the intensive care unit (ICU). Videos 26 and 27 (available online at www.onlinejase.com) show an example of a bedside viability study. Continuous echocardiographic monitoring should be performed and in the optimal setting a physician interpreter is present to monitor for subtle and sometimes transient increases in function that may occur in hibernating myocardium.²²⁷ Discontinuation of beta-blockers is not essential but intermediate doses of dobutamine (15-20 $\mu\text{g}/\text{kg}/\text{min}$) may be needed to elicit a contractile response in the presence of beta-blocker therapy and the number of segments demonstrating contractile reserve may be reduced.²³² For low and intermediate dose protocols, continuous monitoring of at least several ECG leads should be performed for detection of ischemic ST-segment abnormalities and arrhythmias.

Although considerable information on viability can be obtained with low dose dobutamine, utilization of stress doses enables detection of flow-limiting stenosis by eliciting a biphasic response (Video 28, available online at www.onlinejase.com). Use of stress doses also enables identification of ischemia in regions with normal baseline wall motion, providing additional information on which regions should be revascularized. The literature often distinguishes between "low dose" and "high dose" protocols, indicating that the latter is used for detection of flow-limiting stenosis but the dose (and heart rate or

rate-pressure product) required to produce ischemia will be dependent on the severity of epicardial and microvascular disease.²³³ The small risks of arrhythmias or an ischemic event in patients with severe coronary artery obstruction should be considered before proceeding to high dose dobutamine infusion. High dose dobutamine infusion can be safely conducted in subjects with ischemic cardiomyopathy.^{234,235}

c. Interpretation of Wall Motion Response for Assessment of Viability

Table 9 displays the most common expected responses of dysfunctional myocardium to dobutamine. Segments with stunning, hibernation, remodeling, and limited nontransmural infarction are expected to exhibit contractile reserve at low doses of dobutamine in most instances. In the presence of severely reduced resting perfusion, hibernating myocardium may exhibit limited and transient contractile reserve. Lack of improvement in function with low dose dobutamine indicates more extensive nontransmural injury or transmural injury. Because of tethering effects, the subjective nature of visual assessment, and the relationship of prognosis to the number of viable segments, improvement of function in two adjacent segments is considered a more reliable sign of significant viability than slight improvement in an isolated segment. Functional recovery with revascularization may be expected in segments with stunning or hibernation but not necessarily in segments with limited nontransmural infarction unless there is superimposed ischemia.²³⁶ Remodeled segments may not improve in function with revascularization unless there are reductions in LV volume and wall stress.

The responses of viable myocardium to high dose dobutamine can vary based on the presence and extent of nontransmural injury and the severity of coronary artery obstruction. Hibernating segments are expected to exhibit a biphasic response in most cases, an assumption that is supported by studies that this response has the highest positive predictive value for functional recovery (Video 28, available online at www.onlinejase.com).^{233,237} Segments with sustained improvement of contraction are less likely to exhibit functional recovery.^{233,237} The majority of these segments may be remodeled or have nontransmural infarction. Segments that improve in contraction only with high dose are likely to have more extensive nontransmural infarction and have little or no functional recovery. A minority of segments with resting hypokinesis exhibit worsening of function with low dose ($\leq 10 \mu\text{g/kg/min}$) dobutamine (Video 29, available online at www.onlinejase.com). These segments are partially viable, have severely reduced perfusion reserve, and are associated with severe, multivessel coronary artery obstruction, reduced collateral supply, and increased cardiac mortality.^{51,238}

d. Accuracy of DSE for Detection of Viability

Numerous studies have shown that low dose or combined low and high dose dobutamine infusion protocols have clinically useful sensitivity (75 to 80%) and specificity (80 to 85%) for identification of viable segments with functional recovery after revascularization.^{22,239,240} False-negative exams may occur in hibernating regions with disrupted contractile proteins that cannot respond to dobutamine but eventually manifest functional recovery months after revascularization, with reorganization of contractile proteins. Hibernating segments with severely reduced perfusion may not respond to dobutamine or the contractile response may be both transient and of a small degree below the threshold detectable by visual assessment. Demonstration of viability by DSE also has a high sensitivity (86% to

Table 10 Imaging modalities for assessment of viability

Method	Viability Indicator
Resting Echocardiography	
Wall thickness, videointensity	Preserved wall thickness ($\geq 0.5\text{--}0.6$ cm)
UEA	Perfusion
Dobutamine Stress Echocardiography	Contractile reserve
Magnetic Resonance Imaging	
Dobutamine infusion	Contractile reserve
Contrast agent	Absence of scar (absence of delayed enhancement)
Nuclear Imaging	
Positron emission tomography	Glucose utilization assessed by FDG uptake Perfusion (various tracers)
SPECT (Thallium-201)	Perfusion, cell membrane integrity
SPECT (Technetium ^{99m})	Perfusion, membrane integrity, mitochondrial function
SPECT FDG	Glucose utilization assessed by FDG uptake

FDG, Fluorine¹⁸ deoxyglucose.

90%) and reasonable specificity (71% to 90%) for prediction of improvement in global function and outcome (Videos 30-32, available online at www.onlinejase.com).^{237,241-244} The degree of improvement in global function correlates with the number of segments with contractile reserve, the magnitude of reduction in WMSI, or increase in EF with low dose dobutamine. Contractile reserve in 4 to 5 dysfunctional segments is the minimum amount of viable myocardium that predicts a $\geq 5\%$ improvement in EF and improved outcomes with revascularization.^{216,241,243,244}

e. Quantitative Methods for Assessment of Viability

The challenges of visual assessment of wall motion and thickening in regions with resting dysfunction and the necessity of detection of often subtle changes in function provides the rationale for development of quantitative techniques. Doppler assessment of tissue velocities and displacement are useful for quantifying contractile reserve.²⁴⁵⁻²⁴⁷ An increase in basal segment displacement of ≥ 5 mm and a 5% increase in EF predict improvement of global function with revascularization with accuracies of 83% and 87%, respectively.²⁴⁶ The limitations of TDI of myocardial segments confine the application of this method to assessment of viability in basal and mid-portion segments.

Strain and strain rate parameters can be used to differentiate between viable and nonviable myocardium. Supplemental Table 4 (available at www.onlinejase.com) shows data from studies employing strain and strain rate imaging. Quantitative parameters useful for identifying viability include an increase in strain (shortening) or strain rate or a reduction in post-systolic shortening. Speckle-tracking has been employed in a smaller number of studies with variable results.²⁴⁸⁻²⁵⁰ TDI, strain, and strain rate imaging can provide a level of objectivity to the assessment of contractile reserve, potentially improving the sensitivity for viability, and can be recommended as an adjunct to visual assessment.

f. Current Considerations in Assessment of Viability

Evidence from nonrandomized trials has suggested that patients with LV dysfunction and significant viability had improved survival with revascularization compared with medical therapy. In a meta-analysis of 24 studies, annual death rate was 3.2% in subjects with viable myocardium who underwent revascularization compared to 16% in medically treated patients with viability.²¹⁶ Studies employing propensity matching also showed a survival advantage of revascularization in patients with viability.^{251,252} The Surgical Treatment of Ischemic Heart Failure (STICH) trial, which randomized subjects who had ischemic ventricular dysfunction (EF \leq 35%) to coronary artery bypass grafting (CABG) or optimal medical therapy, raised doubts about the utility of assessment of viability.²⁵³ In a substudy of STICH in which patients were designated as having viability based on the number of segments with tracer activity on SPECT, or \geq 5 dysfunctional segments exhibiting contractile reserve with dobutamine, viability was not an independent predictor of death and the presence of viability did not improve 5-year survival in those who had CABG.²⁵⁴ Medically treated patients with viability had lower annual mortality compared to prior studies. In the STICH trial, only half of patients underwent viability testing, which was not randomized.^{255,256} Subjects were at lower risk in terms of the extent of CAD than populations in whom viability testing is usually considered before high risk CABG. The findings of the STICH trial, together with the results of other studies, provide the framework for these recommendations:

Optimization of endocardial border visualization with contrast should be considered for accurate assessment of volumes and EF in patients with ischemic cardiomyopathy. The challenge in obtaining high-quality image data for quantitation in a multicenter study was shown by the inability to measure EF and volumes in 25% of subjects enrolled in STICH.

Reliance on ejection fraction performed during or shortly after an ischemic event may be misleading when determining the patient's risk and whether viability testing may be needed. Many subjects with acute ischemic injury have improvement in global function due to recovery of stunned myocardium.^{257,258} The finding of ejection fraction $>$ 35% in nearly one-fifth of patients in STICH by the echocardiography core lab may have resulted from enrollment based on early imaging studies performed in close proximity to an episode of acute ischemia.

Measures of viability that encompass assessment of global contractility, such as WMSI or EF with low dose dobutamine, may have more prognostic value compared to assessment of contractile reserve in a fixed number of dysfunctional segments.^{246,259-262} The presence of 4 or 5 segments with contractile reserve, which was the definition of viability utilized in STICH, has been correlated with modest (\geq 5%) improvement in ejection fraction that may be below the threshold of measurement variability and may also be insufficient for improvement in prognosis.^{242,263} WMSI and EF assess contractile function and contractile reserve of the whole ventricle rather than limiting assessment to contractile reserve in segments with severe dysfunction. Low dose WMSI may provide incremental prognostic value to a post-revascularization increase in EF for prediction of long-term outcome.²⁶³ Videos 30-32 (available online at www.onlinejase.com) show an example of prediction of the degree of functional recovery using low dose WMSI and EF response to dobutamine. In ischemic cardiomyopathy, the contractile reserve of remodeled segments and normal segments tethered to regions with severe dysfunction may have an impact on outcome in addition to the response of segments with stunning or hibernation.

Testing for viability is not needed in patients with mild LV systolic dysfunction, significant angina, limited comorbidities, and good anatomy for revascularization. However, testing for both ischemia and viability may provide useful information to guide management in patients with moderate LV dysfunction, dyspnea and/or angina, and a variable extent of CAD.²⁶⁴ Revascularization would be indicated with the finding of extensive ischemia. The independent prognostic value of viability might be outweighed by a combination of other factors including the extent and severity of ischemia, the extent of coronary disease, the presence and severity of mitral regurgitation, and the use of medical and device therapies.

At the far end of the spectrum are those with severe global dysfunction, advanced symptoms of heart failure, and severe multivessel disease. The extent of viable myocardium may play a larger role in predicting outcome and the benefit of revascularization in these patients.

IX. COMPARISON WITH OTHER IMAGING MODALITIES

Early studies have compared the accuracy of stress echocardiography and other imaging modalities for detection of angiographic CAD, documenting a similar accuracy.^{1,265} However, many patients undergoing stress testing do not undergo coronary angiography. Studies on the prognostic value of tests allow assessment of large numbers of patients undergoing stress testing but not necessarily coronary angiography. Smaller studies have compared stress echocardiography with other imaging in the same patient population.^{31,265,266} Large studies and meta-analyses have compared the predictive value of stress echocardiography and SPECT in different patients with similar characteristics, noting comparable results.^{119,267,268} The Prospective Multicenter Imaging Study for Evaluation of Chest Pain (PROMISE) study compared anatomic imaging using computed tomographic angiography versus functional imaging in 10,003 stable patients with new symptoms suggestive of CAD. Functional testing was performed according to the treating doctor's preference with exercise electrocardiography, stress SPECT, or stress echocardiography; stress echocardiography was performed in only 1,083 patients. Event rates in both functional and anatomic groups were comparable over a median follow-up of 25 months.²⁶⁹ It should be noted that none of these studies of the comparative value of stress echocardiography versus other modalities have considered the incremental value of ancillary finding detected by echocardiographic imaging performed at the time of the stress echocardiogram, including detection of non-ischemic causes of cardiac symptoms.

Various imaging methods for assessing viability have also been compared; the most common methods are listed in Table 10, along with the marker used to identify viable myocardium. In a prospective study of patients with LV dysfunction, rest-redistribution SPECT-TI had a better sensitivity, but DSE a better specificity for predicting viable myocardium and recovery of function.³¹ For viable myocardium to exhibit a response to dobutamine, an adequate amount of viable tissue must be present, the contractile apparatus must be intact, and some residual perfusion reserve must be present. The ability to demonstrate contractile reserve sharply decreases as the extent of interstitial fibrosis approaches and exceeds 50%. Dobutamine magnetic resonance imaging (MRI) also relies on detection of contractile reserve. MRI utilizing gadolinium contrast detects regions of scar with delayed enhancement. The presence of scar in $<$ 50% of the thickness of the myocardium is a commonly used cutoff value for viability. PET and

Indications for Stress Echo in Children and Young Adults

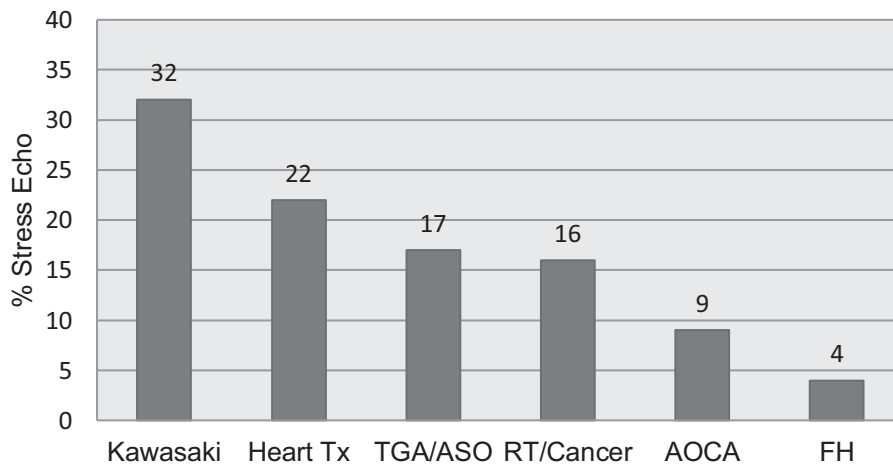


Figure 19 Indications for stress echocardiograms performed in children and young adults at Boston Children's Hospital for evaluation of ischemia from 2006-2017 ($n = 924$). AOCA, anomalous origin of a coronary artery; FH, familial homozygous hypercholesterolemia; RT, radiation therapy to the chest; TGA/ASO, transposition of the great arteries, status post arterial switch operation; Tx, transplant.

SPECT nuclear imaging techniques enable detection of tissue perfusion, with PET possessing higher resolution and the capability for quantitation. A commonly used definition for viable myocardium is the presence of SPECT tracer activity that is at least 50% of tracer activity found in normal myocardium. Additionally, PET or SPECT imaging with FDG (fluorine¹⁸-deoxyglucose) enables assessment of myocardial glucose utilization, which preferentially occurs in hibernating and stunned myocardium and in normal myocardium in glucose loaded states. FDG imaging is performed in combination with perfusion imaging. Stunned segments have normal to increased FDG activity and normal perfusion. Hibernating segments exhibit reduced perfusion, and normal to increased FDG activity, defined as a "mismatch" pattern. Segments with severe reduction in both perfusion and FDG activity (matched pattern) are considered nonviable.

The comparative sensitivity and specificity of the various imaging modalities was reported in several comprehensive review articles.^{22,240,270} The reported sensitivity of nuclear perfusion imaging techniques was higher than DSE since larger amounts of viable myocardium and preservation of the contractile apparatus are necessary for detection of viability by the latter method. However, the specificity of methods for predicting functional recovery that assess contractile reserve is substantially higher than methods that assign viability on the basis of residual perfusion or lack of scar. Regions with nontransmural infarction with residual perfusion tracer activity or midmyocardial-epicardial viability by MRI may not improve function unless there is superimposed stunning or hibernation.

PET FDG imaging is generally regarded as having the highest sensitivity for detection of viable myocardium. Hibernating segments with the mismatch pattern and substantially reduced resting perfusion are less likely to exhibit contractile reserve than stunned segments with normal perfusion.²⁷¹ The specificity of the PET mismatch pattern for functional recovery may be lower than expected, since regions with this pattern represent vulnerable, hibernating myocardium predisposed to permanent ischemic injury if revascularization is delayed, or have incomplete functional recovery because of degraded contractile apparatus.

There are less data on the comparative sensitivity and specificity of the various imaging modalities for prediction of recovery of global ventricular systolic function. FDG and perfusion imaging techniques have

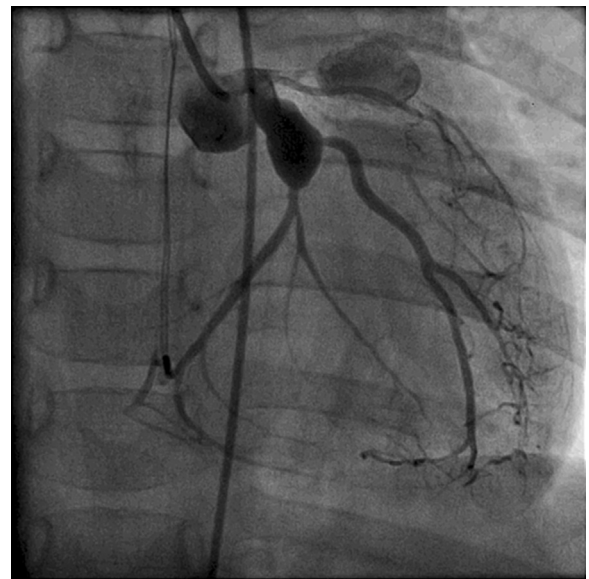


Figure 20 Multiple large coronary artery aneurysms with coronary angiography in a patient with Kawasaki disease.

greater sensitivity for identifying subjects with improvement in global function and DSE has greater specificity.²⁷² However, other echocardiographic studies have shown both high sensitivity and specificity of contractile reserve for prediction of improvement of global function.³¹

Comparative safety of testing modalities should also be considered. The absence of radiation with stress echocardiography makes it an attractive technique for women, because of the radiation sensitivity of breast tissue, and young patients, considering the lifetime cumulative exposure, particularly when serial studies may be required. Organ-specific radiation doses for cardiac SPECT have been shown to be highest for the liver, then heart, thyroid, lung, and breast, whereas for cardiac CT, the breast receives the highest dose.²⁷³ Gadolinium administration as required for CMR may also be undesirable, especially in patients with kidney disease.

Key Points

1. Stress echocardiography has an accuracy similar to that of other stress imaging techniques for detection of angiographic CAD.
2. Stress echocardiography has also been demonstrated to provide similar prognostic information compared to other stress imaging techniques and computed tomography angiography.
3. Comparative studies of the accuracy and prognostic value of stress echocardiography versus other techniques have not considered the incremental value of the additional information available at the time of stress echocardiography regarding the wall thicknesses, chamber sizes, valvular abnormalities, diastolic function, etc., that are assessed at the time of rest imaging.
4. Contractile reserve by DSE compares favorably with other methods for predicting recovery of systolic function of viable segments; compared to perfusion imaging techniques, DSE has mildly lower sensitivity but better specificity.
5. Absence of radiation or need for gadolinium as well as cost benefit makes stress echocardiography an attractive technique for many patients.

Consequently, pediatric centers mostly have utilized DSE and recumbent bicycle stress testing, since these techniques allow for imaging at multiple time periods. These advantages may facilitate the implementation of stress echocardiography in pediatric cardiology practices. [Supplemental Table 5](#) (available at www.onlinejase.com) summarizes pediatric stress echocardiography studies, the type of stress used, and the findings.

Key Points

1. Pediatric stress echocardiography using exercise or dobutamine stress has been increasingly utilized for the detection of ischemia and assessment of exercise tolerance.
2. ESE is extremely well-tolerated in children as it requires no sedation, needle stick, or radiation exposure and can be considered for children age 6 or older.

Pediatric or adult congenital patients who are at high risk for ischemia and premature CAD include patients with (a) prior cardiac transplantation, (b) Kawasaki disease with coronary aneurysms, (c) anomalous aortic origin of the coronary artery, (d) familial hyperlipidemia, (e) transposition of the great arteries, status post arterial switch operation, and other congenital heart surgeries where the coronary arteries have been re-implanted, as well as those with prior chest radiation. Applications of stress echocardiography in nonischemic conditions have been discussed in detail in ASE/EACVI recommendations.⁴

a. Pediatric Cardiac Transplantation

Transplant-induced coronary vasculopathy is an important cause of graft loss, cardiac re-transplantation, and late mortality in cardiac transplant recipients in both adults and children.²⁷⁸ Although annual coronary angiography has been the gold standard for the screening of epicardial CAD in children, DSE in children was shown to be safe and feasible, with good sensitivity and specificity.²⁷⁹ In a large series of patients, an increased likelihood of an abnormal DSE with higher grade of angiographically determined coronary vasculopathy was observed.²⁷² Chen reported that ESE had 89% sensitivity and 92% specificity for detection of CAD, and a 97% negative predictive value for exclusion of coronary artery vasculopathy.²⁷⁶ Consequently, asymptomatic children with a negative stress echocardiogram can extend the interval between angiograms to 2 years, reducing radiation exposure.

Key Points

1. Either DSE or ESE, which both have a high negative predictive value, are recommended to help extend the interval between angiograms in the asymptomatic pediatric transplant recipient.
2. For older children who are able to perform an exercise test, this type of test is preferred over DSE for the same reasons as for adults.

b. Kawasaki Disease

Kawasaki disease (KD) is the leading cause of acquired IHD in children and is characterized by a systemic inflammatory vasculitis that may involve the coronary arteries and lead to coronary artery dilation and coronary aneurysms ([Figure 20](#)). Although regression may occur, aneurysms may transition to stenotic or thrombotic CAD.

In children with KD, DSE had excellent specificity and negative predictive value. A positive DSE was also associated with significant

X. RADIATION-INDUCED CORONARY ARTERY DISEASE

Radiation-induced cardiovascular disease is a major cause of morbidity and mortality in long-term cancer survivors. It may affect ostial coronary arteries in a multivessel distribution. ESE has proven useful in screening for ischemia in patients treated with radiation therapy.^{274,275}

Multivessel disease can be more difficult to detect by nuclear imaging, since there is an increased likelihood of false-negative nuclear studies in the setting of balanced ischemia. In contrast, with stress echocardiography, ischemia involving multiple coronary arteries subtends larger regions of ventricular wall segments, and ischemia is readily detected.

Key Point

1. Chest radiation can result in premature multivessel, ostial CAD. Stress echocardiography has advantages over nuclear imaging in the noninvasive assessment of multivessel CAD, secondary to the lower false-negative rate.

XI. STRESS ECHOCARDIOGRAPHY IN PEDIATRIC PATIENTS AND CONGENITAL HEART DISEASE

ESE is very well tolerated in the pediatric population, since it requires no intravenous line placement, sedation, or radiation exposure. ESE can be performed in children who are old enough to exercise on a treadmill or bicycle, and is therefore generally utilized in those 6 years and older.^{276,277} Eleven-year data of the distribution of diagnoses of patients undergoing stress echocardiography for ischemia at a single center are shown ([Figure 19](#)). Despite exercise being well-tolerated in children, treadmill ESE may be underutilized as a non-invasive imaging modality for ischemia in pediatric centers due to lack of experience and familiarity with the methods and the relatively small numbers of pediatric patients in whom ischemia is suspected.

The rapid decrease in peak heart rate post-exercise and the abundant reserve and extensive collateral circulation in children can make ESE challenging for assessment of ischemia.²⁷⁶

Table 11 Stress echocardiography orientation and competency checklist

Stress Echocardiography Orientation and Competency Checklist			
Institutional Name:			
Sonographer name:			
Preceptor name:			
Dates of training:			# of studies performed
Areas of Orientation and Competency Verification			
Review of:	Reviewed		
Indications for stress echo testing			
Ultrasound equipment and presets			
Supine bicycle, protocol and settings			
Treadmill, protocol and settings			
Dobutamine protocol and settings			
Coronary artery territories			
Contraindications for stress echo			
Required images / data			
Stress echo protocol for ischemia			
Stress echo protocol for viability			
Stress echo protocol for diastolic function			
Adding stages for an expanded protocol			
Factors that may cause false positive stress echo response			
Factors that may cause false negative stress echo response			
Factors that may cause false positive stress ecg response			
Factors that may cause false negative stress ecg response			
Endpoints to terminate stress testing			
Incorporating UEAs into stress protocol			
Required documentation for report preparation			
Preliminary report preparation			
Able to:	Exceptional	Satisfactory	Needs development
Select appropriate protocol / preset for study indication			
Recognize contraindication to stress echo			
Determine peak targeted heart rate			
Perform supine bicycle stress echo study			
Perform treadmill stress echo study			
Perform dobutamine stress echo study			
Obtain requisite images and at each stage			
Recognize wall motion abnormalities			
Recognize viable segments			
Recognize false positive or negative stress echo response factors			
Add stages to protocol			
Incorporate UEA in stress echo			
Recognize symptoms/ecg/echo findings to terminate exam			
Prepare preliminary report			

Table 12 Recommendations for stress echocardiography in patients with symptoms or suspected stable coronary artery disease

Recommendations for non-invasive testing for IHD	Class of recommendation	Level of evidence
In patients with suspected stable CAD, intermediate pretest probability and preserved ejection fraction, stress imaging, such as stress echocardiography, is preferred as the initial test option.	I	B
In patients without typical angina, an imaging stress test, such as stress echocardiography, is recommended as the initial test for diagnosing stable CAD if the pretest probability is high or if LVEF is reduced.	I	B
In patients with suspected CAD and with resting ECG abnormalities, which prevent accurate interpretation of ECG changes during stress, an imaging stress test, such as stress echocardiography, is recommended.	I	B
In patients with LBBB and symptoms consistent with IHD, stress echocardiography (either ESE or DSE) is preferred over SPECT imaging because of its greater specificity and because of its versatility for detecting other cardiac conditions associated with LBBB	I	B
Stress echocardiography is the preferred test for women with an indication for a noninvasive imaging test for known or suspected CAD because of its safety (absence of radiation to the breasts), and greater specificity (absence of breast attenuation artifact)	I	B
ESE is the preferred imaging stress test for children with suspected IHD because of the absence of radiation to developing tissues and absence of need for an intravenous line, and the provision of the prognostically important assessment of exercise capacity	I	B
A pharmacologic stress test, such as DSE, is recommended for patients with the above indications for a stress imaging test who are unable to exercise.	I	B
Stress echocardiography is the preferred test in patients with exertional dyspnea of uncertain etiology. In these patients, in addition to assessment of regional wall motion, tricuspid regurgitation velocity and diastolic function should be assessed at rest and with stress	I	B
An imaging stress test, such as stress echocardiography, should be considered in patients with prior coronary artery revascularization (PCI or CABG) and new cardiac symptoms.	IIa	B
An imaging stress test, such as stress echocardiography, should be considered to assess the functional severity of intermediate lesions on coronary arteriography.	IIa	B
Recommendations for risk stratification using ischemia testing	Class of recommendation	Level of evidence
A stress imaging test such as stress echocardiography for risk stratification is recommended in patients with an inconclusive exercise ECG	I	B
A stress imaging test, such as stress echocardiography, is recommended for risk stratification in patients with known stable CAD and a deterioration in symptoms if the site and extent of ischemia would influence clinical decision making	I	B
In asymptomatic adults with diabetes, peripheral vascular disease, or a strong family history of CAD, or when previous risk assessment testing suggests high risk of CAD, such as a coronary artery calcium score of ≥ 400 , a stress imaging test, such as stress echocardiography, may be considered for advanced cardiovascular risk assessment. ²⁰⁸	IIb	B
Recommendation for re-assessment in patients with stable CAD	Class of recommendation	Level of evidence
An exercise ECG or stress imaging test such as stress echocardiography is recommended in the presence of recurrent or new symptoms once instability has been ruled out.	I	C
In symptomatic patients with revascularized stable CAD, a stress imaging test, such as stress echocardiography, is indicated rather than stress ECG.	I	C
Reassessment of prognosis using a stress test, such as stress echocardiography, may be considered in asymptomatic patients after the expiration of the period for which the previous test was felt to be valid	IIb	B
Recommendations for stress echocardiography in the context of non-cardiac surgery	Class of recommendation	Level of evidence
Recommendations for non-invasive stress testing of IHD	Class of recommendation	Level of evidence
A pharmacologic stress imaging test such as DSE is recommended before high-risk surgery in patients with more than two clinical risk factors and poor functional capacity (<4 METs).	I	B
A pharmacologic stress imaging test such as DSE may be considered before high- or intermediate-risk surgery in patients with suspected cardiac symptoms and poor functional capacity (<4 METs).	I	B

coronary abnormalities.²⁸⁰ Fifteen-year cumulative event-free survival was 25% if the WMSI was ≥ 1.25 and 92% in patients with a WMSI < 1.25 . ESE has been used successfully in the diagnosis of ischemia in high-risk patients and predicted late sequelae for cardiovascular disease.²⁸⁰

Key Point

1. Stress echocardiography is useful for serial screening and prognosis in KD patients with coronary aneurysms; wall motion score index can be used to prognosticate 15-year cumulative event-free survival.

c. Anomalous Origin of a Coronary Artery

Although relatively rare, anomalous coronary artery syndrome is the second most common cause of non-traumatic sudden cardiac death in young athletes.²⁸¹ High-risk variants for sudden death include anomalous origin of the left coronary artery with an intramural course or an inter-arterial course. Surgical unroofing of the coronary artery or repair is performed in patients with high-risk variants, especially those who participate in strenuous activities; however, the clinical management of asymptomatic patients with anomalous origin of the right coronary artery is still a subject of debate.²⁸² Stress echocardiography, along with multi-modality stress imaging, may assist in the decision of which patients to manage medically vs surgically.^{281,283} ESE also has begun to be implemented in the routine post-operative follow-up of children after unroofing or re-implantation of the anomalous coronary artery.²⁸³ ESE also provides baseline data for children with AOCA prior to surgery or in patients who do not undergo surgery.

Key Point

1. Stress echocardiography provides helpful information in the pre-operative diagnosis and serial long-term follow-up of patients with AOCA. (Class of Recommendation IIa, Level of Evidence B)

d. Transposition of the Great Arteries, Status Post Arterial Switch Operation

Dextro-loop transposition of the great arteries (d-TGA) is most commonly repaired by an arterial switch operation (ASO) performed at birth, which requires re-implantation of the coronary arteries. Although overall long-term survival is above 95%, coronary artery stenosis, impingement, or occlusion may occur in about 5% of patients.^{284,285} Given the excellent survival rates,²⁸⁴ the optimal timing and the non-invasive method to screen for ischemia in asymptomatic ASO patients need further investigation.²⁷²

e. Familial Hypercholesterolemia

In patients with homozygous familial hypercholesterolemia, untreated low-density lipoprotein (LDL) cholesterol concentrations exceed 400 to 500 mg/dl in childhood and can result in severe atherosclerotic heart disease, myocardial infarction in children, and mortality before age 20. Given the need for continued intensive follow-up, serial assessment by pediatric stress echocardiography may be useful.

XII. TRAINING REQUIREMENTS AND MAINTENANCE OF COMPETENCY

a. Sonographer Training

Guidelines for sonographer training in stress echocardiography are shown in Table 11. Sonographers embarking on stress echocardiography training for the evaluation of IHD should optimally have independently performed 1,000 complete resting transthoracic echocardiograms (TTE) with a minimum of one year's experience (preferably two years) in the field of echocardiography. They should have extensive experience in evaluating patients with CAD.²⁸⁶ They must (a) demonstrate technical competence and strong scanning ability when performing resting TTEs, (b) obtain high quality on-axis images and recognize pathophysiology, and (c) differentiate normal from abnormal function of both left and right ventricles. The sonographer must understand coronary distribution and perfusion territories,⁴⁷ the 16- and 17-segment wall motion plots, and the corresponding echocardiographic views (Figure 8).⁴⁷ The sonographer trainee must be able to obtain high-quality images during pharmacologic or supine bicycle stress echocardiography and within 60 to 90 seconds after termination of stress (treadmill, bicycle, or pharmacologic).²⁸⁶ The sonographer trainee must understand the indications and contraindications for performance of the stress echocardiographic exam and also the end point for a particular exam. The trainee must understand the various functionalities of the equipment used for the exam (protocols, presets, adding stages, etc.).

For training, the trainee sonographer should be paired with a more senior sonographer who oversees the orientation and performance of stress echocardiograms, including reviews of the various protocols and presets of the equipment, as well as performance for assessment of both myocardial ischemia and viability. The facility should document that the trainee has met the competencies for the various aspects of the training and can perform the stress echocardiograms independently. Sonographers must be certified in basic life support training. Sonographers should perform at least 100 stress echocardiograms annually for maintenance of competency.¹

Sonographers should be trained in optimal use of UEAs for LVO. This should include recognizing indications for use, knowledge of pulse sequence schemes and their physics, and how to use UEAs for LVO and myocardial perfusion. ASE guidelines recommend sonographer training in both starting intravenous lines and administration of UEAs, so as to facilitate the appropriate use of UEAs in clinical practice.¹³

b. Physician Training

Interpretation of stress echocardiographic studies is particularly challenging, and several documents have addressed the requirements for training. In order to develop consistent training guidelines across all aspects of cardiology, the COCATS level 4 Task Force 5 was developed, represented by members of both the American College of Cardiology (ACC) and ASE.²⁴⁸ The document outlines the core competence, curricular milestones, and training requirements for echocardiography. While some exposure to stress echocardiography may occur during level I training, individuals desiring to interpret stress echocardiograms must complete level II training, which includes a minimum of 150 TTE exams performed and 300 TTE exams interpreted.^{1,248} Training programs should include didactic lectures and require participation in the monitoring of various stress echocardiographic studies. The

trainees should understand the advantages, limitations, and risks of the different stress imaging tests (pharmacologic, bicycle, or treadmill) and integrate that information into the clinical scenario for a given patient. In addition to meeting the level II training requirements, for competence in stress echocardiography the trainee must have interpreted a minimum of 100 stress echocardiographic studies, supervised by a level III trained echocardiographer. However, level III training, which requires supervised interpretation of an additional 100 studies, is required for applying stress echocardiography to assessment of hemodynamic responses to stress, such as in valvular heart disease, hypertrophic cardiomyopathy, pulmonary hypertension, and diastolic stress testing, and assessment of viability and myocardial perfusion.²⁸⁷ For maintenance of competency, it is recommended that physicians interpret a minimum of 100 stress echocardiograms per year, in addition to participation in relevant continuing medical education.¹

c. Training for Contrast Perfusion Imaging

No formal training guidelines exist for perfusion imaging with RTMCE. RTMCE has been utilized routinely only at experienced centers. Adequate didactic and hands-on training is required to optimally use ultrasound contrast with RTMCE. The multi-center trials using perfusion echocardiography with RTMCE have not required a systematic prerequisite training program to be completed prior to study participation, and comparative effectiveness trials with radionuclide imaging have demonstrated that this lack of prerequisite training consistently leads to reduced accuracy in CAD detection during stress testing.^{85-87,144,145,147,149} Independent performance of perfusion imaging with continuous infusion of ultrasound contrast requires training at an experienced site.

d. Training for Pediatric Stress Echocardiography

In contrast to adult cardiology practices, the volume of patients at pediatric centers is substantially smaller. Since ischemia is less common in children than adults, pediatric cardiology practices have significantly less exposure to wall motion abnormalities and their angiographic correlations. Therefore, the acquisition of stress echocardiography skills in pediatric centers requires concerted practice over the course of several years. Sonographers who are trained in both adult and pediatric imaging are important to help build a pediatric stress echocardiography program. Furthermore, the collaboration of individuals with Level III training in adult imaging, especially those having extensive experience in stress echocardiography, and pediatric non-invasive imagers well-versed in congenital heart disease, would enable more rapid adaptation of this modality in children at different centers. Consultation with national stress echocardiography experts with combined experience in both adult and pediatric stress echocardiography may serve as a resource for new centers considering implementation of this modality in children.

Key Points

1. Dedicated training with a more senior sonographer who oversees the orientation and performance of stress echocardiograms is required for a sonographer to learn to perform stress echocardiography. This should not occur until the individual has performed at least 1,000 transthoracic echocardiograms and has a minimum of 1 year's clinical experience.
2. Sonographers should perform at least 100 stress echocardiograms annually for maintenance of competency.

3. For competence in interpreting stress echocardiography the physician must have mastered TTE and interpreted a minimum of 100 stress echocardiographic studies, supervised by a level III trained echocardiographer.
4. For maintenance of competency, it is recommended that a physician interpret a minimum of 100 stress echocardiograms per year, in addition to participation in relevant continuing medical education.

XIII. APPROPRIATE USE CRITERIA AND STRESS ECHOCARDIOGRAPHY

Increases in the use of diagnostic imaging in the 1990s and early 2000s prompted professional societies to develop guidelines for the effective use of imaging. The first effort, led by the ACC in partnership with the American Society of Nuclear Cardiology, was the development of appropriate use criteria for nuclear perfusion imaging in 2005.²⁸⁸ Guidelines for the appropriate use of echocardiography and stress echocardiography followed in 2007 and 2008, respectively,^{249,289} as a collaborative effort of the ACC, the ASE, and other professional societies, and were updated in 2010.²⁹⁰ Most recently, the ACC has directed appropriate use criteria to not focus on a given imaging modality, but instead have considered the role of multimodality imaging in the case of a diagnosis or disease state. Relevant to stress echocardiography is the 2012 ACCF/AHA/ACP/AATS/PCNA/SCAI/STS Guideline for the Diagnosis and Management of Patients With Stable Ischemic Heart Disease, in which stress echocardiography and nuclear perfusion scintigraphy were rated as similarly appropriate for diagnosis or risk stratification of patients with symptoms of suspected cardiac etiology.²⁵⁰ Updated recommendations from the literature, including the current level of evidence as summarized in these guidelines for stress echocardiography are shown in [Table 12](#).

XIV. SUMMARY

Stress echocardiography is a mature technique for the assessment of known or suspected IHD. It may be performed with either treadmill or bicycle exercise or combined with a pharmacologic agent for the patient who is unable to complete an exercise protocol. Its use has extended into pediatric populations. The feasibility is excellent with current technology and use of an image enhancing agent, where necessary. Stress echocardiography may be appropriately applied to the diagnosis of IHD, to detect viable myocardium in the patient with LV dysfunction, or stratify risk, or predict prognosis. The baseline images uniquely allow for rapid recognition of other causes of cardiac symptoms. Quantitative methods, including strain imaging, as well as myocardial perfusion imaging and 3D imaging, are important advances that will continue to place this technique at the forefront of cardiac imaging and stress testing.

NOTICE AND DISCLAIMER

This report is made available by ASE as a courtesy reference source for members. This report contains recommendations only and should not be used as the sole basis to make medical practice decisions or for disciplinary action against any employee. The statements and

recommendations contained in this report are primarily based on the opinions of experts, rather than on scientifically verified data. ASE makes no express or implied warranties regarding the completeness or accuracy of the information in this report, including the warranty of merchantability or fitness for a particular purpose. In no event shall ASE be liable to you, your patients, or any other third parties for any decision made or action taken by you or such other parties in reliance on this information. Nor does your use of this information constitute the offering of medical advice by ASE or create any physician-patient relationship between ASE and your patients or anyone else.

ACKNOWLEDGMENTS

Reviewers: This document was reviewed by members of the 2018-2019 ASE Guidelines and Standards Committee, ASE Board of Directors, and ASE Executive Committee. Reviewers included Bonita Anderson, MAPPLSC, DMU, AMS, FASE, ACS, Azin Alizadehas, MD, FASE, Scott D. Choyce, RDCS, RVT, RDMS, FASE, Craig Fleishman, MD, FASE, Benjamin Freed, MD, FASE, Mark K. Friedberg, MD, FASE, Edward Gill, MD, FASE, Robi Goswami, MD, FASE, Renuka Jain, MD, FASE, Pei-Ni Jone, MD, FASE, Stephen H. Little, MD, FASE, Judy Mangion, MD, FASE, Anuj Mediratta, MD, FASE, Andy Pellett, PhD, RCS, RDCS, FASE, Dermot Phelan, MD, PhD, FASE, Juan Carlos Plana, MD, FASE, Geoffrey A. Rose, MD, FASE, David S. Rubenson, MD, FASE, Fadi Shamoun, MD, FASE, David H. Wiener, MD, FASE, and Megan Yamat, RDCS, RCS, FASE.

The authors appreciate the technical support of Ms. Tessa Flies with manuscript preparation.

SUPPLEMENTARY DATA

Supplementary data related to this article can be found at doi:<https://doi.org/10.1016/j.echo.2019.07.001>.

REFERENCES

- Pellikka P, Nagueh S, Elhendy A, Kuehl C, Sawada S. American Society of Echocardiography recommendations for performance, interpretation, and application of stress echocardiography. *J Am Soc Echocardiogr* 2007;20:1021-41.
- Halperin JL, Levine GN, Al-Khatib SM, Birtcher KK, Bozkurt B, Brindis RG, et al. Further evolution of the ACC/AHA clinical practice guideline recommendation classification system: a report of the American College of Cardiology/American Heart Association Task Force on Clinical practice guidelines. *J Am Coll Cardiol* 2016;67:1572-4.
- Picano E, Pellikka PA. Stress echo applications beyond coronary artery disease. *Eur Heart J* 2014;35:1033-40.
- Lancellotti P, Pellikka PA, Budts W, Chaudhry FA, Donal E, Dulgheru R, et al. The clinical use of stress echocardiography in non-ischaemic heart disease: recommendations from the European Association of Cardiovascular Imaging and the American Society of Echocardiography. *J Am Soc Echocardiogr* 2017;30:101-38.
- Attenhofer CH, Pellikka PA, Oh JK, Roger VL, McCully RB, Shub C, et al. Is review of videotape necessary after review of digitized cine-loop images in stress echocardiography? A prospective study in 306 patients. *J Am Soc Echocardiogr* 1997;10:179-84.
- Porter TR, Xie F, Kricsfeld A, Chiou A, Dabestani A. Improved endocardial border resolution during dobutamine stress echocardiography with intravenous sonicated dextrose albumin. *J Am Coll Cardiol* 1994;23:1440-3.
- Dolan MS, Riad K, El-Shafei A, Puri S, Tamirisa K, Bierig M, et al. Effect of intravenous contrast for left ventricular opacification and border definition on sensitivity and specificity of dobutamine stress echocardiography compared with coronary angiography in technically difficult patients. *Am Heart J* 2001;142:908-15.
- Falcone RA, Marcovitz PA, Perez JE, Dittrich HC, Hopkins WE, Armstrong WF. Intravenous albumin during dobutamine stress echocardiography: enhanced localization of left ventricular endocardial borders. *Am Heart J* 1995;130:254-8.
- Plana JC, Mikati IA, Dokainish H, Lakkis N, Abukhalil J, Davis R, et al. A randomized cross-over study for evaluation of the effect of image optimization with contrast on the diagnostic accuracy of dobutamine echocardiography in coronary artery disease. The OPTIMIZE Trial. *JACC Cardiovasc Imaging* 2008;1:145-52.
- Dolan MS, Gala SS, Dodla S, Abdelmoneim SS, Xie F, Cloutier D, et al. Safety and efficacy of commercially available ultrasound contrast agents for rest and stress echocardiography: a multicenter experience. *J Am Coll Cardiol* 2009;53:32-8.
- Porter TR, Mulvagh SL, Abdelmoneim SS, Becher H, Belcik JT, Bierig M, et al. Clinical applications of ultrasonic enhancing agents in echocardiography: 2018 American Society of Echocardiography Guidelines Update. *J Am Soc Echocardiogr* 2018;31:241-74.
- Mulvagh SL, Rakowski H, Vannan MA, Abdelmoneim SS, Becher H, Bierig SM, et al. American Society of Echocardiography consensus statement on the clinical applications of ultrasonic contrast agents in echocardiography. *J Am Soc Echocardiogr* 2008;21:1179-201. quiz 281.
- Porter TR, Abdelmoneim S, Belcik JT, McCulloch ML, Mulvagh SL, Olson JJ, et al. Guidelines for the cardiac sonographer in the performance of contrast echocardiography: a focused update from the American Society of Echocardiography. *J Am Soc Echocardiogr* 2014;27:797-810.
- Bruce RA, Kusumi F, Hosmer D. Maximal oxygen intake and nomographic assessment of functional aerobic impairment in cardiovascular disease. *Am Heart J* 1973;85:546-62.
- Bruce RA, Blackmon JR, Jones JW, Strait G. Exercising testing in adult normal subjects and cardiac patients. *Pediatrics* 1963;32:742-56.
- Roger VL, Pellikka PA, Oh JK, Miller FA, Seward JB, Tajik AJ. Stress echocardiography. Part I. Exercise echocardiography: techniques, implementation, clinical applications, and correlations. *Mayo Clin Proc* 1995;70:5-15.
- Attenhofer C, Pellikka P, Roger V, Oh J, Hepner A, Seward J. Impact of atropine injection on heart rate response during treadmill exercise echocardiography: a double-blind randomized pilot study. *Echocardiography* 2000;17:221-7.
- Modesto KM, Rainbird A, Klarich KW, Mahoney DW, Chandrasekaran K, Pellikka PA. Comparison of supine bicycle exercise and treadmill exercise Doppler echocardiography in evaluation of patients with coronary artery disease. *Am J Cardiol* 2003;91:1245-8.
- Hoffer EP, Dewe W, Celentano C, Pierard LA. Low-level exercise echocardiography detects contractile reserve and predicts reversible dysfunction after acute myocardial infarction: comparison with low-dose dobutamine echocardiography. *J Am Coll Cardiol* 1999;34:989-97.
- Haghani K, Shapiro S, Ginzton LE. Low-level exercise echocardiography identifies contractile reserve in patients with a recent myocardial infarction: comparison with dobutamine stress echocardiography. *J Am Soc Echocardiogr* 2002;15:671-7.
- Lancellotti P, Hoffer EP, Pierard LA. Detection and clinical usefulness of a biphasic response during exercise echocardiography early after myocardial infarction. *J Am Coll Cardiol* 2003;41:1142-7.
- Bax JJ, Poldermans D, Elhendy A, Boersma E, Rahimtoola SH. Sensitivity, specificity, and predictive accuracies of various noninvasive techniques for detecting hibernating myocardium. *Curr Probl Cardiol* 2001;26:147-81.
- Burgess MI, Jenkins C, Sharman JE, Marwick TH. Diastolic stress echocardiography: hemodynamic validation and clinical significance of estimation of ventricular filling pressure with exercise. *J Am Coll Cardiol* 2006;47:1891-900.

24. Ha JW, Oh JK, Pellikka PA, Ommen SR, Stussy VL, Bailey KR, et al. Diastolic stress echocardiography: a novel noninvasive diagnostic test for diastolic dysfunction using supine bicycle exercise Doppler echocardiography. *J Am Soc Echocardiogr* 2005;18:63-8.
25. Nagueh SF, Smiseth OA, Appleton CP, Byrd BF 3rd, Dokainish H, Edvardsen T, et al. Recommendations for the evaluation of left ventricular diastolic function by echocardiography: an update from the American Society of Echocardiography and the European Association of Cardiovascular Imaging. *J Am Soc Echocardiogr* 2016;29:277-314.
26. Choi EY, Shim CY, Kim SA, Rhee SJ, Choi D, Rim SJ, et al. Passive leg-raise is helpful to identify impaired diastolic functional reserve during exercise in patients with abnormal myocardial relaxation. *J Am Soc Echocardiogr* 2010;23:523-30.
27. Kane GC, Hepinstall MJ, Kidd GM, Kuehl CA, Murphy AT, Nelson JM, et al. Safety of stress echocardiography supervised by registered nurses: results of a 2-year audit of 15,404 patients. *J Am Soc Echocardiogr* 2008;21:337-41.
28. Modesto KM, Moller JE, Freeman WK, Shub C, Bailey KR, Pellikka PA. Safety of exercise stress testing in patients with abnormal concentrations of serum potassium. *Am J Cardiol* 2006;97:1247-9.
29. Sawada SG, Segar DS, Ryan T, Brown SE, Dohan AM, Williams R, et al. Echocardiographic detection of coronary artery disease during dobutamine infusion. *Circulation* 1991;83:1605-14.
30. Pellikka PA, Roger VL, Oh JK, Miller FA, Seward JB, Tajik AJ. Stress echocardiography. Part II. Dobutamine stress echocardiography: techniques, implementation, clinical applications, and correlations. *Mayo Clin Proc* 1995;70:16-27.
31. Ling LH, Christian TF, Mulvagh SL, Klarich KW, Hauser MF, Nishimura RA, et al. Determining myocardial viability in chronic ischemic left ventricular dysfunction: a prospective comparison of redistribution thallium 201 single-photon emission computed tomography, nitroglycerin-dobutamine echocardiography, and intracoronary myocardial contrast echocardiography. *Am Heart J* 2006;151:882-9.
32. Ling LH, Pellikka PA, Mahoney DW, Oh JK, McCully RB, Roger VL, et al. Atropine augmentation in dobutamine stress echocardiography: role and incremental value in a clinical practice setting. *J Am Coll Cardiol* 1996;28:551-7.
33. Wuthiwaropas P, Wiste JA, McCully RB, Kane GC, Scott CG, Pellikka PA. Neuropsychiatric symptoms during 24 hours after dobutamine-atropine stress testing: a prospective study in 1,006 patients. *J Am Soc Echocardiogr* 2011;24:367-73.
34. Burger AJ, Notarianni MP, Aronson D. Safety and efficacy of an accelerated dobutamine stress echocardiography protocol in the evaluation of coronary artery disease. *Am J Cardiol* 2000;86:825-9.
35. Lewandowski TJ, Armstrong WF, Bach DS. Reduced test time by early identification of patients requiring atropine during dobutamine stress echocardiography. *J Am Soc Echocardiogr* 1998;11:236-42.
36. Mathias W Jr, Tsutsui JM, Andrade JL, Kowatsch I, Lemos PA, Leal SM, et al. Value of rapid beta-blocker injection at peak dobutamine-atropine stress echocardiography for detection of coronary artery disease. *J Am Coll Cardiol* 2003;41:1583-9.
37. Sheldon SH, Askew JW 3rd, Klarich KW, Scott CG, Pellikka PA, McCully RB. Occurrence of atrial fibrillation during dobutamine stress echocardiography: incidence, risk factors, and outcomes. *J Am Soc Echocardiogr* 2011;24:86-90.
38. Picano E, Lattanzi F. Dipyridamole echocardiography. A new diagnostic window on coronary artery disease. *Circulation* 1991;83(suppl 5): III19-26.
39. Weintraub WS, Hattori S, Agarwal JB, Bodenheimer MM, Banka VS, Helfant RH. The relationship between myocardial blood flow and contraction by myocardial layer in the canine left ventricle during ischemia. *Circ Res* 1981;48:430-8.
40. Bache RJ, Schwartz JS. Effect of perfusion pressure distal to a coronary stenosis on transmural myocardial blood flow. *Circulation* 1982;65: 928-35.
41. Pislaru C, Belohlavek M, Bae RY, Abraham TP, Greenleaf JF, Seward JB. Regional asynchrony during acute myocardial ischemia quantified by ultrasound strain rate imaging. *J Am Coll Cardiol* 2001;37:1141-8.
42. Sutherland GR, Kukulski T, Kvitting JE, D'Hooge J, Arnold M, Brandt E, et al. Quantitation of left-ventricular asynergy by cardiac ultrasound. *Am J Cardiol* 2000;86:4G-9G.
43. Kvitting JP, Wigstrom L, Strotmann JM, Sutherland GR. How accurate is visual assessment of synchronicity in myocardial motion? An in vitro study with computer-simulated regional delay in myocardial motion: clinical implications for rest and stress echocardiography studies. *J Am Soc Echocardiogr* 1999;12:698-705.
44. Hoffmann R, Marwick TH, Poldermans D, Lethen H, Ciani R, van der Meer P, et al. Refinements in stress echocardiographic techniques improve inter-institutional agreement in interpretation of dobutamine stress echocardiograms. *Eur Heart J* 2002;23:821-9.
45. Holman BL, Wynne J, Idoine J, Neill J. Disruption in the temporal sequence of regional ventricular contraction. I. Characteristics and incidence in coronary artery disease. *Circulation* 1980;61:1075-83.
46. Johnson LL, Ellis K, Schmidt D, Weiss MB, Cannon PJ. Volume ejected in early systole. A sensitive index of left ventricular performance in coronary artery disease. *Circulation* 1975;52:378-89.
47. Lang RM, Bierig M, Devereux RB, Flachskampf FA, Foster E, Pellikka PA, et al. Recommendations for chamber quantification: a report from the American Society of Echocardiography's guidelines and Standards Committee and the Chamber quantification Writing group, developed in conjunction with the European Association of echocardiography, a branch of the European Society of Cardiology. *J Am Soc Echocardiogr* 2005;18:1440-63.
48. Lang RM, Badano LP, Mor-Avi V, Afilalo J, Armstrong A, Ernande L, et al. Recommendations for cardiac chamber quantification by echocardiography in adults: an update from the American Society of echocardiography and the European Association of Cardiovascular imaging. *J Am Soc Echocardiogr* 2015;28:1-39 e14.
49. Meizlish JL, Berger HJ, Plankey M, Errico D, Levy W, Zaret BL. Functional left ventricular aneurysm formation after acute anterior transmural myocardial infarction. *N Engl J Med* 1984;311:1001-6.
50. Rasmussen S, Corya BC, Feigenbaum H, Knoebel SB. Detection of myocardial scar tissue by M-mode echocardiography. *Circulation* 1978;57:230-7.
51. Sawada SG, Safadi A, Gaitonde RS, Tung N, Mahenthiran J, Gill W, et al. Stress-induced wall motion abnormalities with low-dose dobutamine infusion indicate the presence of severe disease and vulnerable myocardium. *Echocardiography* 2007;24:739-44.
52. Senior R, Lahiri A. Enhanced detection of myocardial ischemia by stress dobutamine echocardiography utilizing the "biphasic" response of wall thickening during low and high dose dobutamine infusion. *J Am Coll Cardiol* 1995;26:26-32.
53. Park TH, Tayan N, Takeda K, Jeon HK, Quinones MA, Zoghbi WA. Supine bicycle echocardiography improved diagnostic accuracy and physiologic assessment of coronary artery disease with the incorporation of intermediate stages of exercise. *J Am Coll Cardiol* 2007;50:1857-63.
54. Robertson WS, Feigenbaum H, Armstrong WF, Dillon JC, O'Donnell J, McHenry PW. Exercise echocardiography: a clinically practical addition in the evaluation of coronary artery disease. *J Am Coll Cardiol* 1983;2: 1085-91.
55. Tsoukas A, Ikonomidis I, Cokkinos P, Nihoyannopoulos P. Significance of persistent left ventricular dysfunction during recovery after dobutamine stress echocardiography. *J Am Coll Cardiol* 1997;30:621-6.
56. Rudski LG, Lai WW, Afilalo J, Hua L, Handschumacher MD, Chandrasekaran K, et al. Guidelines for the echocardiographic assessment of the right heart in adults: a report from the American Society of echocardiography endorsed by the European Association of echocardiography, a registered branch of the European Society of Cardiology, and the Canadian Society of echocardiography. *J Am Soc Echocardiogr* 2010;23:685-713.

57. Rambaldi R, Poldermans D, Fioretti PM, ten Cate FJ, Vletter WB, Bax JJ, et al. Usefulness of pulse-wave Doppler tissue sampling and dobutamine stress echocardiography for the diagnosis of right coronary artery narrowing. *Am J Cardiol* 1998;81:1411-5.
58. San Roman JA, Vilacosta I, Rollan MJ, Castillo JA, Alonso J, Duran JM, et al. Right ventricular asynergy during dobutamine-atropine echocardiography. *J Am Coll Cardiol* 1997;30:430-5.
59. O'Sullivan CA, Duncan A, Daly C, Li W, Oldershaw P, Henein MY. Dobutamine stress-induced ischemic right ventricular dysfunction and its relation to cardiac output in patients with three-vessel coronary artery disease with angina-like symptoms. *Am J Cardiol* 2005;96:622-7.
60. Arsenault M, Crete M, Bergeron S. Left ventricular shape assessment: a new simple diagnostic tool in stress echocardiography. *J Am Soc Echocardiogr* 2002;15:1321-5.
61. Attenhofer CH, Pellikka PA, Oh JK, Roger VL, Sohn DW, Seward JB. Comparison of ischemic response during exercise and dobutamine echocardiography in patients with left main coronary artery disease. *J Am Coll Cardiol* 1996;27:1171-7.
62. Carstensen S, Ali SM, Stensgaard-Hansen FV, Toft J, Haunso S, Kelbaek H, et al. Dobutamine-atropine stress echocardiography in asymptomatic healthy individuals. The relativity of stress-induced hyperkinesia. *Circulation* 1995;92:3453-63.
63. Coletta C, Galati A, Ricci R, Sestili A, Guagnozzi G, Re F, et al. Prognostic value of left ventricular volume response during dobutamine stress echocardiography. *Eur Heart J* 1997;18:1599-605.
64. Freeman MR, Berman DS, Staniloff H, Elkayam U, Maddahi J, Swan HJ, et al. Comparison of upright and supine bicycle exercise in the detection and evaluation of extent of coronary artery disease by equilibrium radionuclide ventriculography. *Am Heart J* 1981;102:182-9.
65. Ginzton LE, Conant R, Brizendine M, Lee F, Mena I, Laks MM. Exercise substotal two-dimensional echocardiography: a new method of segmental wall motion analysis. *Am J Cardiol* 1984;53:805-11.
66. Klein HO, Ninio R, Eliyahu S, Bakst A, Levi A, Dean H, et al. Effects of the dipyridamole test on left ventricular function in coronary artery disease. *Am J Cardiol* 1992;69:482-8.
67. Labovitz AJ, Pearson AC, Chaitman BR. Doppler and two-dimensional echocardiographic assessment of left ventricular function before and after intravenous dipyridamole stress testing for detection of coronary artery disease. *Am J Cardiol* 1988;62:1180-5.
68. Poliner LR, Dehmer GJ, Lewis SE, Parkey RW, Blomqvist CG, Willerson JT. Left ventricular performance in normal subjects: a comparison of the responses to exercise in the upright and supine positions. *Circulation* 1980;62:528-34.
69. Sochor H, Pachinger O, Ogris E, Probst P, Kaindl F. Radionuclide imaging after coronary vasodilation: myocardial scintigraphy with thallium-201 and radionuclide angiography after administration of dipyridamole. *Eur Heart J* 1984;5:500-9.
70. Zwehl W, Gueret P, Meerbaum S, Holt D, Corday E. Quantitative two dimensional echocardiography during bicycle exercise in normal subjects. *Am J Cardiol* 1981;47:866-73.
71. Lee CY, Pellikka PA, McCully RB, Mahoney DW, Seward JB. Nonexercise stress transthoracic echocardiography: transesophageal atrial pacing versus dobutamine stress. *J Am Coll Cardiol* 1999;33:506-11.
72. Rainbird AJ, Pellikka PA, Stussy VL, Mahoney DM, Seward JB. A rapid stress-testing protocol for the detection of coronary artery disease: comparison of two-stage transesophageal atrial pacing stress echocardiography with dobutamine stress echocardiography. *J Am Coll Cardiol* 2000;36:1659-63.
73. Anselmi M, Golia G, Marino P, Vitolo A, Rossi A, Caraffi G, et al. Comparison of left ventricular function and volumes during transesophageal atrial pacing combined with two-dimensional echocardiography in patients with syndrome X, atherosclerotic coronary artery disease, and normal subjects. *Am J Cardiol* 1997;80:1261-5.
74. Olson C, Porter T, Deligonul U, Xie F, Anderson J. Prognostic value of left ventricular volume response during dobutamine stress echocardiography. *J Am Coll Cardiol* 1994;24:1268-73.
75. Arnese M, Fioretti PM, Cornel JH, Postma-Tjoa J, Reijts AE, Roelandt JR. Akinesis becoming dyskinesia during high-dose dobutamine stress echocardiography: a marker of myocardial ischemia or a mechanical phenomenon? *Am J Cardiol* 1994;73:896-9.
76. Elhendy A, Cornel JH, Roelandt JR, van Domburg RT, Nierop PR, Geleynse ML, et al. Relation between contractile response of akinetic segments during dobutamine stress echocardiography and myocardial ischemia assessed by simultaneous thallium-201 single-photon emission computed tomography. *Am J Cardiol* 1996;77:955-9.
77. Bourque JM, Beller GA. Stress myocardial perfusion imaging for assessing prognosis: an update. *JACC Cardiovasc Imaging* 2011;4:1305-19.
78. Berrington de Gonzalez A, Kim KP, Smith-Bindman R, McAreavey D. Myocardial perfusion scans: projected population cancer risks from current levels of use in the United States. *Circulation* 2010;122:2403-10.
79. Einstein AJ, Weiner SD, Bernheim A, Kulon M, Bokhari S, Johnson LL, et al. Multiple testing, cumulative radiation dose, and clinical indications in patients undergoing myocardial perfusion imaging. *JAMA* 2010;304:2137-44.
80. Wei K, Le E, Bin JP, Coggins M, Jayawera AR, Kaul S. Mechanism of reversible (99m)Tc-sestamibi perfusion defects during pharmacologically induced vasodilatation. *Am J Physiol Heart Circ Physiol* 2001;280:H1896-904.
81. Porter TR, Xie F, Silver M, Kricsfeld D, O'Leary E. Real-time perfusion imaging with low mechanical index pulse inversion Doppler imaging. *J Am Coll Cardiol* 2001;37:748-53.
82. Elhendy A, O'Leary EL, Xie F, McGrain AC, Anderson JR, Porter TR. Comparative accuracy of real-time myocardial contrast perfusion imaging and wall motion analysis during dobutamine stress echocardiography for the diagnosis of coronary artery disease. *J Am Coll Cardiol* 2004;44:2185-91.
83. Xie F, Tsutsui JM, McGrain AC, Demaria A, Cotter B, Becher H, et al. Comparison of dobutamine stress echocardiography with and without real-time perfusion imaging for detection of coronary artery disease. *Am J Cardiol* 2005;96:506-11.
84. Tsutsui JM, Elhendy A, Anderson JR, Xie F, McGrain AC, Porter TR. Prognostic value of dobutamine stress myocardial contrast perfusion echocardiography. *Circulation* 2005;112:1444-50.
85. Peltier M, Vancaeraynest D, Pasquet A, Ay T, Roelants V, D'Hondt AM, et al. Assessment of the physiologic significance of coronary disease with dipyridamole real-time myocardial contrast echocardiography. Comparison with technetium-99m sestamibi single-photon emission computed tomography and quantitative coronary angiography. *J Am Coll Cardiol* 2004;43:257-64.
86. Shimoni S, Zoghbi WA, Xie F, Kricsfeld D, Iskander S, Gobar L, et al. Real-time assessment of myocardial perfusion and wall motion during bicycle and treadmill exercise echocardiography: comparison with single photon emission computed tomography. *J Am Coll Cardiol* 2001;37:741-7.
87. Dawson D, Kaul S, Peters D, Rinkevich D, Schnell G, Belcic JT, et al. Prognostic value of dipyridamole stress myocardial contrast echocardiography: comparison with single photon emission computed tomography. *J Am Soc Echocardiogr* 2009;22:954-60.
88. el-Said ES, Roelandt JR, Fioretti PM, McNeill AJ, Forster T, Boersma H, et al. Abnormal left ventricular early diastolic filling during dobutamine stress Doppler echocardiography is a sensitive indicator of significant coronary artery disease. *J Am Coll Cardiol* 1994;24:1618-24.
89. Presti CF, Walling AD, Montemayor I, Campbell JM, Crawford MH. Influence of exercise-induced myocardial ischemia on the pattern of left ventricular diastolic filling: a Doppler echocardiographic study. *J Am Coll Cardiol* 1991;18:75-82.
90. Peteiro J, Pazos P, Bouzas A, Pinon P, Estevez R, Castro-Beiras A. Assessment of diastolic function during exercise echocardiography: annulus mitral velocity or transmitral flow pattern? *J Am Soc Echocardiogr* 2008;21:178-84.

91. Koch R, Lang RM, Garcia MJ, Weinert L, Bednarz J, Korcarz C, et al. Objective evaluation of regional left ventricular wall motion during dobutamine stress echocardiographic studies using segmental analysis of color kinesis images. *J Am Coll Cardiol* 1999;34:409-19.
92. Takeuchi M, Yoshitani H, Miyazaki C, Haruki N, Otani S, Sakamoto K, et al. Color kinesis during contrast-enhanced dobutamine stress echocardiography: feasibility and applicability. *Circ J* 2003;67:49-53.
93. Cain P, Baglin T, Case C, Spicer D, Short L, Marwick TH. Application of tissue Doppler to interpretation of dobutamine echocardiography and comparison with quantitative coronary angiography. *Am J Cardiol* 2001;87:525-31.
94. Celutkienė J, Sutherland GR, Laucevicius A, Zakarkaite D, Rudys A, Grabauskiene V. Is post-systolic motion the optimal ultrasound parameter to detect induced ischaemia during dobutamine stress echocardiography? *Eur Heart J* 2004;25:932-42.
95. Pauliks LB, Vogel M, Madler CF, Williams RI, Payne N, Redington AN, et al. Regional response of myocardial acceleration during isovolumic contraction during dobutamine stress echocardiography: a color tissue Doppler study and comparison with angiographic findings. *Echocardiography* 2005;22:797-808.
96. von Bibra H, Tchnitz A, Klein A, Schneider-Eicke J, Schomig A, Schwaiger M. Regional diastolic function by pulsed Doppler myocardial mapping for the detection of left ventricular ischemia during pharmacologic stress testing: a comparison with stress echocardiography and perfusion scintigraphy. *J Am Coll Cardiol* 2000;36:444-52.
97. Madler CF, Payne N, Wilkeshoff U, Cohen A, Derumeaux GA, Pierard LA, et al. Non-invasive diagnosis of coronary artery disease by quantitative stress echocardiography: optimal diagnostic models using off-line tissue Doppler in the MYDISE study. *Eur Heart J* 2003;24:1584-94.
98. Sharma R, Mehta RL, Brecker SJ, Gaze DC, Gregson H, Streather CP, et al. The diagnostic and prognostic value of tissue Doppler imaging during dobutamine stress echocardiography in end-stage renal disease. *Coron Artery Dis* 2009;20:230-7.
99. Pislaru C, Abraham TP, Belohlavek M. Strain and strain rate echocardiography. *Curr Opin Cardiol* 2002;17:443-54.
100. Abraham TP, Belohlavek M, Thomson HL, Pislaru C, Khandheria B, Seward JB, et al. Time to onset of regional relaxation: feasibility, variability and utility of a novel index of regional myocardial function by strain rate imaging. *J Am Coll Cardiol* 2002;39:1531-7.
101. Hanekom L, Jenkins C, Jeffries L, Case C, Mundy J, Hawley C, et al. Incremental value of strain rate analysis as an adjunct to wall-motion scoring for assessment of myocardial viability by dobutamine echocardiography: a follow-up study after revascularization. *Circulation* 2005;112:3892-900.
102. Voigt JU, Exner B, Schmiedehausen K, Huchzermeyer C, Reulbach U, Nixdorff U, et al. Strain-rate imaging during dobutamine stress echocardiography provides objective evidence of inducible ischemia. *Circulation* 2003;107:2120-6.
103. Weidemann F, Jung P, Hoyer C, Broscheit J, Voelker W, Ertl G, et al. Assessment of the contractile reserve in patients with intermediate coronary lesions: a strain rate imaging study validated by invasive myocardial fractional flow reserve. *Eur Heart J* 2007;28:1425-32.
104. Celutkienė J, Zakarkaite D, Skorniakov V, Zvironaite V, Grabauskiene V, Burca J, et al. Quantitative approach using multiple single parameters versus visual assessment in dobutamine stress echocardiography. *Cardiovasc Ultrasound* 2012;10:31.
105. Al Suwaidi J, Velianou JL, Gertz MA, Cannon RO 3rd, Higano ST, Holmes DR Jr, et al. Systemic amyloidosis presenting with angina pectoris. *Ann Intern Med* 1999;131:838-41.
106. Mastouri R, Mahenthiran J, Kamalesh M, Gradus-Pizlo I, Feigenbaum H, Sawada SG. Prediction of ischemic events by anatomic M-mode strain rate stress echocardiography. *J Am Soc Echocardiogr* 2008;21:299-306.
107. Voigt J, Nixdorff U, Bogdan R, Exner B, Schmiedehausen K, Platsch G, et al. Comparison of deformation imaging and velocity imaging for detecting regional inducible ischaemia during dobutamine stress echocardiography. *Eur Heart J* 2004;25:1517-25.
108. Reant P, Labrousse L, Lafitte S, Bordachar P, Pillois X, Tariosse L, et al. Experimental validation of circumferential, longitudinal, and radial 2-dimensional strain during dobutamine stress echocardiography in ischemic conditions. *J Am Coll Cardiol* 2008;51:149-57.
109. Sawada SG. Stressing the limits of strain echocardiography. *J Am Soc Echocardiogr* 2015;28:1390-2.
110. Yu Y, Villarraga HR, Saleh HK, Cha SS, Pellikka PA. Can ischemia and dyssynchrony be detected during early stages of dobutamine stress echocardiography by 2-dimensional speckle-tracking echocardiography? *Int J Cardiovasc Imaging* 2013;29:95-102.
111. Hanekom L, Cho GY, Leano R, Jeffries L, Marwick TH. Comparison of two-dimensional speckle and tissue Doppler strain measurement during dobutamine stress echocardiography: an angiographic correlation. *Eur Heart J* 2007;28:1765-72.
112. Ingul CB, Stoylen A, Slordahl SA, Wiseth R, Burgess M, Marwick TH. Automated analysis of myocardial deformation at dobutamine stress echocardiography: an angiographic validation. *J Am Coll Cardiol* 2007;49:1651-9.
113. Rumbinaite E, Zaliaduonyte-Peksiene D, Lapinskas T, Zvirblyte R, Karuzas A, Jonauskiene I, et al. Early and late diastolic strain rate vs global longitudinal strain at rest and during dobutamine stress for the assessment of significant coronary artery stenosis in patients with a moderate and high probability of coronary artery disease. *Echocardiography* 2016;33:1512-22.
114. Uusitalo V, Luotolahti M, Pietila M, Wendelin-Saarenhovi M, Hartiala J, Saraste M, et al. Two-dimensional speckle-tracking during dobutamine stress echocardiography in the detection of myocardial ischemia in patients with suspected coronary artery disease. *J Am Soc Echocardiogr* 2016;29:470-9.e3.
115. Aggeli C, Lagoudakou S, Felekos I, Panagopoulou V, Kastellanos S, Toutouzas K, et al. Two-dimensional speckle-tracking for the assessment of coronary artery disease during dobutamine stress echo: clinical tool or merely research method. *Cardiovasc Ultrasound* 2015;13:43.
116. Ng AC, Sitges M, Pham PN, Tran da T, Delgado V, Bertini M, et al. Incremental value of 2-dimensional speckle-tracking strain imaging to wall motion analysis for detection of coronary artery disease in patients undergoing dobutamine stress echocardiography. *Am Heart J* 2009;158:836-44.
117. Donal E, Bergerot C, Thibault H, Ernande L, Loufoua J, Augeul L, et al. Influence of afterload on left ventricular radial and longitudinal systolic functions: a two-dimensional strain imaging study. *Eur J Echocardiogr* 2009;10:914-21.
118. Rhea IB, Rehman S, Jarori U, Choudhry MW, Feigenbaum H, Sawada SG. Prognostic utility of blood pressure-adjusted global and basal systolic longitudinal strain. *Echo Res Pract* 2016;3:17-24.
119. Fleischmann K, Hunink M, Kuntz K, Douglas P. Exercise echocardiography or exercise SPECT imaging? A meta-analysis of diagnostic test performance. *JAMA* 1998;280:913-20.
120. Mahajan N, Polavaram L, Vankayala H, Ference B, Wang Y, Ager J, et al. Diagnostic accuracy of myocardial perfusion imaging and stress echocardiography for the diagnosis of left main and triple vessel coronary artery disease: a comparative meta-analysis. *Heart* 2010;96:956-66.
121. Picano E, Molinaro S, Pasanisi E. The diagnostic accuracy of pharmacological stress echocardiography for the assessment of coronary artery disease: a meta-analysis. *Cardiovasc Ultrasound* 2008;6:30.
122. Abram S, Arruda-Olson AM, Scott CG, Pellikka PA, Nkomo VT, Oh JK, et al. Typical blood pressure response during dobutamine stress echocardiography of patients without known cardiovascular disease who have normal stress echocardiograms. *Eur Heart J Cardiovasc Imaging* 2015;17:557-63.
123. Jurens T, From A, Kane G, Mulvagh S, Pellikka P, McCully R. An exaggerated blood pressure response to treadmill exercise does not increase the likelihood that exercise echocardiograms are abnormal in men or women. *J Am Soc Echocardiogr* 2012;25:1113-9.
124. Ha J, Juracan E, Mahoney D, Oh J, Shub C, Seward J, et al. Hypertensive response to exercise: a potential cause for new wall motion abnormality in the absence of coronary artery disease. *J Am Coll Cardiol* 2002;39:323-7.

125. From AM, Kane G, Bruce C, Pellikka PA, Scott C, McCully RB. Characteristics and outcomes of patients with abnormal stress echocardiograms and angiographically mild coronary artery disease (<50% stenoses) or normal coronary arteries. *J Am Soc Echocardiogr* 2010;23:207-14.
126. Abram SMD, Arruda-Olson AMMDP, Scott CGMS, Pellikka PAMD, Nkomo VTMD, Oh JKMD, et al. Frequency, predictors, and implications of abnormal blood pressure responses during dobutamine stress echocardiography. *Circ Cardiovasc Imaging* 2017;10:e005444.
127. Dorbala S, Vangala D, Bruyere J Jr, Quarta C, Kruger J, Padera R, et al. Coronary microvascular dysfunction is related to abnormalities in myocardial structure and function in cardiac amyloidosis. *JACC Heart Fail* 2014;2:358-67.
128. From AM, Prasad A, Pellikka PA, McCully RB. Are some false-positive stress echocardiograms a forme fruste variety of apical ballooning syndrome? *Am J Cardiol* 2009;103:1434-8.
129. Patel SM, Lerman A, Lennon RJ, Prasad A. Impaired coronary microvascular reactivity in women with apical ballooning syndrome (Takotsubo/stress cardiomyopathy). *Eur Heart J Acute Cardiovasc Care* 2013;2:147-52.
130. Anakwenze OA, Lerman A, Edwards WD, Gertz MA, Rihal CS. Death during coronary angiography in a woman with cardiac amyloidosis. *Amyloid* 2006;13:108-10.
131. Abdelmoneim SS, Dhoble A, Bernier M, Erwin PJ, Korosoglou G, Senior R, et al. Quantitative myocardial contrast echocardiography during pharmacological stress for diagnosis of coronary artery disease: a systematic review and meta-analysis of diagnostic accuracy studies. *Eur J Echocardiogr* 2009;10:813-25.
132. Arnold JR, Karamitsos TD, Pegg TJ, Francis JM, Olszewski R, Searle N, et al. Adenosine stress myocardial contrast echocardiography for the detection of coronary artery disease: a comparison with coronary angiography and cardiac magnetic resonance. *JACC Cardiovasc Imaging* 2010;3:934-43.
133. Elhendy A, Tsutsui JM, O'Leary EL, Xie F, Porter TR. Noninvasive diagnosis of coronary artery bypass graft disease by dobutamine stress real-time myocardial contrast perfusion imaging. *J Am Soc Echocardiogr* 2006;19:1482-7.
134. Elhendy A, Tsutsui JM, O'Leary EL, Xie F, McGrain AC, Porter TR. Noninvasive diagnosis of coronary artery disease in patients with diabetes by dobutamine stress real-time myocardial contrast perfusion imaging. *Diabetes Care* 2005;28:1662-7.
135. Gaibazzi N, Reverberi C, Lorenzoni V, Molinaro S, Porter TR. Prognostic value of high-dose dipyridamole stress myocardial contrast perfusion echocardiography. *Circulation* 2012;126:1217-24.
136. Gaibazzi N, Rigo F, Squeri A, Ugo F, Reverberi C. Incremental value of contrast myocardial perfusion to detect intermediate versus severe coronary artery stenosis during stress-echocardiography. *Cardiovasc Ultrasound* 2010;8:16.
137. Gudmundsson P, Shahgaldi K, Winter R, Dencker M, Kitlinski M, Thorsson O, et al. Head to head comparisons of two modalities of perfusion adenosine stress echocardiography with simultaneous SPECT. *Cardiovasc Ultrasound* 2009;7:19.
138. Hayat SA, Dwivedi G, Jacobsen A, Lim TK, Kinsey C, Senior R. Effects of left bundle-branch block on cardiac structure, function, perfusion, and perfusion reserve: implications for myocardial contrast echocardiography versus radionuclide perfusion imaging for the detection of coronary artery disease. *Circulation* 2008;117:1832-41.
139. Jeetley P, Hickman M, Kamp O, Lang RM, Thomas JD, Vannan MA, et al. Myocardial contrast echocardiography for the detection of coronary artery stenosis: a prospective multicenter study in comparison with single-photon emission computed tomography. *J Am Coll Cardiol* 2006;47:141-5.
140. Leong-Poi H, Le E, Rim SJ, Sakuma T, Kaul S, Wei K. Quantification of myocardial perfusion and determination of coronary stenosis severity during hyperemia using real-time myocardial contrast echocardiography. *J Am Soc Echocardiogr* 2001;14:1173-82.
141. Miszalski-Jamka T, Kuntz-Hehner S, Schmidt H, Peter D, Miszalski-Jamka K, Hammerstingl C, et al. Myocardial contrast echocardiography enhances long-term prognostic value of supine bicycle stress two-dimensional echocardiography. *J Am Soc Echocardiogr* 2009;22:1220-7.
142. Porter TR, Adolphson M, High RR, Smith LM, Olson J, Erdkamp M, et al. Rapid detection of coronary artery stenoses with real-time perfusion echocardiography during regadenoson stress. *Circ Cardiovasc Imaging* 2011;4:628-35.
143. Porter TR, Smith LM, Wu J, Thomas D, Haas JT, Mathers DH, et al. Patient outcome following 2 different stress imaging approaches: a prospective randomized comparison. *J Am Coll Cardiol* 2013;61:2446-55.
144. Senior R, Monaghan M, Main ML, Zamorano JL, Tiemann K, Agati L, et al. Detection of coronary artery disease with perfusion stress echocardiography using a novel ultrasound imaging agent: two Phase 3 international trials in comparison with radionuclide perfusion imaging. *Eur J Echocardiogr* 2009;10:26-35.
145. Senior R, Moreo A, Gaibazzi N, Agati L, Tiemann K, Shivalkar B, et al. Comparison of sulfur hexafluoride microbubble (SonoVue)-enhanced myocardial contrast echocardiography with gated single-photon emission computed tomography for detection of significant coronary artery disease: a large European multicenter study. *J Am Coll Cardiol* 2013;62:1353-61.
146. Toledo E, Jacobs LD, Lodato JA, DeCara JM, Coon P, Mor-Avi V, et al. Quantitative diagnosis of stress-induced myocardial ischemia using analysis of contrast echocardiographic parametric perfusion images. *Eur J Echocardiogr* 2006;7:217-25.
147. Wei K, Crouse L, Weiss J, Villanueva F, Schiller NB, Naqvi TZ, et al. Comparison of usefulness of dipyridamole stress myocardial contrast echocardiography to technetium-99m sestamibi single-photon emission computed tomography for detection of coronary artery disease (PB127 Multicenter Phase 2 Trial results). *Am J Cardiol* 2003;91:1293-8.
148. Xie F, Dodla S, O'Leary E, Porter TR. Detection of subendocardial ischemia in the left anterior descending coronary artery territory with real-time myocardial contrast echocardiography during dobutamine stress echocardiography. *JACC Cardiovasc Imaging* 2008;1:271-8.
149. Xie F, Hankins J, Mahrous HA, Porter TR. Detection of coronary artery disease with a continuous infusion of definity ultrasound contrast during adenosine stress real time perfusion echocardiography. *Echocardiography* 2007;24:1044-50.
150. Abdelmoneim SS, Dhoble A, Bernier M, Moir S, Hagen ME, Ness SA, et al. Absolute myocardial blood flow determination using real-time myocardial contrast echocardiography during adenosine stress: comparison with single-photon emission computed tomography. *Heart* 2009;95:1662-8.
151. Felis S, Deste W, Colonna P, Ragusa A, Scandura S, Giannotta D, et al. Myocardial contrast echocardiography in the evaluation of myocardial perfusion in patients with left bundle branch block and coronary artery disease. *Ital Heart J* 2005;6:956-61.
152. Gaibazzi N, Rigo F, Reverberi C. Detection of coronary artery disease by combined assessment of wall motion, myocardial perfusion and coronary flow reserve: a multiparametric contrast stress-echocardiography study. *J Am Soc Echocardiogr* 2010;23:1242-50.
153. Janardhanan R, Senior R. Accuracy of dipyridamole myocardial contrast echocardiography for the detection of residual stenosis of the infarct-related artery and multivessel disease early after acute myocardial infarction. *J Am Coll Cardiol* 2004;43:2247-52.
154. Korosoglou G, Dubart AE, DaSilva KG Jr, Labadze N, Hardt S, Hansen A, et al. Real-time myocardial perfusion imaging for pharmacologic stress testing: added value to single photon emission computed tomography. *Am Heart J* 2006;151:131-8.
155. Lipiec P, Wejner-Mik P, Krzeminska-Pakula M, Kusmierek J, Plachcinska A, Szuminski R, et al. Accelerated stress real-time myocardial contrast echocardiography for the detection of coronary artery disease: comparison with 99mTc single photon emission computed tomography. *J Am Soc Echocardiogr* 2008;21:941-7.
156. Malm S, Frigstad S, Torp H, Wiseth R, Skjarpe T. Quantitative adenosine real-time myocardial contrast echocardiography for detection of angiographically significant coronary artery disease. *J Am Soc Echocardiogr* 2006;19:365-72.

157. Mor-Avi V, Koch R, Holper EM, Goonewardena S, Coon PD, Min JK, et al. Value of vasodilator stress myocardial contrast echocardiography and magnetic resonance imaging for the differential diagnosis of ischemic versus nonischemic cardiomyopathy. *J Am Soc Echocardiogr* 2008;21:425-32.
158. Senior R, Janardhanan R, Jeetley P, Burden L. Myocardial contrast echocardiography for distinguishing ischemic from nonischemic first-onset acute heart failure: insights into the mechanism of acute heart failure. *Circulation* 2005;112:1587-93.
159. Gaibazzi N, Lorenzoni V, Reverberi C, Wu J, Xie F, Porter TR. Effect of pharmacologic stress test results on outcomes in obese versus nonobese subjects referred for stress perfusion echocardiography. *J Am Soc Echocardiogr* 2016;29:899-906.
160. Wu J, Barton D, Xie F, O'Leary E, Steuter J, Pavlides G, et al. Comparison of fractional flow reserve assessment with demand stress myocardial contrast echocardiography in angiographically intermediate coronary stenoses. *Circ Cardiovasc Imaging* 2016;9.
161. Wei K, Ragosta M, Thorpe J, Coggins M, Moos S, Kaul S. Noninvasive quantification of coronary blood flow reserve in humans using myocardial contrast echocardiography. *Circulation* 2001;103:2560-5.
162. Leong-Poi H, Rim SJ, Le DE, Fisher NG, Wei K, Kaul S. Perfusion versus function: the ischemic cascade in demand ischemia: implications of single-vessel versus multivessel stenosis. *Circulation* 2002;105:987-92.
163. Jayaweera AR, Wei K, Coggins M, Bin JP, Goodman C, Kaul S. Role of capillaries in determining CBF reserve: new insights using myocardial contrast echocardiography. *Am J Physiol* 1999;277(6 Pt 2):H2363-72.
164. Rigo F. Coronary flow reserve in stress-echo lab. From pathophysiologic toy to diagnostic tool. *Cardiovasc Ultrasound* 2005;3:8.
165. Hozumi T, Yoshida K, Ogata Y, Akasaka T, Asami Y, Takagi T, et al. Noninvasive assessment of significant left anterior descending coronary artery stenosis by coronary flow velocity reserve with transthoracic color Doppler echocardiography. *Circulation* 1998;97:1557-62.
166. Caiati C, Montaldo C, Zedda N, Montisci R, Ruscazio M, Lai G, et al. Validation of a new noninvasive method (contrast-enhanced transthoracic second harmonic echo Doppler) for the evaluation of coronary flow reserve: comparison with intracoronary Doppler flow wire. *J Am Coll Cardiol* 1999;34:1193-200.
167. Lowenstein J, Tian C, Marquez G, Presti C, Quiroz C. Simultaneous analysis of wall motion and coronary flow reserve of the left anterior descending coronary artery by transthoracic Doppler echocardiography during dipyridamole stress echocardiography. *J Am Soc Echocardiogr* 2003;16:607-13.
168. Nohtomi Y, Takeuchi M, Nagasawa K, Arimura K, Miyata K, Kuwata K, et al. Simultaneous assessment of wall motion and coronary flow velocity in the left anterior descending coronary artery during dipyridamole stress echocardiography. *J Am Soc Echocardiogr* 2003;16:457-63.
169. Forte EH, Rousse MC, Lowenstein JA. Target heart rate to determine the normal value of coronary flow reserve during dobutamine stress echocardiography. *Cardiovasc Ultrasound* 2011;9:10.
170. Peteiro J, Pinon P, Perez R, Monserrat L, Perez D, Castro-Beiras A. Comparison of 2- and 3-dimensional exercise echocardiography for the detection of coronary artery disease. *J Am Soc Echocardiogr* 2007;20:959-67.
171. Yang H, Pellikka P, McCully R, Oh J, Kukuzke J, Khandheria B, et al. Role of biplane and biplane echocardiographically guided 3-dimensional echocardiography during dobutamine stress echocardiography. *J Am Soc Echocardiogr* 2006;19:1136-43.
172. Lang R, Badano L, Tsang W, Adams D, Agricola E, Buck T, et al. EAE/ASE Recommendations for image acquisition and display using three-dimensional echocardiography. *J Am Soc Echocardiogr* 2012;25:3-46.
173. Bates RE, Omer M, Abdelmoneim SS, Arruda-Olson AM, Scott CG, Bailey KR, et al. Impact of stress testing for coronary artery disease screening in asymptomatic patients with diabetes mellitus: a community-based study in Olmsted County, Minnesota. *Mayo Clin Proc* 2016;91:1535-44.
174. Yao SS, Qureshi E, Sherrid MV, Chaudhry FA. Practical applications in stress echocardiography: risk stratification and prognosis in patients with known or suspected ischemic heart disease. *J Am Coll Cardiol* 2003;42:1084-90.
175. Marwick TH, Case C, Sawada S, Rimmerman C, Brenneman P, Kovacs R, et al. Prediction of mortality using dobutamine echocardiography. *J Am Coll Cardiol* 2001;37:754-60.
176. Marwick TH, Case C, Vasey C, Allen S, Short L, Thomas JD. Prediction of mortality by exercise echocardiography: a strategy for combination with the Duke treadmill score. *Circulation* 2001;103:2566-71.
177. McCully RB, Roger VL, Mahoney DW, Karon BL, Oh JK, Miller FA Jr, et al. Outcome after normal exercise echocardiography and predictors of subsequent cardiac events: follow-up of 1,325 patients. *J Am Coll Cardiol* 1998;31:144-9.
178. Yao SS, Rozanski A. Principal uses of myocardial perfusion scintigraphy in the management of patients with known or suspected coronary artery disease. *Prog Cardiovasc Dis* 2001;43:281-302.
179. McCully RB, Ommen SR, Klarich KW, Burger KN, Mahoney DW, Pellikka PA. Prognosis of patients with good exercise capacity and mildly abnormal exercise echocardiography results: identification of an at-risk subgroup. *J Am Soc Echocardiogr* 2005;18:644-8.
180. McCully RB, Roger VL, Ommen SR, Mahoney DW, Burger KN, Freeman WK, et al. Outcomes of patients with reduced exercise capacity at time of exercise echocardiography. *Mayo Clin Proc* 2004;79:750-7.
181. Elhendy A, Mahoney DW, Khandheria BK, Burger K, Pellikka PA. Prognostic significance of impairment of heart rate response to exercise: impact of left ventricular function and myocardial ischemia. *J Am Coll Cardiol* 2003;42:823-30.
182. Chaowalit N, McCully RB, Callahan MJ, Mookadam F, Bailey KR, Pellikka PA. Outcomes after normal dobutamine stress echocardiography and predictors of adverse events: long-term follow-up of 3014 patients. *Eur Heart J* 2006;27:3039-44.
183. Chuah SC, Pellikka PA, Roger VL, McCully RB, Seward JB. Role of dobutamine stress echocardiography in predicting outcome in 860 patients with known or suspected coronary artery disease. *Circulation* 1998;97:1474-80.
184. Yao SS, Qureshi E, Syed A, Chaudhry FA. Novel stress echocardiographic model incorporating the extent and severity of wall motion abnormality for risk stratification and prognosis. *Am J Cardiol* 2004;94:715-9.
185. Arruda-Olson A, Juracan E, Mahoney D, McCully R, Roger V, Pellikka P. Prognostic value of exercise echocardiography in 5,798 patients: is there a gender difference? *J Am Coll Cardiol* 2002;39:625-31.
186. Ladenheim ML, Pollock BH, Rozanski A, Berman DS, Staniloff HM, Forrester JS, et al. Extent and severity of myocardial hypoperfusion as predictors of prognosis in patients with suspected coronary artery disease. *J Am Coll Cardiol* 1986;7:464-71.
187. Ghio S, Gavazzi A, Campana C, Inerra C, Klersy C, Sebastiani R, et al. Independent and additive prognostic value of right ventricular systolic function and pulmonary artery pressure in patients with chronic heart failure. *J Am Coll Cardiol* 2001;37:183-8.
188. Bangalore S, Yao SS, Chaudhry FA. Role of right ventricular wall motion abnormalities in risk stratification and prognosis of patients referred for stress echocardiography. *J Am Coll Cardiol* 2007;50:1981-9.
189. Rigolin VH, Robiolio PA, Wilson JS, Harrison JK, Bashore TM. The forgotten chamber: the importance of the right ventricle. *Cathet Cardiovasc Diagn* 1995;35:18-28.
190. Bergeron S, Ommen SR, Bailey KR, Oh JK, McCully RB, Pellikka PA. Exercise echocardiographic findings and outcome of patients referred for evaluation of dyspnea. *J Am Coll Cardiol* 2004;43:2242-6.
191. Bernheim AM, Kittipovanonth M, Scott CG, McCully RB, Tsang TS, Pellikka PA. Relation of dyspnea in patients unable to perform exercise stress testing to outcome and myocardial ischemia. *Am J Cardiol* 2009;104:265-9.
192. Grewal J, McCully RB, Kane GC, Lam C, Pellikka PA. Left ventricular function and exercise capacity. *JAMA* 2009;301:286-94.
193. Gharacholou SM, Scott CG, Takahashi PY, Nkomo VT, McCully RB, Fine NM, et al. Left ventricular diastolic function and long-term outcomes in patients with normal exercise echocardiographic findings. *Am J Cardiol* 2013;112:200-7.
194. Nakajima Y, Kane GC, McCully RB, Ommen SR, Pellikka PA. Left ventricular diastolic filling pressures during dobutamine stress

- echocardiography: relationship to symptoms and ischemia. *J Am Soc Echocardiogr* 2009;22:947-53.
195. Bangalore S, Yao SS, Chaudhry FA. Role of left atrial size in risk stratification and prognosis of patients undergoing stress echocardiography. *J Am Coll Cardiol* 2007;50:1254-62.
196. Kane GC, Sachdev A, Villarraga HR, Ammash NM, Oh JK, McGoon MD, et al. Impact of age on pulmonary artery systolic pressures at rest and with exercise. *Echo Res Pract* 2016;3:53-61.
197. Geleijnse ML, Vigna C, Kasprzak JD, Rambaldi R, Salvatori MP, Elhendy A, et al. Usefulness and limitations of dobutamine-atropine stress echocardiography for the diagnosis of coronary artery disease in patients with left bundle branch block. A multicentre study. *Eur Heart J* 2000;21:1666-73.
198. Cortigiani L, Picano E, Vigna C, Lattanzi F, Coletta C, Mariotti E, et al. Prognostic value of pharmacologic stress echocardiography in patients with left bundle branch block. *Am J Med* 2001;110:361-9.
199. Supariwala AA, Po JR, Mohareb S, Aslam F, Kaddaha F, Mian ZI, et al. Prevalence and long-term prognosis of patients with complete bundle branch block (right or left bundle branch) with normal left ventricular ejection fraction referred for stress echocardiography. *Echocardiography* 2015;32:483-9.
200. Biagini E, Shaw LJ, Poldermans D, Schinkel AF, Rizzello V, Elhendy A, et al. Accuracy of non-invasive techniques for diagnosis of coronary artery disease and prediction of cardiac events in patients with left bundle branch block: a meta-analysis. *Eur J Nucl Med Mol Imaging* 2006;33:1442-51.
201. Geleijnse M, Vigna C, Kasprzak J, Rambaldi R, Salvatori M, Elhendy A, et al. Usefulness and limitations of dobutamine-atropine stress echocardiography for the diagnosis of coronary artery disease in patients with left bundle branch block. *Eur Heart J* 2000;21:1666-73.
202. Shan Y, Villarraga HR, Pislaru C, Shah AA, Cha SS, Pellikka PA. Quantitative assessment of strain and strain rate by velocity vector imaging during dobutamine stress echocardiography to predict outcome in patients with left bundle branch block. *J Am Soc Echocardiogr* 2009;22:1212-9.
203. Vamvakidou A, Karogiannis N, Tzalamouras V, Parsons G, Young G, Gurunathan S, et al. Prognostic usefulness of contemporary stress echocardiography in patients with left bundle branch block and impact of contrast use in improving prediction of outcome. *Eur Heart J Cardiovasc Imaging* 2017;18:415-21.
204. Das MK, Pellikka PA, Mahoney DW, Roger VL, Oh JK, McCully RB, et al. Assessment of cardiac risk before nonvascular surgery: dobutamine stress echocardiography in 530 patients. *J Am Coll Cardiol* 2000;35:1647-53.
205. Kertai MD, Boersma E, Bax JJ, Heijnenbroek-Kal MH, Hunink MG, L'Talien GJ, et al. A meta-analysis comparing the prognostic accuracy of six diagnostic tests for predicting perioperative cardiac risk in patients undergoing major vascular surgery. *Heart* 2003;89:1327-34.
206. Bach DS, Eagle KA. Dobutamine stress echocardiography. Stressing the indications for preoperative testing. *Circulation* 1997;95:8-10.
207. Davila-Roman VG, Waggoner AD, Sicard GA, Geltman EM, Schechtman KB, Perez JE. Dobutamine stress echocardiography predicts surgical outcome in patients with an aortic aneurysm and peripheral vascular disease. *J Am Coll Cardiol* 1993;21:957-63.
208. Lalka SC, Sawada SG, Dalsing MC, Cikrit DF, Sawchuk AP, Kovacs RL, et al. Dobutamine stress echocardiography as a predictor of cardiac events associated with aortic surgery. *J Vasc Surg* 1992;15:831-40. discussion 841-2.
209. Poldermans D, Arnese M, Fioretti PM, Salustri A, Boersma E, Thomson IR, et al. Improved cardiac risk stratification in major vascular surgery with dobutamine-atropine stress echocardiography. *J Am Coll Cardiol* 1995;26:648-53.
210. Poldermans D, Fioretti PM, Forster T, Thomson IR, Boersma E, el-Said EM, et al. Dobutamine stress echocardiography for assessment of perioperative cardiac risk in patients undergoing major vascular surgery. *Circulation* 1993;87:1506-12.
211. Brown KA, Rowen M. Extent of jeopardized viable myocardium determined by myocardial perfusion imaging best predicts perioperative cardiac events in patients undergoing noncardiac surgery. *J Am Coll Cardiol* 1993;21:325-30.
212. Bry JD, Belkin M, O'Donnell TF Jr., Mackey WC, Udelson JE, Schmid CH, et al. An assessment of the positive predictive value and cost-effectiveness of dipyridamole myocardial scintigraphy in patients undergoing vascular surgery. *J Vasc Surg* 1994;19:112-21. discussion 121-4.
213. Hendel RC, Whitfield SS, Villegas BJ, Cutler BS, Leppo JA. Prediction of late cardiac events by dipyridamole thallium imaging in patients undergoing elective vascular surgery. *Am J Cardiol* 1992;70:1243-9.
214. Leppo JA. Preoperative cardiac risk assessment for noncardiac surgery. *Am J Cardiol* 1995;75:42D-51D.
215. Huang W-C, Chiou K-R, Liu C-P, Lin S-L, Lee D, Mar G-Y, et al. Comparison of real-time contrast echocardiography and low-dose dobutamine stress echocardiography in predicting the left ventricular functional recovery in patients after acute myocardial infarction under different therapeutic intervention. *Int J Cardiol* 2005;104:81-91.
216. Allman KC, Shaw LJ, Hachamovitch R, Udelson JE. Myocardial viability testing and impact of revascularization on prognosis in patients with coronary artery disease and left ventricular dysfunction: a meta-analysis. *J Am Coll Cardiol* 2002;39:1151-8.
217. Shen YT, Vatner SF. Mechanism of impaired myocardial function during progressive coronary stenosis in conscious pigs. Hibernation versus stunning? *Circ Res* 1995;76:479-88.
218. Vanoverschelde JL, Wijns W, Borgers M, Heyndrickx G, Depre C, Flameng W, et al. Chronic myocardial hibernation in humans. From bedside to bench. *Circulation* 1997;95:1961-71.
219. Vanoverschelde JL, Wijns W, Depre C, Essamri B, Heyndrickx GR, Borgers M, et al. Mechanisms of chronic regional postschemic dysfunction in humans. New insights from the study of noninfarcted collateral-dependent myocardium. *Circulation* 1993;87:1513-23.
220. Marinho NV, Keogh BE, Costa DC, Lammerstma AA, Ell PJ, Camici PG. Pathophysiology of chronic left ventricular dysfunction. New insights from the measurement of absolute myocardial blood flow and glucose utilization. *Circulation* 1996;93:737-44.
221. Shivalkar B, Flameng W, Szilard M, Pislaru S, Borgers M, Vanhaecke J. Repeated stunning precedes myocardial hibernation in progressive multiple coronary artery obstruction. *J Am Coll Cardiol* 1999;34:2126-36.
222. Schwarz ER, Schoendube FA, Kostin S, Schmiedtke N, Schulz G, Buell U, et al. Prolonged myocardial hibernation exacerbates cardiomyocyte degeneration and impairs recovery of function after revascularization. *J Am Coll Cardiol* 1998;31:1018-26.
223. Beanlands RS, Hendry PJ, Masters RG, deKemp RA, Woodend K, Ruddy TD. Delay in revascularization is associated with increased mortality rate in patients with severe left ventricular dysfunction and viable myocardium on fluorine 18-fluorodeoxyglucose positron emission tomography imaging. *Circulation* 1998;98(suppl 19):II51-6.
224. Cauty JM Jr., Suzuki G, Banas MD, Verheyen F, Borgers M, Fallavollita JA. Hibernating myocardium: chronically adapted to ischemia but vulnerable to sudden death. *Circ Res* 2004;94:1142-9.
225. Cwajg JM, Cwajg E, Nagueh SF, He ZX, Qureshi U, Olmos LI, et al. End-diastolic wall thickness as a predictor of recovery of function in myocardial hibernation: relation to rest-redistribution T1-201 tomography and dobutamine stress echocardiography. *J Am Coll Cardiol* 2000;35:1152-61.
226. Hammond HK, McKirnan MD. Effects of dobutamine and arbutamine on regional myocardial function in a porcine model of myocardial ischemia. *J Am Coll Cardiol* 1994;23:475-82.
227. Chen C, Li L, Chen LL, Prada JV, Chen MH, Fallon JT, et al. Incremental doses of dobutamine induce a biphasic response in dysfunctional left ventricular regions subtending coronary stenoses. *Circulation* 1995;92:756-66.
228. Mertes H, Segar DS, Johnson M, Ryan T, Sawada SG, Feigenbaum H. Assessment of hibernating myocardium by dobutamine stimulation in a canine model. *J Am Coll Cardiol* 1995;26:1348-55.
229. Hirano Y, Yamamoto T, Uehara H, Ozasa Y, Yamada S, Ikawa H, et al. Diagnosis of myocardial viability by exercise echocardiography. *J Cardiol* 1999;34:113-20.
230. Lu C, Carlino M, Fragasso G, Maisano F, Margonato A, Cappelletti A, et al. Enoximone echocardiography for predicting recovery of left ventricular dysfunction after revascularization: a novel test for detecting myocardial viability. *Circulation* 2000;101:1255-60.
231. Picano E, Marzullo P, Gigli G, Reisenhofer B, Parodi O, Distanti A, et al. Identification of viable myocardium by dipyridamole-induced

- improvement in regional left ventricular function assessed by echocardiography in myocardial infarction and comparison with thallium scintigraphy at rest. *Am J Cardiol* 1992;70:703-10.
232. Poldermans D, Sozzi FB, Bax JJ, Boersma E, Duncker DJ, Vourvouri E, et al. Influence of continuation of beta blockers during dobutamine stress echocardiography for the assessment of myocardial viability in patients with severe ischemic left ventricular dysfunction. *Am J Cardiol* 2001;88:A7. 68-70.
 233. Afridi I, Kleiman NS, Raizner AE, Zoghbi WA. Dobutamine echocardiography in myocardial hibernation. Optimal dose and accuracy in predicting recovery of ventricular function after coronary angioplasty. *Circulation* 1995;91:663-70.
 234. Cornel JH, Balk AH, Boersma E, Maat AP, Elhendy A, Arnesi M, et al. Safety and feasibility of dobutamine-atropine stress echocardiography in patients with ischemic left ventricular dysfunction. *J Am Soc Echocardiogr* 1996;9:27-32.
 235. Poldermans D, Rambaldi R, Bax JJ, Cornel JH, Thomson IR, Valkema R, et al. Safety and utility of atropine addition during dobutamine stress echocardiography for the assessment of viable myocardium in patients with severe left ventricular dysfunction. *Eur Heart J* 1998;19:1712-8.
 236. Armstrong WF. "Hibernating" myocardium: asleep or part dead? *J Am Coll Cardiol* 1996;28:530-5.
 237. Cornel JH, Bax JJ, Elhendy A, Maat AP, Kimman GJ, Geleijnse ML, et al. Biphasic response to dobutamine predicts improvement of global left ventricular function after surgical revascularization in patients with stable coronary artery disease: implications of time course of recovery on diagnostic accuracy. *J Am Coll Cardiol* 1998;31:1002-10.
 238. Maskoun W, Mustafa N, Mahenthiran J, Gradus-Pizlo I, Kamalesh M, Feigenbaum H, et al. Wall motion abnormalities with low-dose dobutamine predict a high risk of cardiac death in medically treated patients with ischemic cardiomyopathy. *Clin Cardiol* 2009;32:403-9.
 239. Sawada S. Dobutamine echocardiography for detection of viable myocardium in ischemic cardiomyopathy. *Echocardiography* 2000;17:69-77.
 240. Schinkel AF, Bax JJ, Poldermans D, Elhendy A, Ferrari R, Rahimtoola SH. Hibernating myocardium: diagnosis and patient outcomes. *Curr Probl Cardiol* 2007;32:375-410.
 241. Bax JJ, Poldermans D, Elhendy A, Cornel JH, Boersma E, Rambaldi R, et al. Improvement of left ventricular ejection fraction, heart failure symptoms and prognosis after revascularization in patients with chronic coronary artery disease and viable myocardium detected by dobutamine stress echocardiography. *J Am Coll Cardiol* 1999;34:163-9.
 242. Meluzin J, Cerny J, Frelich M, Stetka F, Spinarova L, Popelova J, et al. Prognostic value of the amount of dysfunctional but viable myocardium in revascularized patients with coronary artery disease and left ventricular dysfunction. *J Am Coll Cardiol* 1998;32:912-20.
 243. Afridi I, Grayburn PA, Panza JA, Oh JK, Zoghbi WA, Marwick TH. Myocardial viability during dobutamine echocardiography predicts survival in patients with coronary artery disease and severe left ventricular systolic dysfunction. *J Am Coll Cardiol* 1998;32:921-6.
 244. Senior R, Kaul S, Lahiri A. Myocardial viability on echocardiography predicts long-term survival after revascularization in patients with ischemic congestive heart failure. *J Am Coll Cardiol* 1999;33:1848-54.
 245. Bountiokos M, Schinkel AF, Bax JJ, Rizzello V, Valkema R, Krenning BJ, et al. Pulsed wave tissue Doppler imaging for the quantification of contractile reserve in stunned, hibernating, and scarred myocardium. *Heart* 2004;90:506-10.
 246. Cain P, Khoury V, Short L, Marwick TH. Usefulness of quantitative echocardiographic techniques to predict recovery of regional and global left ventricular function after acute myocardial infarction. *Am J Cardiol* 2003;91:391-6.
 247. Rambaldi R, Poldermans D, Bax JJ, Boersma E, Elhendy A, Vletter W, et al. Doppler tissue velocity sampling improves diagnostic accuracy during dobutamine stress echocardiography for the assessment of viable myocardium in patients with severe left ventricular dysfunction. *Eur Heart J* 2000;21:1091-8.
 248. Ryan T, Berlacher K, Lindner JR, Mankad SV, Rose GA, Wang A. CO-CATS 4 Task Force 5: training in echocardiography. *J Am Coll Cardiol* 2015;65:1786-99.
 249. Douglas P, Khandheria B, Stainback R, Weissman N. ACCF/AHA/ACEP/AHA/ASNC/SCAI/SCCT/SCMR 2008 appropriateness criteria for stress echocardiography. *J Am Coll Cardiol* 2008;1:1127-47.
 250. Fihn SD, Gardin JM, Abrams J, Berra K, Blankenship JC, Dallas AP, et al. 2012 ACCF/AHA/ACP/AATS/PCNA/SCAI/STS guideline for the diagnosis and management of patients with stable ischemic heart disease. A report of the American College of Cardiology Foundation/American Heart Association Task Force on practice guidelines, and the American College of physicians, American Association for Thoracic Surgery, preventive Cardiovascular nurses Association, Society for Cardiovascular Angiography and interventions, and Society of Thoracic Surgeons. *Circulation* 2012;126:e354-471.
 251. Tarakji K, Brunken R, McCarthy P, Al-Chekakie M, Abdel-Latif A, Pothier C, et al. Myocardial viability testing and the effect of early intervention in patients with advanced left ventricular systolic dysfunction. *Circulation* 2006;113:230-7.
 252. Sawada SG, Dasgupta S, Nguyen J, Lane KA, Gradus-Pizlo I, Mahenthiran J, et al. Effect of revascularization on long-term survival in patients with ischemic left ventricular dysfunction and a wide range of viability. *Am J Cardiol* 2010;106:187-92.
 253. Velazquez EJ, Lee KL, Deja MA, Jain A, Sopko G, Marchenko A, et al. Coronary-artery bypass surgery in patients with left ventricular dysfunction. *N Engl J Med* 2011;364:1607-16.
 254. Bonow RO, Maurer G, Lee KL, Holly TA, Binkley PF, Desvigne-Nickens P, et al. Myocardial viability and survival in ischemic left ventricular dysfunction. *N Engl J Med* 2011;364:1617-25.
 255. Oh J, Pellikka P, Panza J, Biernat J, Attisano T, Manahan B, et al. Core lab analysis of baseline echocardiographic studies in the STICH Trial and recommendation for use of echocardiography in future clinical trials. *J Am Soc Echocardiogr* 2012;25:327-36.
 256. Shah BN, Khattar RS, Senior R. The hibernating myocardium: current concepts, diagnostic dilemmas, and clinical challenges in the post-STICH era. *Eur Heart J* 2013;34:1323-36.
 257. Bourdillon PD, Broderick TM, Williams ES, Davis C, Dillon JC, Armstrong WF, et al. Early recovery of regional left ventricular function after reperfusion in acute myocardial infarction assessed by serial two-dimensional echocardiography. *Am J Cardiol* 1989;63:641-6.
 258. Sheehan FH, Doerr R, Schmidt WG, Bolson EL, Uebis R, von Essen R, et al. Early recovery of left ventricular function after thrombolytic therapy for acute myocardial infarction: an important determinant of survival. *J Am Coll Cardiol* 1988;12:289-300.
 259. Nesto RW, Cohn LH, Collins JJ Jr, Wynne J, Holman L, Cohn PF. Inotropic contractile reserve: a useful predictor of increased 5 year survival and improved postoperative left ventricular function in patients with coronary artery disease and reduced ejection fraction. *Am J Cardiol* 1982;50:39-44.
 260. Rocchi G, Poldermans D, Bax JJ, Rambaldi R, Boersma E, Elhendy A, et al. Usefulness of the ejection fraction response to dobutamine infusion in predicting functional recovery after coronary artery bypass grafting in patients with left ventricular dysfunction. *Am J Cardiol* 2000;85:1440-4.
 261. Sawada S, Bapat A, Vaz D, Weksler J, Fineberg N, Greene A, et al. Incremental value of myocardial viability for prediction of long-term prognosis in surgically revascularized patients with left ventricular dysfunction. *J Am Coll Cardiol* 2003;42:2099-105.
 262. Sawada SG, Lewis SJ, Foltz J, Ando A, Khouri S, Kaser S, et al. Usefulness of rest and low-dose dobutamine wall motion scores in predicting survival and benefit from revascularization in patients with ischemic cardiomyopathy. *Am J Cardiol* 2002;89:811-6.
 263. Joshi K, Alam I, Ruden E, Gradus-Pizlo I, Mahenthiran J, Kamalesh M, et al. Effect of improvement in left ventricular ejection fraction on long-term survival in revascularized patients with ischaemic left ventricular systolic dysfunction. *Eur J Echocardiogr* 2011;12:454-60.
 264. Ling LF, Marwick TH, Flores DR, Jaber WA, Brunken RC, Cerqueira MD, et al. Identification of therapeutic benefit from revascularization in patients with left ventricular systolic dysfunction: inducible ischemia versus hibernating myocardium. *Circ Cardiovasc Imaging* 2013;6:363-72.
 265. Quinones M, Verani M, Haichin R, Mahmarian J, Suarez J, Zog W. Exercise echocardiography versus 201Tl single-photon emission computed

- tomography in evaluation of coronary artery disease. Analysis of 292 patients. *Circulation* 1992;85:1217-8.
266. Schinkel A, Bax J, Elhendy A, van Domburg R, Valkema R, Vourvouri E, et al. Long-term prognostic value of dobutamine stress echocardiography compared with myocardial perfusion scanning in patients unable to perform exercise tests. *Am J Med* 2004;117:1-9.
 267. Shaw LJ, Eagle KA, Gersh BJ, Miller DD. Meta-analysis of intravenous dipyridamole-thallium-201 imaging (1985 to 1994) and dobutamine echocardiography (1991 to 1994) for risk stratification before vascular surgery. *J Am Coll Cardiol* 1996;27:787-98.
 268. Metz L, Beattie M, Hom R, Redberg R, Grady D, Fleischmann K. The prognostic value of normal exercise myocardial perfusion imaging and exercise echocardiography: a meta-analysis. *J Am Coll Cardiol* 2007;49:227-37.
 269. Douglas PS, Hoffmann U, Patel MR, Mark DB, Al-Khalidi HR, Cavanaugh B, et al. Outcomes of anatomical versus functional testing for coronary artery disease. *N Engl J Med* 2015;372:1291-300.
 270. Bax JJ, Wijns W, Cornel JH, Visser FC, Boersma E, Fioretti PM. Accuracy of currently available techniques for prediction of functional recovery after revascularization in patients with left ventricular dysfunction due to chronic coronary artery disease: comparison of pooled data. *J Am Coll Cardiol* 1997;30:1451-60.
 271. Sawada S, Elsner G, Segar DS, O'Shaughnessy M, Khouri S, Foltz J, et al. Evaluation of patterns of perfusion and metabolism in dobutamine-responsive myocardium. *J Am Coll Cardiol* 1997;29:55-61.
 272. Dipchand AI, Bharat W, Manlhiot C, Safi M, Lobach NE, McCrindle BW. A prospective study of dobutamine stress echocardiography for the assessment of cardiac allograft vasculopathy in pediatric heart transplant recipients. *Pediatr Transplant* 2008;12:570-6.
 273. Serreli G, Ruffini L, Ortenzia O, Cidda C, Lazzara C, Ghetti C. Radiation dose reduction in myocardial perfusion imaging single-photon emission computed tomography/computed tomography using a dose-tracking software. *Nucl Med Commun* 2018;39:894-900.
 274. Chen MH, Blackington LH, Zhou J, Chu TF, Gauvreau K, Marcus KJ, et al. Blood pressure is associated with occult cardiovascular disease in prospectively studied Hodgkin lymphoma survivors after chest radiation. *Leuk Lymphoma* 2014;55:2477-83.
 275. Heidenreich PA, Schnittger I, Strauss HW, Vagelos RH, Lee BK, Mariscal CS, et al. Screening for coronary artery disease after mediastinal irradiation for Hodgkin's disease. *J Clin Oncol* 2007;25:43-9.
 276. Chen MH, Abernathy E, Lunze F, Colan SD, O'Neill S, Bergersen L, et al. Utility of exercise stress echocardiography in pediatric cardiac transplant recipients: a single-center experience. *J Heart Lung Transplant* 2012;31:517-23.
 277. Kimball TR. Pediatric stress echocardiography. *Pediatr Cardiol* 2002;23:347-57.
 278. Boucek MM, Waltz DA, Edwards LB, Taylor DO, Keck BM, Trulock EP, et al. Registry of the International Society for Heart and Lung Transplantation: ninth official pediatric heart transplantation report—2006. *J Heart Lung Transplant* 2006;25:893-903.
 279. Pahl E, Duffy CE, Chaudhry FA. The role of stress echocardiography in children. *Echocardiography* 2000;17:507-12.
 280. Noto N, Kamiyama H, Karasawa K, Ayusawa M, Sumitomo N, Okada T, et al. Long-term prognostic impact of dobutamine stress echocardiography in patients with Kawasaki disease and coronary artery lesions: a 15-year follow-up study. *J Am Coll Cardiol* 2014;63:337-44.
 281. Brothers JA, McBride MG, Seliem MA, Marino BS, Tomlinson RS, Pampaloni MH, et al. Evaluation of myocardial ischemia after surgical repair of anomalous aortic origin of a coronary artery in a series of pediatric patients. *J Am Coll Cardiol* 2007;50:2078-82.
 282. Osaki M, McCrindle BW, Van Arsdell G, Dipchand AI. Anomalous origin of a coronary artery from the opposite sinus of Valsalva with an interarterial course: clinical profile and approach to management in the pediatric population. *Pediatr Cardiol* 2008;29:24-30.
 283. Fabozzo A, DiOrio M, Newburger JW, Powell AJ, Liu H, Fynn-Thompson F, et al. Anomalous aortic origin of coronary arteries: a single-center experience. *Semin Thorac Cardiovasc Surg* 2016;28:791-800.
 284. Ou P, Celermajer DS, Marini D, Agnoletti G, Vouhe P, Brunelle F, et al. Safety and accuracy of 64-slice computed tomography coronary angiography in children after the arterial switch operation for transposition of the great arteries. *JACC Cardiovasc Imaging* 2008;1:331-9.
 285. Khairy P, Clair M, Fernandes SM, Blume ED, Powell AJ, Newburger JW, et al. Cardiovascular outcomes after the arterial switch operation for D-transposition of the great arteries. *Circulation* 2013;127:331-9.
 286. Bierig SM, Ehler D, Knoll ML, Waggoner AD. American Society of Echocardiography minimum standards for the cardiac sonographer: a position paper. *J Am Soc Echocardiogr* 2006;19:471-4.
 287. Wiegers SE, Ryan T, Arrighi JA, Brown SM, Canaday B, Damp JB, et al. 2019 ACC/AHA/ASE advanced training statement on echocardiography (revision of the 2003 ACC/AHA clinical competence statement on echocardiography). *J Am Coll Cardiol* 2019;74:377-402.
 288. Brindis R, Douglas P, Hendel R, Peterson E, Wolk M, Allen J, et al. ACCF/ASNC appropriateness criteria for single-photon emission computed tomography myocardial perfusion imaging (SPECT MPI): a report of the American College of Cardiology Foundation quality Strategic directions Committee Appropriateness Criteria working group and the American Society of nuclear Cardiology. *J Am Coll Cardiol* 2005;46:1587-605.
 289. Douglas P, Khandheria B, Stainback R, Weissman N. ACCF/ASE/ACEP/ASNC/SCAL/SCCT/SCMR 2007 appropriateness criteria for transthoracic and transesophageal echocardiography. *J Am Coll Cardiol* 2007;20:787-805.
 290. Douglas P, Garcia M, Haines D, Lai W, Manning W, Patel A, et al. ACCF/ASE/AHA/ASNC/HFSA/HRS/SCAI/SCCM/SCCT/SCMR 2011 Appropriate use criteria for echocardiography: a report of the American College of Cardiology Foundation Appropriate use Criteria Task Force, American Society of echocardiography, American Heart Association, American Society of nuclear Cardiology, Heart failure Society of America, Heart rhythm Society, Society for Cardiovascular Angiography and interventions, Society of Critical Care medicine, Society of Cardiovascular Computed tomography, and Society for Cardiovascular magnetic resonance endorsed by the American College of Chest physicians. *J Am Coll Cardiol* 2011;57:1126-66.

Supplemental Table 1 Comparison of Doppler strain imaging and visual analysis of wall motion

	Doppler strain imaging				Visual analysis					
	Stress mode	Feasibility per segment basis	Parameters	Sens %	Spec %	Acc %	Feas %	Sens %	Spec %	Acc %
Abraham JACC 2002 ¹	Dob	91%	Time to Onset Relax	92	75					
Voigt Circulation 2003 ²	Dob	95% M-mode 85% Quantitation	Curved M-mode Ratio of Post Syst Strain to Max Strain >35%	86 82	89 85			81	82	
Hanekom Eur Heart J 2007 ³	Dob	85%	Peak Syst Strain Rate	89	53	74		90	53	75
Ingul JACC 2007 ⁴	Dob	80% Strain Rate	Peak Syst Strain Rate Peak Syst Strain Post Syst Strain Index	89 93 72	93 74 81	90 84 83	98	73	81	76
Weidemann Eur Heart J 2007 ⁵	Dob		Rest to Stress Change in Peak Syst Strain <0.6 s ⁻¹ Ratio of Post Syst Strain to Max Strain	89 72	89 70			80	67	
Takagi J Cardiology 2010 ⁶	Treadmill 5 Min Post Exercise Strain		Ratio of Time to Max Strain Post-Exercise to Time to Max Strain at Rest	93	73	87		87	80	84
Nagy Eur Heart J CV Imaging 2015 ⁷	Dob	87	Ratio of Post Syst Strain to Max Strain >35% Peak Syst Strain Rate ≤ -1.3 s ⁻¹	89 with visual analysis	64 with visual analysis	78 with visual analysis	100 Contrast	89	72	82

Supplemental Table 2 Comparison of 2D speckle-tracking and visual analysis of wall motion

Two-dimensional speckle-tracking visual analysis										
	Stress mode	Feasibility	Parameters	Sensitivity %	Specificity%	Accuracy %	Feasibility %	Sensitivity %	Specificity %	Accuracy %
Ingul JACC 2007 ⁴	DSE	77% Strain 84% Strain Rate	Peak Syst Strain Peak Syst Strain Rate	86 84	80 92	84 87	98	73	81	76
Hanekom Eur Heart J 2007 ³	DSE	82%	Peak Syst Strain Rate	82	50	69		90	53	75
Ng Am Heart J 2009 ⁸	DSE	81%	Peak Syst Strain	84	88	85		76	93	82
Celutkiene CV Ultrasound 2012 ⁹	DSE	92%	12 Different Markers	40 to 90	34 to 89	46 to 80		82	93	86
Yu Int J CV Imaging 2013 ¹⁰	DSE Intermed. Dose		Peak Syst Strain Rate Time to Peak Strain	79 82	67 74					
Hwang J CV Ultra. 2014 ¹¹	DSE 5 Min Post		Peak Syst Strain 5 Min Post-Stress	71	83	78		72	85	77
Cusma-Piccione JASE 2015 ¹²	Dip	100%	Peak Syst Strain Change from Low to Peak Dip Stress	84	92			44	55	
Aggeli Cardiovasc Ultr 2015 ¹³	DSE	75%	Rest to Stress Change in Syst Strain Change in Torsion	81 81	72 82			78	88	
Joyce JASE 2015 ¹⁴	DSE	92%	Rest to Peak Stress Change in Syst Strain	87	46	60		11	94	64
Uusitalo JASE 2016 ¹⁵	DSE 1 Min Post		Peak Syst Strain Rate 1 min Post-Stress	80 with WMS	67 with WMS			60	80	
Rumbinaite Echo 2016 ¹⁶	DSE	86%	Peak Syst Strain	94	82			76	84	

Supplemental Table 3 Diagnostic accuracy of stress echocardiography*

First author	Year	Modality	Number of patients in the study	Number who underwent coronary arteriography	Stenosis %	Sensitivity %	Specificity %
Kim ¹⁷	2016	DSE	202	202	>50	70	95
			202	202	>75	74	91
Abdelmoneim ¹⁸	2015	Regadenoson and MCE	150	150	>50	77 (67-85)	73 (57-84)
			150	150	>70	79 (67-88)	60 (47-72)
Neglia ¹⁹	2015	Stress echocardiography	475	261	>70 ECA or >50 LM	45 (33-57)	90 (86-94)
Wong ²⁰	2015	Post Treadmill Exercise	100	13	>70	73	80
Mordi ²¹	2014	DSE	82	82	≥70 ECA or ≥50 LM	71	73
Shaikh ²²	2014	Regadenoson-atropine	45	45	>70	61	86
Miszalski-Jamka ²³	2013	Supine Bicycle Stress, MCE	61	61	≥50	2D Echocardiography 71 LVO 78 MPE 85	2D Echocardiography 80 LVO 80 MPE 80
Caiati ²⁴	2013	Upright Bicycle	86	86	≥50	88	89
Caiati ²⁴	2013	Post Treadmill Exercise	86	86	≥50	66	89
Celutkienė ⁹	2012	DSE	151	151	≥70	82 (77-85)	93 (83-97)
Chandraratna ²⁵	2012	DSE	39	39	≥50	85	94
Falcão ²⁶	2013	DSE and MCE	42	42	>50	88 (75-100)	88 (72-100)
Peteiro ²⁷	2012	Treadmill Exercise	116	116	>50	84	63
Peteiro ²⁷	2012	Supine Bicycle	116	116	≥50	75	80
Aggeli ²⁸	2011	Adenosine Stress MPE, RT3D	60	60	>50	88 (2-D)	64 (2-D)
						90 (RT3D)	73 (RT3D)
Mathias ²⁹	2011	DSE and MCE	45	45	>50	79 (61-97)	96 (89-100)
Arnold ³⁰	2010	Adenosine and MCE	65	65	≥50	85	76
Badano ³¹	2010	2-D, 3-D, Dipyridamole	107	44	>50	80 (3-D)	87 (3-D)
						78 (2-D)	91 (2-D)
Gaibazzi ³²	2010	Dipyridamole plus Atropine, MPE	150	150	≥50	96	69
Gaibazzi ³³	2010	MPE and Dipyridamole	400	400	>50	96	66
Lu ³⁴	2010	DSE and Dipyridamole echocardiography	76	76	>50	87(DSE) 61 (Dipyridamole)	82(DSE) 91(Dipyridamole)
Takagi ⁶	2010	Post Treadmill Exercise	45	45	≥50	87	80
Płońska-Gosciniak ³⁵	2008	Right atrial pacing	100 (67 men and 33 women)	100	≥50	82 (Women) 95 (Men)	68 (Women) 79 (Men)

2D, Two-dimensional imaging; DSE, dobutamine stress echocardiography; ECA, major epicardial coronary artery; LM, left main coronary artery; LVO, left ventricular opacification; MCE, myocardial contrast echocardiography; MPE, myocardial perfusion echocardiography; RT3D, Real-time three-dimensional imaging.

*Search Strategy using PubMed: Stress Echocardiography and CAD but not Prognosis from 2007-2017 in English language.

Supplemental Table 4 Deformation assessment of viability

	Modality	Ejection Fraction (%)	Reference standard	Quantitative parameters	Quant Sensitivity, %	Quant Specificity, %	Wall motion	Wall Motion
Hoffman, R J Am Coll Cardiol 2002 ³⁶	Low Dose DSE	43 ± 9	FDG PET SPECT Perfusion	Tissue Velocity Increase >1.05 cm/s Dop Strain Rate Increase > -0.23 1/s	69 83	64 84	75	63
Hanekom, L Circulation 2005 ¹⁰⁹	Low Dose DSE	36 ± 8	Functional Recovery	Low Dose Dop Strain Rate > -0.7 1/s (Doppler velocities were not accurate) Increase in Dop Strain Rate > -0.25 1/s	78 80	77 75	73	77
Vitarelli, A J Card Failure 2006 ³⁷	Low and Moderate Dose DSE	29 ± 8	Functional Recovery	Low Dose Dop Strain Rate > -0.25 1/s (Doppler velocities were less accurate) Low Dose Dop Post-systolic Short Index <20%	85 86	85 85	73	81
Fujimoto, H. J Cardiology 2010 ³⁸	Low and Peak Dose DSE	52 ± 10	Functional Recovery	Dop Strain Post-systolic Short Index <0.29 Syst lengthening/Total shortening < 0.16	61 84	60 79	86	71
Bansal, M JACC CV Imaging 2010 ³⁹	Low Dose DSE	35 ± 11	Functional Recovery	Low Dose Dop Strain > -9.4% (Speckle-Tracking decreased accuracy) Low Dose Dop Strain Rate > -0.81 1/s	78 68	68 70	71	77
Rosner, A Eur H J CV Imaging 2012 ⁴⁰	Low and Moderate Dose DSE	49 ± 9	Functional Recovery by Strain	Resting Doppler Strain (lengthening) Improved Dop Strain (shortening) with dobutamine	72 77	77 80		
Ran, H Echocardiogr 2012 ⁴¹	Adenosine 140 µg/kg/min	40 ± 6	FDG PET SPECT Perfusion	Speckle Track % Increase in Rad Strain >9.5% Speckle Track % Increase in Long Strain >14.6%	84 87	81 90		
Li, L J of Clin Ultras 2016 ⁴²	Low Dose DSE	43 ± 6	Functional Recovery	Speckle Track Low Dose Long Strain (Circum strain, strain rate with dob also accurate) Speckle Track Low Dose Long Strain Rate	86 90	88 89	69	63

DSE, Dobutamine stress echocardiography; Dop, doppler; FDG PET, fluorodeoxyglucose positron emission tomography; SPECT, single photon emission computed tomography computed tomography computed tomography.

Supplemental Table 5 Summary of publications on use of stress echocardiography in detection of ischemia in children and young adults, with congenital heart disease or heart disease acquired in childhood

Stress echocardiography studies to assess for ischemia in children and congenital heart disease						
Disease	Author year	No. of patients	Age	Type of stress	Conclusions	
Cardiac Transplant Recipients	Chen ⁴³ 2012	47	Median 16.9 yrs old; median post-tx: 7.9 yrs	ESE, treadmill	In cardiac tx, ESE has excellent negative predictive value for exclusion of epicardial CAD. Largest series of ESE in pediatric cardiac tx patients and use of treadmill exercise.	
	Di Filippo ⁴⁴ 2003	18	Mean 13.5 yrs old; mean post-tx: 5.1 yrs	DSE	In cardiac tx, DSE is safe and feasible. Normal DSE predicts absence of significant CAD.	
	Dipchand ⁴⁵ 2008	102	Median 17 months old; median post-tx: 10 months	DSE	In cardiac tx, DSE correlates with higher grade of CAV. DSE may be used for initial screening for CAV.	
	Larsen ⁴⁶ 1998	78	Median 5.7 yrs old; mean post-tx: 4.6 yrs	DSE	In cardiac tx, DSE is sensitive, specific, and accurate, and is useful in determining event-free survival at 2 years.	
Kawasaki Disease (KD)	Maiers ⁴⁷ 2008	20	Mean 12.7 yrs old; mean post-tx: 7.9 yrs	DSE	In cardiac tx, multiple imaging modalities were necessary to detect transplant CAV.	
	Pahl ⁴⁸ 1995	28	Median 10.7 yrs. old; mean post-KD: 7.3 yrs.	ESE, treadmill	In KD, ESE is safe, non-invasive, and superior to ECG stress test alone.	
	Noto ⁴⁹ 1996	50	Mean 13.6 yrs old; mean post KD: 5.8 yrs	DSE	In KD, DSE is a safe and accurate diagnostic method for detection of coronary artery stenosis in kids.	
Childhood Cancer Survivors	Noto ⁵⁰ 2014	58	Mean 23.8 yrs old; mean post-KD: 14.7 yrs	DSE	DSE provided independent prognostic information 15 yrs post-KD.	
	Ryerson ⁵¹ 2015	80	Mean 13 y210 rs old; Mean post-cancer: 8-9 yrs	ESE, bike	In childhood cancer pts treated w/ anthracycline, strain imaging is feasible, and at their young age, no significant decrease in function with stress.	
Congenital Heart Disease	Chen ⁵² 2014	182	78% childhood cancer survivors; mean post-cancer: 17 yrs	ESE, treadmill	In asymptomatic long-term survivors of childhood cancer (Hodgkin's) treated with radiation, 5% on ESE had occult CAD requiring intervention.	
	Brothers ⁵³ 2007	24	Median: 12 yrs	ESE, bike and treadmill	In patients with anomalous aortic origin of the coronary arteries (AAOCA), multi-modality testing is useful for ischemia and post-operative care.	
	Hasan ⁵⁴ 2012	40	Median: 17 yrs	ESE, treadmill	In obstructed RV-PA conduit patients, ESE was feasible in detecting abnormal ventricular function and conduit dysfunction at peak exercise.	

Supplemental Table 5 (Continued)

Stress echocardiography studies to assess for ischemia in children and congenital heart disease					
Disease	Author year	No. of patients	Age	Type of stress	Conclusions
	Pauliks ⁵⁵ 2012	26	Mean: 14.9 years old; mean 5.4 yrs s/p Ross	ESE, treadmill	In patients s/p Ross procedure, ESE is feasible in most children and most had normal exercise capacity.
Technology And Imaging	Ciliberti ⁵⁶ 2015	42	Median 14.5 yrs	ESE, semi-supine bike	In children, there is rapid heart rate decrease during SE, secondary to extensive collateral circulation.
	Kutty ⁵⁷ 2012	68	Median 21.5 yrs	ESE, supine and tilted bike	In adolescent and young adults with CHD, stress echo w/contrast allows assessment of reserve perfusion defects and hemodynamics.

AAOCA, Anomalous aortic origin of a coronary artery; CAD, coronary artery disease; CAV, cardiac allograft vasculopathy; CHD, congenital heart disease; DSE, dobutamine stress echocardiography; F/u, follow-up; KD, Kawasaki Disease; RVF, right ventricular function; Tx, transplant.

SUPPLEMENTARY REFERENCES

- Abraham TP, Belohlavek M, Thomson HL, Pislaru C, Khandheria B, Seward JB, et al. Time to onset of regional relaxation: feasibility, variability and utility of a novel index of regional myocardial function by strain rate imaging. *J Am Coll Cardiol* 2002;39:1531-7.
- Voigt JU, Exner B, Schmiedehausen K, Huchzermeyer C, Reulbach U, Nixdorff U, et al. Strain-rate imaging during dobutamine stress echocardiography provides objective evidence of inducible ischemia. *Circulation* 2003;107:2120-6.
- Hanekom L, Cho GY, Leano R, Jeffriess L, Marwick TH. Comparison of two-dimensional speckle and tissue Doppler strain measurement during dobutamine stress echocardiography: an angiographic correlation. *Eur Heart J* 2007;28:1765-72.
- Ingul CB, Stoylen A, Slordahl SA, Wiseth R, Burgess M, Marwick TH. Automated analysis of myocardial deformation at dobutamine stress echocardiography: an angiographic validation. *J Am Coll Cardiol* 2007;49:1651-9.
- Weidemann F, Jung P, Hoyer C, Broscheit J, Voelker W, Ertl G, et al. Assessment of the contractile reserve in patients with intermediate coronary lesions: a strain rate imaging study validated by invasive myocardial fractional flow reserve. *Eur Heart J* 2007;28:1425-32.
- Takagi T, Takagi A, Yoshikawa J. Detection of coronary artery disease using delayed strain imaging at 5 min after the termination of exercise stress: head to head comparison with conventional treadmill stress echocardiography. *J Cardiol* 2010;55:41-8.
- Nagy AI, Sahlen A, Manouras A, Henareh L, da Silva C, Gunyeli E, et al. Combination of contrast-enhanced wall motion analysis and myocardial deformation imaging during dobutamine stress echocardiography. *Eur Heart J Cardiovasc Imaging* 2015;16:88-95.
- Ng AC, Sitges M, Pham PN, Tran da T, Delgado V, Bertini M, et al. Incremental value of 2-dimensional speckle tracking strain imaging to wall motion analysis for detection of coronary artery disease in patients undergoing dobutamine stress echocardiography. *Am Heart J* 2009;158:836-44.
- Celutkienė J, Zakarkaite D, Skorniakov V, Zvironaite V, Grabauskienė V, Burca J, et al. Quantitative approach using multiple single parameters versus visual assessment in dobutamine stress echocardiography. *Cardiovasc Ultrasound* 2012;10:31.
- Yu Y, Villarraga HR, Saleh HK, Cha SS, Pellikka PA. Can ischemia and dyssynchrony be detected during early stages of dobutamine stress echocardiography by 2-dimensional speckle tracking echocardiography? *Int J Cardiovasc Imaging* 2013;29:95-102.
- Hwang HJ, Lee HM, Yang IH, Lee JL, Pak HY, Park CB, et al. The value of assessing myocardial deformation at recovery after dobutamine stress echocardiography. *J Cardiovasc Ultrasound* 2014;22:127-33.
- Cusma-Piccione M, Zito C, Oretto L, D'Angelo M, Tripepi S, Di Bella G, et al. Longitudinal strain by automated function imaging detects single-vessel coronary artery disease in patients undergoing dipyridamole stress echocardiography. *J Am Soc Echocardiogr* 2015;28:1214-21.
- Aggeli C, Lagoudakou S, Felekos I, Panagopoulou V, Kastellanos S, Toutouzas K, et al. Two-dimensional speckle tracking for the assessment of coronary artery disease during dobutamine stress echo: clinical tool or merely research method. *Cardiovasc Ultrasound* 2015;13:43.
- Joyce E, Hoogslag GE, Al Amri I, Debonnaire P, Katsanos S, Bax JJ, et al. Quantitative dobutamine stress echocardiography using speckle-tracking analysis versus conventional visual analysis for detection of significant coronary artery disease after ST-segment elevation myocardial infarction. *J Am Soc Echocardiogr* 2015;28:1379-13789 e1.
- Uusitalo V, Luotolahti M, Pietila M, Wendelin-Saarenhovi M, Hartiala J, Saraste M, et al. Two-dimensional speckle-tracking during dobutamine stress echocardiography in the detection of myocardial ischemia in patients with suspected coronary artery disease. *J Am Soc Echocardiogr* 2016;29:470-9.e3.
- Rumbinaite E, Zaliaduonyte-Peksiene D, Lapinskas T, Zvirblyte R, Karuzas A, Jonauskienė I, et al. Early and late diastolic strain rate vs global longitudinal strain at rest and during dobutamine stress for the assessment of significant coronary artery stenosis in patients with a moderate and high probability of coronary artery disease. *Echocardiography* 2016;33:1512-22.
- Kim MN, Kim SA, Kim YH, Hong SJ, Park SM, Shin MS, et al. Head to head comparison of stress echocardiography with exercise electrocardiography for the detection of coronary artery stenosis in women. *J Cardiovasc Ultrasound* 2016;24:135-43.
- Abdelmoneim SS, Mulvagh SL, Xie F, O'Leary E, Adolphson M, Omer MA, et al. Regadenoson stress real-time myocardial perfusion echocardiography for detection of coronary artery disease: feasibility and accuracy of two different ultrasound contrast agents. *J Am Soc Echocardiogr* 2015;28:1393-400.
- Neglia D, Rovai D, Caselli C, Pietila M, Teresinska A, Aguade-Bruix S, et al. Detection of significant coronary artery disease by noninvasive anatomical and functional imaging. *Circ Cardiovasc Imaging* 2015;8.
- Wong CB, Leung SE, Fukuyunagi S. A novel method to risk stratify patients undergoing exercise stress echocardiography using a set of combined criteria. *Int J Angiol* 2015;24:35-40.
- Mordi I, Stanton T, Carrick D, McClure J, Oldroyd K, Berry C, et al. Comprehensive dobutamine stress CMR versus echocardiography in LBBB and suspected coronary artery disease. *JACC Cardiovasc Imaging* 2014;7:490-8.
- Shaikh K, Wang DD, Saad H, Alam M, Khandelwal A, Brooks K, et al. Feasibility, safety and accuracy of regadenoson-atropine (REGAT) stress echocardiography for the diagnosis of coronary artery disease: an angiographic correlative study. *Int J Cardiovasc Imaging* 2014;30:515-22.
- Miszalski-Jamka T, Kuntz-Hehner S, Tiemann K, Karwat K, Kostkiewicz M. Quantitative myocardial contrast supine bicycle stress echocardiography for detection of coronary artery disease. *Echocardiography* 2013;30:392-400.
- Caiati C, Lepera ME, Carretta D, Santoro D, Favale S. Head-to-head comparison of peak upright bicycle and post-treadmill echocardiography in detecting coronary artery disease: a randomized, single-blind crossover study. *J Am Soc Echocardiogr* 2013;26:1434-43.
- Chandraratna PA, Kuznetsov VA, Mohar DS, Sidorous PF, Scheutz J, Krinochkin DV, et al. Comparison of squatting stress echocardiography and dobutamine stress echocardiography for the diagnosis of coronary artery disease. *Echocardiography* 2012;29:695-9.
- Falcao SN, Rochitte CE, Junior WM, Quaglia L, Lemos PA, Sbrana JC, et al. Incremental value of perfusion over wall-motion abnormalities with the use of dobutamine-atropine stress myocardial contrast echocardiography and magnetic resonance imaging for detecting coronary artery disease. *Echocardiography* 2013;30:45-54.
- Peteiro J, Bouzas-Mosquera A, Estevez R, Pazos P, Pineiro M, Castro-Beiras A. Head-to-head comparison of peak supine bicycle exercise echocardiography and treadmill exercise echocardiography at peak and at post-exercise for the detection of coronary artery disease. *J Am Soc Echocardiogr* 2012;25:319-26.
- Aggeli C, Felekos I, Roussakis G, Kazazaki C, Lagoudakou S, Pietri P, et al. Value of real-time three-dimensional adenosine stress contrast echocardiography in patients with known or suspected coronary artery disease. *Eur J Echocardiogr* 2011;12:648-55.
- Mathias W Jr, Kowatsch I, Saroute AN, Osorio AF, Sbrana JC, Dourado PM, et al. Dynamic changes in microcirculatory blood flow during dobutamine stress assessed by quantitative myocardial contrast echocardiography. *Echocardiography* 2011;28:993-1001.
- Arnold JR, Karamitsos TD, Pegg TJ, Francis JM, Olszewski R, Searle N, et al. Adenosine stress myocardial contrast echocardiography for the detection of coronary artery disease: a comparison with coronary angiography and cardiac magnetic resonance. *JACC Cardiovasc Imaging* 2010;3:934-43.
- Badano LP, Muraru D, Rigo F, Del Mestre L, Ermacorora D, Gianfagna P, et al. High volume-rate three-dimensional stress echocardiography to assess inducible myocardial ischemia: a feasibility study. *J Am Soc Echocardiogr* 2010;23:628-35.
- Gaibazzi N, Rigo F, Squeri A, Ugo F, Reverberi C. Incremental value of contrast myocardial perfusion to detect intermediate versus severe

- coronary artery stenosis during stress-echocardiography. *Cardiovasc Ultrasound* 2010;8:16.
33. Gaibazzi N, Rigo F, Reverberi C. Detection of coronary artery disease by combined assessment of wall motion, myocardial perfusion and coronary flow reserve: a multiparametric contrast stress-echocardiography study. *J Am Soc Echocardiogr* 2010;23:1242-50.
 34. Lu C, Lu F, Fragasso G, Dabrowski P, Di Bello V, Chierchia SL, et al. Comparison of exercise electrocardiography, technetium-99m sestamibi single photon emission computed tomography, and dobutamine and dipyridamole echocardiography for detection of coronary artery disease in hypertensive women. *Am J Cardiol* 2010;105:1254-60.
 35. Plonska-Gosciniak E, Lancellotti P, Kleinrok A, Gackowski A, Gasior Z, Kowalik I, et al. Influence of gender on diagnostic accuracy of rapid atrial and ventricular pacing stress echocardiography for the detection of coronary artery disease: a multicenter study (Pol-RAPSE final results). *J Am Soc Echocardiogr* 2008;21:1116-20.
 36. Hoffmann R, Altiok E, Nowak B, Heussen N, Kuhl H, Kaiser HJ, et al. Strain rate measurement by Doppler echocardiography allows improved assessment of myocardial viability in patients with depressed left ventricular function. *J Am Coll Cardiol* 2002;39:443-9.
 37. Vitarelli A, Montesano T, Gaudio C, Conde Y, Cimino E, D'Angeli I, et al. Strain rate dobutamine echocardiography for prediction of recovery after revascularization in patients with ischemic left ventricular dysfunction. *J Card Fail* 2006;12:268-75.
 38. Fujimoto H, Honma H, Ohno T, Mizuno K, Kumita S. Longitudinal Doppler strain measurement for assessment of damaged and/or hibernating myocardium by dobutamine stress echocardiography in patients with old myocardial infarction. *J Cardiol* 2010;55:309-16.
 39. Bansal M, Jeffries L, Leano R, Mundy J, Marwick TH. Assessment of myocardial viability at dobutamine echocardiography by deformation analysis using tissue velocity and speckle-tracking. *JACC Cardiovasc Imaging* 2010;3:121-31.
 40. Rosner A, Avenarius D, Malm S, Iqbal A, Baltabaeva A, Sutherland GR, et al. Persistent dysfunction of viable myocardium after revascularization in chronic ischaemic heart disease: implications for dobutamine stress echocardiography with longitudinal systolic strain and strain rate measurements. *Eur Heart J Cardiovasc Imaging* 2012;13:745-55.
 41. Ran H, Zhang PY, Fang LL, Ma XW, Wu WF, Feng WF. Clinic value of two-dimensional speckle tracking combined with adenosine stress echocardiography for assessment of myocardial viability. *Echocardiography* 2012;29:688-94.
 42. Li L, Wang F, Xu T, Chen J, Wang C, Wang X, et al. The detection of viable myocardium by low-dose dobutamine stress speckle tracking echocardiography in patients with old myocardial infarction. *J Clin Ultrasound* 2016;44:545-54.
 43. Chen MH, Abernathy E, Lunze F, Colan SD, O'Neill S, Bergersen L, et al. Utility of exercise stress echocardiography in pediatric cardiac transplant recipients: a single-center experience. *J Heart Lung Transplant* 2012;31:517-23.
 44. Di Filippo S, Semiond B, Roriz R, Sassolas F, Raboisson MJ, Bozio A. Non-invasive detection of coronary artery disease by dobutamine-stress echocardiography in children after heart transplantation. *J Heart Lung Transplant* 2003;22:876-82.
 45. Dipchand AI, Bharat W, Manlhiot C, Safi M, Lobach NE, McCrindle BW. A prospective study of dobutamine stress echocardiography for the assessment of cardiac allograft vasculopathy in pediatric heart transplant recipients. *Pediatr Transplant* 2008;12:570-6.
 46. Larsen RL, Applegate PM, Dyar DA, Ribeiro PA, Fritzsche SD, Mulla NF, et al. Dobutamine stress echocardiography for assessing coronary artery disease after transplantation in children. *J Am Coll Cardiol* 1998;32:515-20.
 47. Maiers J, Hurwitz R. Identification of coronary artery disease in the pediatric cardiac transplant patient. *Pediatr Cardiol* 2008;29:19-23.
 48. Pahl E, Sehgal R, Chrystof D, Neches WH, Webb CL, Duffy CE, et al. Feasibility of exercise stress echocardiography for the follow-up of children with coronary involvement secondary to Kawasaki disease. *Circulation* 1995;91:122-8.
 49. Noto N, Ayusawa M, Karasawa K, Yamaguchi H, Sumitomo N, Okada T, et al. Dobutamine stress echocardiography for detection of coronary artery stenosis in children with Kawasaki disease. *J Am Coll Cardiol* 1996;27:1251-6.
 50. Noto N, Kamiyama H, Karasawa K, Ayusawa M, Sumitomo N, Okada T, et al. Long-term prognostic impact of dobutamine stress echocardiography in patients with Kawasaki disease and coronary artery lesions: a 15-year follow-up study. *J Am Coll Cardiol* 2014;63:337-44.
 51. Ryerson AB, Border WL, Wasilewski-Masker K, Goodman M, Meacham L, Austin H, et al. Assessing anthracycline-treated childhood cancer survivors with advanced stress echocardiography. *Pediatr Blood Cancer* 2015;62:502-8.
 52. Chen MH, Blackington LH, Zhou J, Chu TF, Gauvreau K, Marcus KJ, et al. Blood pressure is associated with occult cardiovascular disease in prospectively studied Hodgkin lymphoma survivors after chest radiation. *Leuk Lymphoma* 2014;55:2477-83.
 53. Brothers JA, McBride MG, Seliem MA, Marino BS, Tomlinson RS, Pampaloni MH, et al. Evaluation of myocardial ischemia after surgical repair of anomalous aortic origin of a coronary artery in a series of pediatric patients. *J Am Coll Cardiol* 2007;50:2078-82.
 54. Hasan BS, Lunze FI, McElhinney DB, Stantcheva E, Brown DW, Rhodes J, et al. Exercise stress echocardiographic assessment of outflow tract and ventricular function in patients with an obstructed right ventricular-to-pulmonary artery conduit after repair of conotruncal heart defects. *Am J Cardiol* 2012;110:1527-33.
 55. Pauliks LB, Brian Clark J, Rogerson A, DiPietro A, Myers JL, Cyran SE. Exercise stress echocardiography after childhood Ross surgery: functional outcome in 26 patients from a single institution. *Pediatr Cardiol* 2012;33:797-801.
 56. Ciliberti P, McLeod I, Cairello F, Kaski JP, Fenton M, Giardini A, et al. Semi-supine exercise stress echocardiography in children and adolescents: feasibility and safety. *Pediatr Cardiol* 2015;36:633-9.
 57. Kutty S, Olson J, Danford CJ, Sandene EK, Xie F, Fletcher SE, et al. Ultrasound contrast and real-time perfusion in conjunction with supine bicycle stress echocardiography for comprehensive evaluation of surgically corrected congenital heart disease. *Eur Heart J Cardiovasc Imaging* 2012;13:500-9.