
North American clinical management guidelines for hidradenitis suppurativa: A publication from the United States and Canadian Hidradenitis Suppurativa Foundations



Part II: Topical, intralesional, and systemic medical management

Ali Alikhan, MD (Co-chair),^a Christopher Sayed, MD (Co-chair),^b Afsaneh Alavi, MD, MSc,^c Raed Alhusayen, MD,^c Alain Brassard, MD,^d Craig Burkhart, MD,^b Karen Crowell, MLIS,^e Daniel B. Eisen, MD,^d Alice B. Gottlieb, MD, PhD,^f Iltefat Hamzavi, MD,^g Paul G. Hazen, MD,^h Tara Jaleel, MD,ⁱ Alexa B. Kimball, MD, MPH,^j Joslyn Kirby, MD, MEd, MS,^k Michelle A. Lowes, MBBS, PhD,^l Robert Micheletti, MD,^{m,n} Angela Miller, CCRP, CWCA,^g Haley B. Naik, MD, MHSc,^o Dennis Orgill, MD,^p and Yves Poulin, MD^q

Sacramento and San Francisco, California; Chapel Hill and Durham, North Carolina; Toronto, Ontario, Canada; New York, New York; Detroit, Michigan; Westlake, Ohio; Boston, Massachusetts; Hershey and Philadelphia, Pennsylvania; and Quebec City, Quebec, Canada

Hidradenitis suppurativa is a severe and debilitating dermatologic disease. Clinical management is challenging and consists of both medical and surgical approaches, which must often be combined for best outcomes. Therapeutic approaches have evolved rapidly in the last decade and include the use of

From Sutter Health, Sacramento^a; Department of Dermatology, University of North Carolina at Chapel Hill^b; Department of Medicine, Division of Dermatology, University of Toronto^c; Department of Dermatology, University of California at Davis, Sacramento^d; Health Sciences Library, University of North Carolina School of Medicine, Chapel Hill^e; Department of Dermatology, Icahn School of Medicine at Mt Sinai Hospital, New York^f; Department of Dermatology, Henry Ford Hospital, Detroit^g; Associates in Dermatology, Westlake^h; Department of Dermatology, Duke University School of Medicine, Durhamⁱ; Department of Dermatology, Harvard Medical School, Boston^j; Department of Dermatology, Penn State Hershey Medical Center^k; Laboratory for Investigative Dermatology, New York^l; Department of Dermatology^m and Department of Medicine, Perelman School of Medicine, University of Pennsylvania, Philadelphiaⁿ; Department of Dermatology, University of California San Francisco^o; Division of Plastic Surgery, Brigham and Women's Hospital, Boston^p; and Centre de Recherche Dermatologique du Quebec Metropolitan.^q

Dr Alikhan and Dr Sayed are cofirst authors.

Funding sources: None.

Disclosure: Dr Sayed reports service as a speaker for AbbVie and Novartis, an advisory board member for AbbVie and InflaRx, a coinvestigator for AbbVie and Novartis, and an investigator for InflaR and UCB. Dr Hamzavi reports service as an investigator for AbbVie, The Microdermis Corporation, Adelphi Values, and Lencicura and a consultant for UCB and Incyte; in addition, he is president of the Hidradenitis Suppurativa Foundation. Dr Hazen reports service as a speaker for AbbVie and an advisory board member for AbbVie. Dr Kimball reports service as a consultant and investigator for Amgen, AbbVie, Janssen, and Novartis and has received fellowship funding from Novartis and AbbVie. Dr Lowes reports service as an advisory board member

for AbbVie and Janssen and a consultant for AbbVie, XBiotech, and Incyte. Dr Alavi reports service as a clinical investigator and consultant for AbbVie, Janssen, Novartis, Pfizer, Galderma, Leo, and Valeant and has received grant funding from AbbVie. Dr Naik reports grant funding from AbbVie. Dr Alhusayen reports service for AbbVie as an advisory board member and consulting and has received research funding from the company; he has also served as an advisory board member for Janssen and a consultant for Eli Lilly and Company and Hidradem Solutions. Dr Orgill has served as a consultant and investigator for KCI, Inc, and Integra. Dr Brassard has served as a speaker and advisory board member for AbbVie, Janssen, Celgene, and 3M and as a speaker for Coloplast and Hollister. Dr Miller has served as a consultant for AbbVie and an advisory board member for AbbVie and BSN; in addition, she is employed by the Hidradenitis Suppurativa Foundation and is president and founding director of the Hope for HS support group. Dr Poulin has served as an investigator, advisory board member, and speaker for AbbVie. Dr Kirby has served as an advisory board member and speaker for AbbVie and a consultant for Incyte and Chemocentryx. Dr Gottlieb has served as an investigator for Novartis and a speaker for AbbVie. Dr Jaleel has served as an investigator for Eli Lilly and Company. Dr Alikhan, Dr Micheletti, Dr Eisen, Dr Burkhart, and Dr Crowell have no conflicts of interest to disclose.

Accepted for publication February 27, 2019.

Reprints not available from the authors.

Correspondence to: Christopher Sayed, MD, University of North Carolina Dermatology, 410 Market St, Suite 400, Chapel Hill, NC, 27516. E-mail: christopher_sayed@med.unc.edu.

Published online March 11, 2019.

0190-9622/\$36.00

© 2019 by the American Academy of Dermatology, Inc.

<https://doi.org/10.1016/j.jaad.2019.02.068>

topical therapies, systemic antibiotics, hormonal therapies, and a wide range of immunomodulating medications. An evidence-based guideline is presented to support health care practitioners as they select optimal medical management strategies and is reviewed in this second part of the management guidelines. A therapeutic algorithm informed by the evidence available at the time of the review is provided. (J Am Acad Dermatol 2019;81:91-101.)

Key words: acne inversa; adalimumab; biomarkers; carbon dioxide laser; clindamycin; comorbidities; ertapenem; finasteride; guidelines; hidradenitis suppurativa; infliximab; laser; lifestyle modification; microbiome; Nd:YAG; oral contraceptive pills; rifampin; spironolactone.

DISCLAIMER

The purpose of these guidelines is to summarize the available data at the time of preparation—it is possible certain treatments or procedures are not included, as the primary literature review concluded on March 16, 2017, with only selected updates of high clinical impact through December 1, 2018. Given the difficulty in treating hidradenitis suppurativa (HS), there is no guarantee that following the guidelines will result in successful treatment. Moreover, the guidelines are not meant to set a standard of care. Care of a patient with HS is ultimately guided by the physician and patient, with an emphasis on factors unique to individual patients.

SCOPE

The guidelines address management of patients presenting with HS and discuss various treatments and procedures available at the time of preparation. In Part II of the guidelines the evidence available to guide topical and systemic medical treatment is graded in [Table I](#). A therapeutic algorithm providing an overview of treatment strategies based on Hurley staging is provided in [Fig 1](#).

TOPICAL AND INTRALESIONAL THERAPIES IN HS

Topical treatment of HS includes skin cleansers, keratolytic agents, and topical antibiotics ([Table II](#)).

Choice of skin cleanser is empiric, as no data exist for specific agents, though use of chlorhexidine, benzoyl peroxide, and zinc pyrithione is supported by expert opinion.^{3,96}

Resorcinol 15% cream, a keratolytic and antiseptic, was studied in 12 women with Hurley stage I or II disease twice daily for HS flares and daily

CAPSULE SUMMARY

- Evidence regarding topical and systemic medical treatment of hidradenitis suppurativa is increasing, but no management guidelines currently exist in North America.
- Available evidence is graded and recommendations for management including a therapeutic algorithm is provided.

between flares; it reduced pain and duration of abscesses, though irritant dermatitis was frequent.⁴

The only topical antibiotic studied is clindamycin 1% solution.^{1,2} A 12-week randomized, placebo-controlled trial of 27 subjects with Hurley stage I or II disease demonstrated reduced pustules but no effect on inflammatory nodules and abscesses.¹ Patient self-assessment improved. Topical clindamycin

performed similarly to tetracycline in a double-blind comparative trial of 46 patients with mild-to-moderate disease. It is well tolerated, but it increases rates of *Staphylococcus aureus* resistance in patients with HS.⁷ Benzoyl peroxide may reduce this risk.⁵

A prospective case series on the effect of intralesional triamcinolone, 10 mg/mL (0.2-2.0 mL), into inflamed HS lesions demonstrated significant reductions in physician-assessed erythema, edema, suppuration, and size.⁶ A significant difference in pain visual analog scale (VAS) score occurred after 1 day.⁶

SYSTEMIC ANTIBIOTICS IN HS

Systemic antibiotics have been a mainstay of HS treatment for decades, with many regimens reported ([Table III](#)). Monotherapy is possible for mild disease, but in advanced disease their role is adjunctive on account of lower response rates and increased recurrence.

A single randomized controlled trial (RCT) comparing tetracycline, 500 mg twice daily, with topical clindamycin demonstrated a 30% reduction of abscesses in both groups, but changes in patient-reported outcomes were not significant.² Minocycline has been evaluated only in combination with colchicine, making its utility unclear.⁹ Similarly, doxycycline, 100 mg twice daily, was used in combination with adalimumab or placebo in a subset of

Abbreviations used:

DLQI:	Dermatology Life Quality Index
FDA:	US Food and Drug Administration
HiSCR:	Hidradenitis Suppurativa Clinical Response
HS:	hidradenitis suppurativa
HS-PGA:	hidradenitis suppurativa Physician's Global Assessment
IL:	interleukin
PGA:	Physician's Global Assessment
RCT:	randomized controlled trial
TNF:	tumor necrosis factor
VAS:	visual analog scale

patients in the PIONEER studies of adalimumab, but it was not independently linked to better outcomes in either arm.⁴⁹

Clindamycin and rifampin in combination have been studied in HS more than most other antibiotics, typically with both used at a dose of 300 mg twice daily. A systematic review of retrospective and prospective series reported response rates from 71% to 93% in 187 patients, strongly favoring their use.^{12,13,97} Treatment typically lasts 8 to 12 weeks and can be repeated intermittently as monotherapy in patients with mild-to-moderate disease or as adjuvant therapy in those with severe disease.

A retrospective series of 28 patients taking oral metronidazole, moxifloxacin, and rifampin reported that 6 of 6 patients with Hurley stage I disease, 8 of 10 with Hurley stage II disease, and 2 of 12 with Hurley stage III disease had complete responses. Treatment duration ranged from 1 to 12 months, but metronidazole was stopped at 6 weeks to avoid neurologic toxicity. Typical dosing is moxifloxacin, 400 mg once daily, metronidazole, 500 mg thrice daily, and rifampin, 300 mg twice daily. Relapse was common, but most patients responded to a second course.¹⁷ This is usually considered as third-line therapy or as a bridge to surgery or other long-term therapy.

Dapsone was evaluated in a retrospective review with response in 38% of patients, though none with Hurley stage III disease responded.¹⁸ A series of 5 patients also noted positive response.¹⁹ Treatment for at least 3 months is recommended, and long-term maintenance may sustain responses. Dosing in studies has varied, but starting at 50 mg daily and titrating up to 200 mg daily can be considered. Given the low response rates and need for monitoring, dapsone is reserved as third-line treatment in Hurley stage I or II disease.

Of 30 patients treated with 1 g of intravenously administered ertapenem daily, most areas affected by Hurley stage I or II reached clinical remission, and most patients with Hurley stage III disease had major

improvement in quality of life. Relapses were frequent with discontinuation, and most patients received additional oral antibiotics after discontinuing ertapenem.²⁰ Ertapenem is highly effective but is reserved as third-line therapy for a single 6-week course as rescue therapy or during surgical planning, given the practical barriers to home infusions and concerns about antibiotic resistance.

Many antibiotics, including trimethoprim-sulfamethoxazole, beta-lactams, linezolid, and others, have been anecdotally reported to have benefit in some patients with HS, but there is a lack of published evidence. A supplemental brief overview of dosing, side effects, and monitoring are available at www.hs-foundation.org.

HORMONAL THERAPIES IN HS

Androgens influence HS, as evidenced by the effects of pregnancy and menstrual cycles for many patients,^{98,99} but the recommendations on hormonal therapies are based on limited evidence (Table IV).

The only RCT of hormonal therapy compared ethinyl estradiol/noregestrol with ethinyl estradiol and cyproterone acetate; it was a double-blind, controlled, cross-over trial of 24 women. Both therapies resulted in similar improvement, with 12 patients improving or clearing completely.²²

In a retrospective series of 29 women treated with antiandrogen therapies (ethinyl estradiol, cyproterone acetate, and spironolactone), 16 (55%) reported improvement.²³ Treatment with spironolactone, 100 to 150 mg daily, resulted in improvement in 17 of 20 (85%), including complete remission in 11 of 20 (55%). Of the 3 patients with severe HS, none cleared.²⁴

Metformin, 500 mg 2 to 3 times daily, was associated with significant improvement in Sartorius score in 18 of 25 patients (72%) and Dermatology Life Quality Index (DLQI) score in 16 of 25 patients (64%) in a 24-week uncontrolled, prospective study. Most patients (22 of 25) were females with features of polycystic ovarian syndrome.²⁵ Finally, adjunctive or monotherapy with finasteride, 1.25 to 5 mg/d, has been beneficial in 4 reports with patients in total.²⁶

There is anecdotal concern among authors that progestogen-only regimens may worsen HS in some cases. These regimens may be used with caution but discontinued if disease worsens.

Hormonal agents should be considered as monotherapy in females with mild-to-moderate HS or as adjunctive agents for more severe disease. Patients reporting HS flares around menses or with features of polycystic ovarian syndrome may more likely benefit.^{23,26}

Table I. Strength of recommendations for the management and treatment of HS

Recommendations	Strength of recommendation	Level of evidence	References
Topical/IL therapies			
Clindamycin	C	II, III	1,2
Zinc pyrithione	C	III	3
Chlorhexidine	C	Expert opinion	
Resorcinol	C	III	4
Triamcinolone (IL)	C	III	5,6
Benzoyl peroxide	C	III	7
Dapsone	C	Expert opinion	
Systemic antibiotics			
Tetracyclines	C	II, III	2,8,9
Rifampin + clindamycin	B	II	10-16
Rifampin + moxifloxacin + metronidazole	C	II	17
Dapsone	C	III	18,19
Ertapenem	C	III	20,21
Hormonal therapies			
Antiandrogen contraceptives	C	II	22,23
Spironolactone	C	III	24
Metformin	C	III	25
Finasteride	C	III	26
Retinoids			
Isotretinoin	B	II	27-32
Acitretin	B	II	33-36
Alitretinoin	B	II	37
Systemic immunomodulators			
Methotrexate	Not recommended	III	38
Azathioprine	Not recommended	III	39
Colchicine	C (in combination with minocycline only)	III	9,40
Cyclosporine	C	III	41-45
Systemic steroids	C*	III	46,47
Biologics			
Adalimumab	A	I	48-66
Infliximab	B	II	65,67-77
Anakinra	B	II	78-82
Ustekinumab	B	II	83-87
Etanercept	C	II	88-93
Golimumab	C	III	78,94

Strength of Recommendation Taxonomy recommendation level: I, good-quality patient-oriented evidence; II, limited-quality patient-oriented evidence; and III, other evidence, including consensus guidelines, opinion, case studies, and disease-oriented evidence. Evidence grading level: A, recommendation based on consistent and good-quality patient-oriented evidence; B, recommendation based on inconsistent or limited-quality patient-oriented evidence; and C, recommendation based on consensus, opinion, case studies, or disease-oriented evidence.⁹⁵

HS, Hidradenitis suppurativa; IL, intralesional.

*May be considered as low-dose adjunctive treatment or pulse dosing for acute flares or to bridge to other treatment.

RETINOIDS IN HS

Historically, retinoids were frequently used for HS, possibly because the pathogenesis was considered more similar to that of acne vulgaris.¹⁰⁰ Results in HS have disappointed compared with those in cystic acne (Table V), which is consistent with our current understanding of HS as a follicular disorder.¹⁰¹ Systemic retinoids should be prescribed by those familiar with side effects and

monitoring parameters, as outlined at www.hs-foundation.org.¹⁰²

In all, 4 retrospective and 3 prospective uncontrolled cohort studies with 5 or more patients have been reported for isotretinoin monotherapy, for a total of 207 patients.^{28-33,103} The mean dose ranged from 0.5 to 1 mg/kg/d, with the mean duration ranging from 4 to 10 months. Hurley stages were mostly unreported and outcome measures varied

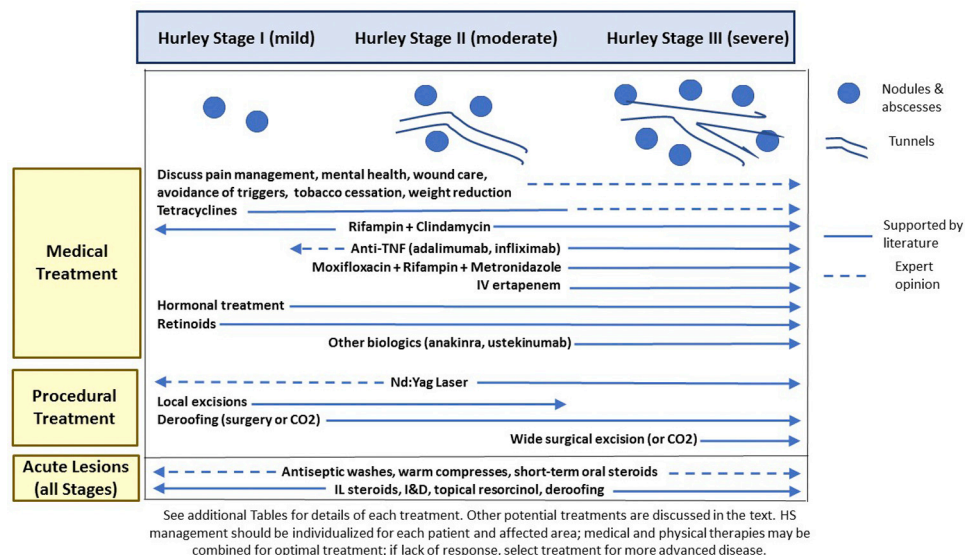


Fig 1. Overview of treatment strategies based on Hurley staging. *I&D*, Incision and drainage; *IL*, intralesional; *IV*, intravenous; *Nd:YAG*, neodymium-doped yttrium-aluminum-garnet; *TNF*, tumor necrosis factor.

Table II. Recommendations for topical and intralesional therapies

Topical clindamycin may reduce pustules in HS, but it carries a high risk of bacterial resistance.

Resorcinol 15% cream is recommended but may induce contact dermatitis.

Washing with chlorhexidine, zinc pyrithione, or other antibacterial washes is supported by expert opinion.

Intralesional corticosteroid for inflamed lesions is recommended on the basis of weak evidence for short-term control of HS flares.

HS, Hidradenitis suppurativa.

markedly, but a total of 85 of 207 (41%) improved, with better responses in milder disease. Isotretinoin should be considered most strongly in patients with concomitant nodulocystic acne.

Many consider acitretin to be superior to isotretinoin, but comparative evidence is lacking. Acitretin is contraindicated in women with reproductive potential. Three cohort studies and 1 small RCT (acitretin vs acitretin and wide excision) of mostly patients with Hurley stage II to III disease have been reported, for a total of 50 patients.³³⁻³⁶ The typical dose was 0.5 or 0.6 mg/kg/d, with the mean duration ranging from 3 to 12 months. Validated outcome measures were lacking, but 54% of patients reported improvement.

A single prospective, uncontrolled study of 14 females receiving alitretinoin, 10 mg/d for 24 weeks,

Table III. Recommendations for systemic antibiotics

Tetracyclines are recommended in mild-to-moderate HS for a 12-week course or as long-term maintenance when appropriate.

Clindamycin and rifampin in combination is effective as a second-line treatment for mild-to-moderate disease or as a first-line or adjunct treatment in severe disease.

Moxifloxacin, metronidazole, and rifampin in combination are recommended as second- or third-line treatment in moderate-to-severe disease.

Dapsone may be effective for a minority of patients with Hurley stage I or II disease as long-term maintenance therapy.

IV ertapanem is recommended for severe disease as a 1-time rescue therapy or as a bridge to surgery or other long-term maintenance.

Determining the duration and frequency of antibiotic use should balance the benefit received by each patient with the risk of antibiotic resistance. Recurrence following cessation is frequent.

HS, Hidradenitis suppurativa; *IV*, intravenous.

demonstrated improvement in all patients.³⁷ There was significant improvement in 78.5% of patients, and 42.8% had a reduction in Sartorius scale score of 50% or more. The mean DLQI decreased from 17 to 2.

Table IV. Recommendations for hormonal agents

Hormonal agents, including estrogen-containing combined oral contraceptives, spironolactone, cyproterone acetate, metformin, and finasteride, should be considered in appropriate female patients, either as monotherapy for mild-to-moderate HS or in combination with other agents for more severe disease.

Anecdotal data suggest that progestogen-only contraceptives may worsen HS and should potentially be avoided.

Small samples sizes, variable outcome measures and methods, and reporting bias are major limitations in all described evidence of hormonal therapies.

HS, Hidradenitis suppurativa.

Table V. Recommendations for retinoids

Results from isotretinoin studies have been mixed. Its use should be considered only as a second- or third-line treatment or in patients with severe concomitant acne.

Acitretin may be superior to isotretinoin for the treatment of HS, but robust comparative studies are lacking. It should be considered a second- or third-line treatment.

Alitretinoin is supported by a single study in women. It is available in Canada and many other countries but not in the United States.

HS, Hidradenitis suppurativa.

SYSTEMIC IMMUNOSUPPRESSANTS

The use of several immunomodulators in HS has been reported (Table VI). Methotrexate is a folate antagonist that is widely used in dermatology.^{104,105} A single series of 3 patients treated with 12.5 to 15 mg weekly for 6 to 24 weeks did not suggest efficacy, and its use is not recommended.³⁸

Similarly, data for azathioprine are limited to 9 patients receiving low doses of 0.5 to 1 mg/kg for 1 to 8 months, with 4 of 9 showing slight improvement.³⁹

Cyclosporine has been reported in fewer than 20 cases, with responses generally being poor in patients receiving doses less than 5 mg/kg.⁴¹ Case reports of use of doses up to 6 mg/kg daily and combination therapy have noted improvement, though relapse was frequent upon discontinuation and side effects were often limiting.^{43,44}

In a series of 8 patients with moderate-to-severe HS treated with colchicine, 0.5 mg twice daily, only 2 patients continued treatment at 4 months, with 1 having slight improvement in HS Physician's Global Assessment (PGA) (HS-PGA) score.⁴⁰ A recent series

Table VI. Recommendations for immunosuppressants

The available limited evidence does not support the use of methotrexate or azathioprine in the treatment of HS.

Weak evidence supports the use of colchicine in combination with minocycline in refractory mild-to-moderate disease, but not colchicine monotherapy.

Cyclosporine can be considered in patients with recalcitrant moderate-to-severe HS who have failed or are not candidates for standard therapy.

Short-term pulse steroid therapy can be considered for acute flares or to bridge patients to other treatment.

Long-term systemic corticosteroids tapered to the lowest possible dose can be considered in cases of severe HS, as an adjunct therapy in patients with suboptimal response to standard therapy.

HS, Hidradenitis suppurativa.

Table VII. Recommendations for biologics

Adalimumab at the approved HS dosing is recommended to improve disease severity and quality of life in patients with moderate-to-severe HS.

Infliximab is recommended for moderate-to-severe disease; however, dose-ranging studies are needed to determine the optimal dosage for management.

Anakinra, 100 mg daily, may be effective for HS; however, dose-ranging studies are needed to determine the optimal dosage for management.

Ustekinumab, 45 to 90 mg administered every 12 weeks, may be effective for HS; however, placebo-controlled dose-ranging studies are needed to determine the optimal dosage for management.

The limited available evidence does not support etanercept for the management of HS.

HS, Hidradenitis suppurativa.

of 20 patients with mostly Hurley stage I or/II disease were treated with minocycline, 100 mg daily, and colchicine, 0.5 mg twice daily for 6 months, followed by colchicine alone for 3 months. All improved according to their HS-PGA score.⁹ This combination may be useful in some patients, but existing evidence does not support colchicine monotherapy.

Systemic steroids were studied in a case series of 13 patients with moderate-to-severe HS. Six (46.2%) had a partial response and 5 (38.5%) had a good response with the addition of 10 mg of prednisone to

their existing treatment, including all 5 patients who did not initially respond to adalimumab.⁴⁶ Many experts use prednisone pulses or multiweek tapers starting at 0.5 to 1 mg/kg daily as rescue therapy for flares or to bridge to other long-term therapy. The effect is rapid and substantial, but side effects limit prolonged use.

BIOLOGICS IN HS

Immunomodulation is rapidly becoming the cornerstone of therapy for moderate-to-severe HS (Table VII). There is interest in targeting the tumor necrosis factor (TNF), interleukin 1 (IL-1), IL-12/type 1 helper T-cell, and IL-23/type 17 helper T-cell pathways as potential therapies.¹⁰⁶ Adalimumab is approved by the US Food and Drug Administration (FDA) for treating moderate-to-severe HS, and the results of small studies evaluating other biologics are promising. Primary limitations include considerable variability and validity of end points, lack of dose-ranging studies,¹⁰⁶ and short follow-up periods.

TNF inhibitors

Adalimumab. Adalimumab is currently the only FDA-approved treatment for HS.^{107,108} Early case reports and open-label trials demonstrated mixed results.^{51-66,109,110} In 4 larger placebo-controlled trials, adalimumab, 40 mg every other week, failed to achieve primary efficacy end points.⁴⁸⁻⁵⁰

A subsequent phase 2 double-blinded trial randomized 154 patients to adalimumab 40 mg every other week, 40 mg weekly, or placebo. The primary end point of HS-PGA score of clear, minimal, or mild at 16 weeks was achieved by 3.9% with placebo, 9.6% with every-other-week dosing, and 17.6% with weekly dosing.

Following this, 2 parallel double-blind placebo-controlled phase 3 trials (PIONEER 1 and PIONEER 2) evaluated a primary end point of Hidradenitis Suppurativa Clinical Response (HiSCR) at 12 weeks with either placebo or adalimumab, 160 mg at week 0, 80 mg at week 2, and then 40 mg weekly starting at week 4. In PIONEER 2, 19% of patients continued treatment with concomitant tetracycline-class antibiotics during the clinical trial period.⁴⁹

Week 12 HiSCR responses for adalimumab versus placebo, respectively, were 42% versus 26% ($P = .003$) in PIONEER 1 and 59% versus 28% in PIONEER 2. Almost half of the week 12 responders lost response at week 36 despite weekly maintenance dosing, compared with three-quarters of those who switched to placebo at 12 weeks.⁴⁹ Conversely, of the nonresponders at 12 weeks who were taking adalimumab, almost 40% achieved a response at 36 weeks with continued treatment.⁴⁹

A supplemental complete review of safety considerations of biologics is beyond the scope of these guidelines, but focused recommendations are provided at www.hs-foundation.org.

Infliximab. A single-center double-blind placebo-controlled trial of infliximab, 5 mg/kg ($n = 15$), versus placebo ($n = 18$) at weeks 0, 2, and 6, and then every 8 weeks with open-label crossover at week 8 demonstrated that 4 of 15 patients receiving infliximab (27%) versus 1 of 18 patients receiving placebo (5%) achieved the primary end point of a 50% or greater decrease in HS Severity Index score at 8 weeks; however, this difference did not reach statistical significance ($P = .092$). Post hoc analyses indicated that 13 of 15 patients receiving infliximab and 2 of 18 patients receiving placebo achieved a 25% or greater improvement in Hidradenitis Suppurativa Severity Index score at week 8. Significant differences in improvement were demonstrated for DLQI score, pain VAS score, and mean PGA score.⁶⁷

In a subsequent case series with systematic review,⁷⁵ response (which was defined as a 50% or greater decrease in the Hidradenitis Suppurativa Score) was reached by 55 of 71 patients (78%).

Optimal dosing of infliximab for patients with HS has yet to be established. One study¹¹¹ suggests that 5-mg/kg dosing every 4 weeks is superior to every-8-weeks dosing. Expert experience suggests that titration to doses of 10 mg/kg every 4 to 8 weeks may be necessary for optimal control.

Etanercept. The data supporting etanercept in HS are conflicting, and the evaluated doses range from 50 to 100 mg weekly. Low-level evidence suggests efficacy based on incompletely validated outcome measures, but a single-center randomized double-blind placebo-controlled study of etanercept, 50 mg twice weekly ($n = 10$), versus placebo ($n = 10$) demonstrated no statistically significant improvement in either patient- or physician-reported outcomes.⁸⁸ Three prospective open-label trials that included a total of 31 subjects demonstrated mixed results.³⁴⁻³⁶

Golimumab. The data supporting use of golimumab are limited to 2 case reports. In 1 report, nonresponse was noted with 50 mg every 4 weeks. In the other, ulcerative colitis dosing with 200 mg at week 0 and then 100 mg every 4 weeks starting at week 2 was helpful and indicates that higher dosing may be needed for HS.⁷⁸

IL-1 inhibitors

Anakinra. In a placebo-controlled RCT of 20 participants, 6 of 10 participants treated with anakinra, 100 mg daily, reported a reduction in non-validated HS disease activity score at 12 weeks

Table VIII. Recommendations for pediatric and pregnant patients

Perform laboratory evaluation for precocious puberty in pediatric patients with HS who are age 11 or younger when other suspicious physical examination findings are present.

Avoid tetracyclines in children younger than 9 years and acitretin in female patients during the childbearing years.

Avoid retinoids, hormonal agents, most systemic antibiotics, and most immunosuppressive medications in pregnant patients.

Use topical treatments, procedures, and safe systemic agents in pregnant patients.

HS, Hidradenitis suppurativa.

compared with 2 of 10 treated with placebo.⁷⁹ HiSCR was retrospectively assessed and achieved at 12 weeks in 7 of 9 patients receiving anakinra versus in 3 of 10 treated with placebo. Changes in modified Sartorius score, DLQI score, and VAS scores for disease severity and pain did not differ significantly from 0 to 12 weeks between treatment groups. Another open-label pilot study reported 5 of 6 patients achieving significant decreases in modified Sartorius score and DLQI score after 8 weeks of anakinra, 100 mg daily.⁸⁰ Four additional cases reports showed mixed results.^{78,81,82}

Anakinra should generally be considered only after failed response to TNF inhibition.

IL-12/IL-23 inhibitors

Ustekinumab. Ustekinumab is a human monoclonal antibody directed against the p40 subunit of IL-12 and IL-23.

In an open-label study of 17 subjects with moderate-to-severe HS who were receiving ustekinumab, 45 mg (or 90 mg if weighing >100 kg) every 12 weeks, 14 subjects demonstrated a mean improvement of 46.3% in modified Sartorius score, and 8 subjects achieved a 50% reduction in inflammatory lesion count by week 40. The reductions in DLQI score and pain VAS score were not significant.⁸³ The patients in 6 additional case reports had variable responses.⁸⁴⁻⁸⁷ It is possible that higher dosing similar to that used in inflammatory bowel disease would be more successful in HS, but no data currently exist.

TREATMENT OF HS IN PEDIATRIC AND PREGNANT PATIENTS

The literature describing the treatment of pediatric HS is limited and skews toward severe disease,

though cross-sectional studies do not consistently report more advanced disease in pediatric patients.¹¹² Several authors recommend endocrinologic evaluation and suggest that pediatric HS may be more severe and affect more sites than adult HS does.¹¹²⁻¹¹⁵ However, given the limited data to support these suggestions, we first recommend a performing a complete physical examination of typical HS sites and looking for signs of metabolic syndrome and precocious puberty. Further evaluation and management steps should stem from history and examination findings.

The natural history and impact of management on pediatric HS are unclear, but the goal should be to minimize scarring, progression, and need for surgery.^{88,116,117} Discussions of prognosis should be open-minded, as early procedural interventions have potential for cure in some patients. Management strategies are similar to those for adults with some specific considerations outlined in [Table VIII](#).

Although it has not been studied, expert opinion indicates that HS severity may improve,^{99,118} worsen, or be unaffected by pregnancy.¹¹⁹ Treatment of HS in pregnant women requires special consideration of medication effects on the developing embryo. FDA recommendations on pregnancy/breastfeeding should be consulted before determining treatment in HS; nonetheless, most medications used in HS have not been studied for this purpose and the ultimate decision lies with patients and their providers.

In pregnant patients, topical treatments, procedural treatments, and possibly lifestyle modifications, should be considered first-line treatment, whereas systemic agents should be considered second-line treatment.¹²⁰ Retinoids and hormonal therapies are contraindicated, as are certain immunosuppressants.

CONCLUSION

HS management is often complex and requires balancing medical and surgical treatment options in addition to addressing the associated pain and psychiatric and medical comorbidities that accompany the disease. These guidelines aim to help clinicians make optimal treatment decisions, but standard of care management requires an individualized approach because rigorous evidence is unavailable for most interventions. The need for stronger evidence highlighted by the guidelines should direct future research to fill gaps in current evidence.

The committee would like to thank the external reviewers who provided valuable feedback, including Dr Wayne Gulliver, Dr Errol Prens, and Dr Hessel van der Zee.

REFERENCES

1. Clemmensen OJ. Topical treatment of hidradenitis suppurativa with clindamycin. *Int J Dermatol*. 1983;22(5):325-328.
2. Jemec GB, Wendelboe P. Topical clindamycin versus systemic tetracycline in the treatment of hidradenitis suppurativa. *J Am Acad Dermatol*. 1998;39(6):971-974.
3. Danesh MJ, Kimball AB. Pyrithione zinc as a general management strategy for hidradenitis suppurativa. *J Am Acad Dermatol*. 2015;73(5):e175.
4. Boer J, Jemec GB. Resorcinol peels as a possible self-treatment of painful nodules in hidradenitis suppurativa. *Clin Exp Dermatol*. 2010;35(1):36-40.
5. Mahmoud BH, Tierney E, Hexsel CL, Pui J, Ozog DM, Hamzavi IH. Prospective controlled clinical and histopathologic study of hidradenitis suppurativa treated with the long-pulsed neodymium:yttrium-aluminium-garnet laser. *J Am Acad Dermatol*. 2010;62(4):637-645.
6. Riis PT, Boer J, Prens EP, et al. Intralesional triamcinolone for flares of hidradenitis suppurativa (HS): a case series. *J Am Acad Dermatol*. 2016;75(6):1151-1155.
7. Fischer AH, Haskin A, Okoye GA. Patterns of antimicrobial resistance in lesions of hidradenitis suppurativa. *J Am Acad Dermatol*. 2017;76(2):309-313.e302.
8. Kipping HF. How I treat hidradenitis suppurativa. *Postgrad Med*. 1970;48(3):291-292.
9. Armyra K, Kouris A, Markantoni V, Katsambas A, Kontochristopoulos G. Hidradenitis suppurativa treated with tetracycline in combination with colchicine: a prospective series of 20 patients. *Int J Dermatol*. 2017;56(3):346-350.
10. Scheinfeld N. Why rifampin (rifampicin) is a key component in the antibiotic treatment of hidradenitis suppurativa: a review of rifampin's effects on bacteria, bacterial biofilms, and the human immune system. *Dermatol Online J*. 2016;22(6).
11. Bettoli V, Join-Lambert O, Nassif A. Antibiotic treatment of hidradenitis suppurativa. *Dermatol Clin*. 2016;34(1):81-89.
12. Bettoli V, Zauli S, Borghi A, et al. Oral clindamycin and rifampicin in the treatment of hidradenitis suppurativa-acne inversa: a prospective study on 23 patients. *J Eur Acad Dermatol Venereol*. 2014;28(1):125-126.
13. van der Zee HH, Boer J, Prens EP, Jemec GB. The effect of combined treatment with oral clindamycin and oral rifampicin in patients with hidradenitis suppurativa. *Dermatology*. 2009;219(2):143-147.
14. Gener G, Canoui-Poitaine F, Revuz JE, et al. Combination therapy with clindamycin and rifampicin for hidradenitis suppurativa: a series of 116 consecutive patients. *Dermatology*. 2009;219(2):148-154.
15. Mendonca CO, Griffiths CE. Clindamycin and rifampicin combination therapy for hidradenitis suppurativa. *Br J Dermatol*. 2006;154(5):977-978.
16. Ingram JR, Woo PN, Chua SL, et al. Interventions for hidradenitis suppurativa. *Cochrane Database Syst Rev*. 2015;(10):CD010081.
17. Join-Lambert O, Coignard H, Jais JP, et al. Efficacy of rifampin-moxifloxacin-metronidazole combination therapy in hidradenitis suppurativa. *Dermatology*. 2011;222(1):49-58.
18. Yazdanyar S, Boer J, Ingvarsson G, Szepietowski JC, Jemec GB. Dapsone therapy for hidradenitis suppurativa: a series of 24 patients. *Dermatology*. 2011;222(4):342-346.
19. Kaur MR, Lewis HM. Hidradenitis suppurativa treated with dapsone: a case series of five patients. *J Dermatolog Treat*. 2006;17(4):211-213.
20. Join-Lambert O, Coignard-Biehler H, Jais JP, et al. Efficacy of ertapenem in severe hidradenitis suppurativa: a pilot study in a cohort of 30 consecutive patients. *J Antimicrob Chemother*. 2016;71(2):513-520.
21. Scheinfeld N. Extensive hidradenitis suppurativa (HS) Hurly stage III disease treated with intravenous (IV) linezolid and meropenem with rapid remission. *Dermatol Online J*. 2015;21(2).
22. Mortimer PS, Dawber RP, Gales MA, Moore RA. A double-blind controlled cross-over trial of cyproterone acetate in females with hidradenitis suppurativa. *Br J Dermatol*. 1986;115(3):263-268.
23. Kraft JN, Searles GE. Hidradenitis suppurativa in 64 female patients: retrospective study comparing oral antibiotics and antiandrogen therapy. *J Cutan Med Surg*. 2007;11(4):125-131.
24. Lee A, Fischer G. A case series of 20 women with hidradenitis suppurativa treated with spironolactone. *Australas J Dermatol*. 2015;56(3):192-196.
25. Verdolini R, Clayton N, Smith A, Alwash N, Mannello B. Metformin for the treatment of hidradenitis suppurativa: a little help along the way. *J Eur Acad Dermatol Venereol*. 2013;27(9):1101-1108.
26. Khandalavala BN, Do MV. Finasteride in hidradenitis suppurativa: a "male" therapy for a predominantly "female" disease. *J Clin Aesthet Dermatol*. 2016;9(6):44-50.
27. Boer J, van Gemert MJ. Long-term results of isotretinoin in the treatment of 68 patients with hidradenitis suppurativa. *J Am Acad Dermatol*. 1999;40(1):73-76.
28. Dicken CH, Powell ST, Spear KL. Evaluation of isotretinoin treatment of hidradenitis suppurativa. *J Am Acad Dermatol*. 1984;11(3):500-502.
29. Huang CM, Kirchhof MG. A new perspective on isotretinoin treatment of hidradenitis suppurativa: a retrospective chart review of patient outcomes. *Dermatology*. 2017;233(2-3):120-125.
30. Norris JF, Cunliffe WJ. Failure of treatment of familial widespread hidradenitis suppurativa with isotretinoin. *Clin Exp Dermatol*. 1986;11(6):579-583.
31. Poli F, Wolkenstein P, Revuz J. Back and face involvement in hidradenitis suppurativa. *Dermatology*. 2010;221(2):137-141.
32. Soria A, Canoui-Poitaine F, Wolkenstein P, et al. Absence of efficacy of oral isotretinoin in hidradenitis suppurativa: a retrospective study based on patients' outcome assessment. *Dermatology*. 2009;218(2):134-135.
33. Boer J, Nazary M. Long-term results of acitretin therapy for hidradenitis suppurativa. Is acne inversa also a misnomer? *Br J Dermatol*. 2011;164(1):170-175.
34. Matusiak L, Bieniek A, Szepietowski JC. Acitretin treatment for hidradenitis suppurativa: a prospective series of 17 patients. *Br J Dermatol*. 2014;171(1):170-174.
35. Puri N, Talwar A. A study on the management of hidradenitis suppurativa with retinoids and surgical excision. *Indian J Dermatol*. 2011;56(6):650-651.
36. Tan MG, Shear NH, Walsh S, Alhusayen R. Acitretin. *J Cutan Med Surg*. 2017;21(1):48-53.
37. Verdolini R, Simonacci F, Menon S, Pavlou P, Mannello B. Alitretinoin: a useful agent in the treatment of hidradenitis suppurativa, especially in women of child-bearing age. *G Ital Dermatol Venereol*. 2015;150(2):155-162.
38. Jemec GB. Methotrexate is of limited value in the treatment of hidradenitis suppurativa. *Clin Exp Dermatol*. 2002;27(6):528-529.
39. Nazary M, Prens EP, Boer J. Azathioprine lacks efficacy in hidradenitis suppurativa: a retrospective study of nine patients. *Br J Dermatol*. 2016;174(3):639-641.
40. van der Zee HH, Prens EP. The anti-inflammatory drug colchicine lacks efficacy in hidradenitis suppurativa. *Dermatology*. 2011;223(2):169-173.

41. Anderson MD, Zauli S, Bettoli V, Boer J, Jemec GB. Cyclosporine treatment of severe hidradenitis suppurativa—a case series. *J Dermatolog Treat*. 2016;27(3):247-250.
42. Gupta AK, Ellis CN, Nickloff BJ, et al. Oral cyclosporine in the treatment of inflammatory and noninflammatory dermatoses. A clinical and immunopathologic analysis. *Arch Dermatol*. 1990;126(3):339-350.
43. Buckley DA, Rogers S. Cyclosporin-responsive hidradenitis suppurativa. *J R Soc Med*. 1995;88(5):289P-290P.
44. Bianchi L, Hansel K, Stingeni L. Recalcitrant severe hidradenitis suppurativa successfully treated with cyclosporine A. *J Am Acad Dermatol*. 2012;67(6):e278-279.
45. Staub J, Pfannschmidt N, Strohal R, et al. Successful treatment of PASH syndrome with infliximab, cyclosporine and dapsone. *J Eur Acad Dermatol Venereol*. 2015;29(11):2243-2247.
46. Wong D, Walsh S, Alhusayen R. Low-dose systemic corticosteroid treatment for recalcitrant hidradenitis suppurativa. *J Am Acad Dermatol*. 2016;75(5):1059-1062.
47. Rose RF, Goodfield MJ, Clark SM. Treatment of recalcitrant hidradenitis suppurativa with oral ciclosporin. *Clin Exp Dermatol*. 2006;31(1):154-155.
48. Kimball AB, Kerdel F, Adams D, et al. Adalimumab for the treatment of moderate to severe hidradenitis suppurativa: a parallel randomized trial. *Annals Intern Med*. 2012;157(12):846-855.
49. Kimball AB, Okun MM, Williams DA, et al. Two phase 3 trials of adalimumab for hidradenitis suppurativa. *N Engl J Med*. 2016;375(5):422-434.
50. Miller I, Lynggaard CD, Lophaven S, Zachariae C, Dufour DN, Jemec GB. A double-blind placebo-controlled randomized trial of adalimumab in the treatment of hidradenitis suppurativa. *Br J Dermatol*. 2011;165(2):391-398.
51. Amano M, Grant A, Kerdel FA. A prospective open-label clinical trial of adalimumab for the treatment of hidradenitis suppurativa. *Int J Dermatol*. 2010;49(8):950-955.
52. Arenbergerova M, Gkalpakiotis S, Arenberger P. Effective long-term control of refractory hidradenitis suppurativa with adalimumab after failure of conventional therapy. *Int J Dermatol*. 2010;49(12):1445-1449.
53. Bahillo Monné C, Honorato Guerra S, Schoendorff Ortega C, Gargallo Quintero AB. Management of hidradenitis suppurativa with biological therapy: report of four cases and review of the literature. *Dermatology*. 2014;229(4):279-287.
54. Blanco R, Martinez-Taboada VM, Villa I, et al. Long-term successful adalimumab therapy in severe hidradenitis suppurativa. *Arch Dermatol*. 2009;145(5):580-584.
55. Bosnić D, Žarković B, Baresić M, Zarkovic M, Anic B. Improvement of overlapping hidradenitis suppurativa and ankylosing spondylitis after the introduction of adalimumab. *Reumatologia*. 2016;54(6):321-325.
56. Diamantova D, Lomickova I, Cetkovska P. Adalimumab treatment for hidradenitis suppurativa associated with Crohn's disease. *Acta Dermatovenerol Croat*. 2014;22(4):291-293.
57. Gorovoy I, Berghoff A, Ferris L. Successful treatment of recalcitrant hidradenitis suppurativa with adalimumab. *Case Rep Dermatol*. 2009;1(1):71-77.
58. Harde V, Mrowietz U. Treatment of severe recalcitrant hidradenitis suppurativa with adalimumab. *J Dtsch Dermatol Ges*. 2009;7(2):139-141.
59. Koilakou S, Karapiperis D, Tzathas C. A case of hidradenitis suppurativa refractory to anti-TNFalpha therapy in a patient with Crohn's disease. *Am J Gastroenterol*. 2010;105(1):231-232.
60. Murphy B, Morrison G, Podmore P. Successful use of adalimumab to treat pyoderma gangrenosum, acne and suppurative hidradenitis (PASH syndrome) following colectomy in ulcerative colitis. *Int J Colorectal Dis*. 2015;30(8):1139-1140.
61. Reddick CL, Singh MN, Chalmers RJ. Successful treatment of superficial pyoderma gangrenosum associated with hidradenitis suppurativa with adalimumab. *Dermatol Online J*. 2010;16(8):15.
62. Saraceno R, Babino G, Chiricozzi A, Zangrilli A, Chimenti S. PsAPASH: a new syndrome associated with hidradenitis suppurativa with response to tumor necrosis factor inhibition. *J Am Acad Dermatol*. 2015;72(1):e42-44.
63. Scheinfeld N. Treatment of coincident seronegative arthritis and hidradenitis suppurativa with adalimumab. *J Am Acad Dermatol*. 2006;55(1):163-164.
64. Sotiriou E, Goussi C, Lallas A, et al. A prospective open-label clinical trial of efficacy of the every week administration of adalimumab in the treatment of hidradenitis suppurativa. *J Drugs Dermatol*. 2012;11(5 Suppl):s15-s20.
65. van Rappard DC, Leenarts MF, Meijerink-van 't Oost L, Mekkes JR. Comparing treatment outcome of infliximab and adalimumab in patients with severe hidradenitis suppurativa. *J Dermatolog Treat*. 2012;23(4):284-289.
66. Yamauchi PS, Mau N. Hidradenitis suppurativa managed with adalimumab. *J Drugs Dermatol*. 2009;8(2):181-183.
67. Grant A, Gonzalez T, Montgomery MO, Cardenas V, Kerdel FA. Infliximab therapy for patients with moderate to severe hidradenitis suppurativa: a randomized, double-blind, placebo-controlled crossover trial. *J Am Acad Dermatol*. 2010;62(2):205-217.
68. van Rappard DC, Mooij JE, Baeten DL, Mekkes JR. New-onset polyarthritis during successful treatment of hidradenitis suppurativa with infliximab. *Br J Dermatol*. 2011;165(1):194-198.
69. Brunasso AM, Delfino C, Massone C. Hidradenitis suppurativa: are tumour necrosis factor-alpha blockers the ultimate alternative? *Br J Dermatol*. 2008;159(3):761-763.
70. Delage M, Samimi M, Atlan M, Mchet L, Lorette G, Maruani A. Efficacy of infliximab for hidradenitis suppurativa: assessment of clinical and biological inflammatory markers. *Acta Dermatovenerol*. 2011;91(2):169-171.
71. Fardet L, Dupuy A, Kerob D, et al. Infliximab for severe hidradenitis suppurativa: transient clinical efficacy in 7 consecutive patients. *J Am Acad Dermatol*. 2007;56(4):624-628.
72. Fernandez-Vozmediano JM, Armario-Hita JC. Infliximab for the treatment of hidradenitis suppurativa. *Dermatology*. 2007;215(1):41-44.
73. Lasocki A, Sinclair R, Foley P, Saunders H. Hidradenitis suppurativa responding to treatment with infliximab. *Australas J Dermatol*. 2010;51(3):186-190.
74. Mekkes JR, Bos JD. Long-term efficacy of a single course of infliximab in hidradenitis suppurativa. *Br J Dermatol*. 2008;158(2):370-374.
75. Paradela S, Rodriguez-Lojo R, Fernandez-Torres R, Arevalo P, Fonseca E. Long-term efficacy of infliximab in hidradenitis suppurativa. *J Dermatolog Treat*. 2012;23(4):278-283.
76. Pedraz J, Dauden E, Perez-Gala S, Goiriz-Valdes R, Fernandez-Penas P, Garcia-Diez A. [Hidradenitis suppurativa. Response to treatment with infliximab]. *Actas Dermosifiliograf*. 2007;98(5):325-331.
77. Usmani N, Clayton TH, Everett S, Goodfield MD. Variable response of hidradenitis suppurativa to infliximab in four patients. *Clin Exp Dermatol*. 2007;32(2):204-205.
78. van der Zee HH, Prens EP. Failure of anti-interleukin-1 therapy in severe hidradenitis suppurativa: a case report. *Dermatology*. 2013;226(2):97-100.
79. Tzanetakou V, Kanni T, Giatrakou S, et al. Safety and efficacy of anakinra in severe hidradenitis suppurativa: a randomized clinical trial. *JAMA Dermatol*. 2016;152(1):52-59.

80. Leslie KS, Tripathi SV, Nguyen TV, Pauli M, Rosenblum MD. An open-label study of anakinra for the treatment of moderate to severe hidradenitis suppurativa. *J Am Acad Dermatol.* 2014;70(2):243-251.
81. Zarchi K, Dufour DN, Jemec GB. Successful treatment of severe hidradenitis suppurativa with anakinra. *JAMA Dermatol.* 2013;149(10):1192-1194.
82. Menis D, Maronas-Jimenez L, Delgado-Marquez AM, Postigo-Llorente C, Vanaclocha-Sebastian F. Two cases of severe hidradenitis suppurativa with failure of anakinra therapy. *Br J Dermatol.* 2015;172(3):810-811.
83. Blok JL, Li K, Brodmerkel C, Horvatovich P, Jonkman MF, Horvath B. Ustekinumab in hidradenitis suppurativa: clinical results and a search for potential biomarkers in serum. *Br J Dermatol.* 2016;174(4):839-846.
84. Gulliver WP, Jemec GB, Baker KA. Experience with ustekinumab for the treatment of moderate to severe hidradenitis suppurativa. *J Eur Acad Dermatol Venereol.* 2012;26(7):911-914.
85. Santos-Perez MI, Garcia-Rodicio S, Del Olmo-Revuelto MA, Pozo-Roman T. Ustekinumab for hidradenitis suppurativa: a case report. *Actas Dermosifiliogr.* 2014;105(7):720-722.
86. Sharon VR, Garcia MS, Bagheri S, et al. Management of recalcitrant hidradenitis suppurativa with ustekinumab. *Acta Derm Venereol.* 2012;92(3):320-321.
87. Baerveldt EM, Kappen JH, Thio HB, van Laar JA, van Hagen PM, Prens EP. Successful long-term triple disease control by ustekinumab in a patient with Behcet's disease, psoriasis and hidradenitis suppurativa. *Ann Rheum Dis.* 2013;72(4):626-627.
88. Adams DR, Yankura JA, Fogelberg AC, Anderson BE. Treatment of hidradenitis suppurativa with etanercept injection. *Arch Dermatol.* 2010;146(5):501-504.
89. Pelekanou A, Kanni T, Savva A, et al. Long-term efficacy of etanercept in hidradenitis suppurativa: results from an open-label phase II prospective trial. *Exp Dermatol.* 2010;19(6):538-540.
90. Lee RA, Dommasch E, Treat J, et al. A prospective clinical trial of open-label etanercept for the treatment of hidradenitis suppurativa. *J Am Acad Dermatol.* 2009;60(4):565-573.
91. Giamarellos-Bourboulis EJ, Pelekanou E, Antonopoulou A, et al. An open-label phase II study of the safety and efficacy of etanercept for the therapy of hidradenitis suppurativa. *Br J Dermatol.* 2008;158(3):567-572.
92. Cusack C, Buckley C. Etanercept: effective in the management of hidradenitis suppurativa. *Br J Dermatol.* 2006;154(4):726-729.
93. Sotiriou E, Apalla Z, Ioannidis D. Etanercept for the treatment of hidradenitis suppurativa. *Acta Derm Venereol.* 2009;89(1):82-83.
94. Tursi A. Concomitant hidradenitis suppurativa and pyostomatitis vegetans in silent ulcerative colitis successfully treated with golimumab. *Dig Liver Dis.* 2016;48(12):1511-1512.
95. Ebell MH, Siwek J, Weiss BD, et al. Strength of recommendation taxonomy (SORT): a patient-centered approach to grading evidence in the medical literature. *Am Fam Physician.* 2004;69(3):548-556.
96. Alavi A, Kirsner RS. Local wound care and topical management of hidradenitis suppurativa. *J Am Acad Dermatol.* 2015;73(5 Suppl 1):S55-S61.
97. Bettoli V, Zauli S, Virgili A. Oral clindamycin and rifampicin in the treatment of hidradenitis suppurativa-acne inversa: can some factors influence the response to the treatment? *G Ital Dermatol Venereol.* 2016;151(2):216-218.
98. Riis PT, Ring HC, Themstrup L, Jemec GB. The role of androgens and estrogens in hidradenitis suppurativa - a systematic review. *Acta Dermatovenerol Croat.* 2016;24(4):239-249.
99. Vossen AR, van Straalen KR, Prens EP, van der Zee HH. Menses and pregnancy affect symptoms in hidradenitis suppurativa: a cross-sectional study. *J Am Acad Dermatol.* 2017;76(1):155-156.
100. Alikhan A, Lynch PJ, Eisen DB. Hidradenitis suppurativa: a comprehensive review. *J Am Acad Dermatol.* 2009;60(4):539-561. quiz 562-533.
101. Danby FW, Jemec GB, Marsch W, von Laffert M. Preliminary findings suggest hidradenitis suppurativa may be due to defective follicular support. *Br J Dermatol.* 2013;168(5):1034-1039.
102. Wolverson SE. *Comprehensive Dermatologic Drug Therapy.* 3rd ed. Edinburgh: Saunders/Elsevier; 2013.
103. Nazary M, van der Zee HH, Prens EP, Folkerts G, Boer J. Pathogenesis and pharmacotherapy of hidradenitis suppurativa. *Eur J Pharmacol.* 2011;672(1-3):1-8.
104. Cronstein BN, Naime D, Ostad E. The antiinflammatory mechanism of methotrexate. Increased adenosine release at inflamed sites diminishes leukocyte accumulation in an in vivo model of inflammation. *J Clin Invest.* 1993;92(6):2675-2682.
105. Kalb RE, Strober B, Weinstein G, Lebwohl M. Methotrexate and psoriasis: 2009 National Psoriasis Foundation Consensus Conference. *J Am Acad Dermatol.* 2009;60(5):824-837.
106. Hoffman LK, Ghias MH, Lowes MA. Pathophysiology of hidradenitis suppurativa. *Semin Cutan Med Surg.* 2017;36(2):47-54.
107. *Humira (adalimumab) [package insert].* Chicago, IL: AbbVie Inc.; 2017.
108. Perng P, Zampella JG, Okoye GA. Management of hidradenitis suppurativa in pregnancy. *J Am Acad Dermatol.* 2017;76(5):979-989.
109. Zouboulis CC, Desai N, Emtestam L, et al. European S1 guideline for the treatment of hidradenitis suppurativa/acne inversa. *J Eur Acad Dermatol Venereol.* 2015;29(4):619-644.
110. Moul DK, Korman NJ. The cutting edge. Severe hidradenitis suppurativa treated with adalimumab. *Arch Dermatol.* 2006;142(9):1110-1112.
111. Moriarty B, Jiyad Z, Creamer D. Four-weekly infliximab in the treatment of severe hidradenitis suppurativa. *Br J Dermatol.* 2014;170(4):986-987.
112. Liy-Wong C, Pope E, Lara-Corrales I. Hidradenitis suppurativa in the pediatric population. *J Am Acad Dermatol.* 2015;73(5 Suppl 1):S36-S41.
113. Deckers IE, van der Zee HH, Boer J, Prens EP. Correlation of early-onset hidradenitis suppurativa with stronger genetic susceptibility and more widespread involvement. *J Am Acad Dermatol.* 2015;72(3):485-488.
114. Bettoli V, Ricci M, Zauli S, Virgili A. Hidradenitis suppurativa-acne inversa: a relevant dermatosis in paediatric patients. *Br J Dermatol.* 2015;173(5):1328-1330.
115. Palmer RA, Keefe M. Early-onset hidradenitis suppurativa. *Clin Exp Dermatol.* 2001;26(6):501-503.
116. Mikkelsen PR, Jemec GB. Hidradenitis suppurativa in children and adolescents: a review of treatment options. *Paediatr Drugs.* 2014;16(6):483-489.
117. Rambhatla PV, Lim HW, Hamzavi I. A systematic review of treatments for hidradenitis suppurativa. *Arch Dermatol.* 2012;148(4):439-446.
118. Combleet T. Pregnancy and apocrine gland diseases: hidradenitis, Fox-Fordyce disease. *AMA Arch Derm Syphilol.* 1952;65(1):12-19.
119. Kromann CB, Deckers IE, Esmann S, Boer J, Prens EP, Jemec GB. Risk factors, clinical course and long-term prognosis in hidradenitis suppurativa: a cross-sectional study. *Br J Dermatol.* 2014;171(4):819-824.
120. Pagliarello C, Fabrizi G, Feliciani C, Di Nuzzo S. Cryoinflation for Hurley stage II hidradenitis suppurativa: a useful treatment option when systemic therapies should be avoided. *JAMA Dermatol.* 2014;150(7):765-766.