



AMERICAN ACADEMY
OF OPHTHALMOLOGY®

Protecting Sight. Empowering Lives.®

Adult Strabismus Preferred Practice Pattern®

Secretary for Quality of Care
Timothy W. Olsen, MD

Academy Staff
Ali Al-Rajhi, PhD, MPH
Andre Ambrus, MLIS
Meghan Daly
Flora C. Lum, MD
Doris Mizuri

Medical Editor: Susan Garratt

Approved by: Board of Trustees
September 7, 2019

© 2019 American Academy of Ophthalmology®
All rights reserved

AMERICAN ACADEMY OF OPHTHALMOLOGY and PREFERRED PRACTICE PATTERN are registered trademarks of the American Academy of Ophthalmology. All other trademarks are the property of their respective owners.

Preferred Practice Pattern® guidelines are developed by the Academy's H. Dunbar Hoskins Jr., M.D. Center for Quality Eye Care without any external financial support. Authors and reviewers of the guidelines are volunteers and do not receive any financial compensation for their contributions to the documents. The guidelines are externally reviewed by experts and stakeholders before publication.

American Academy of Ophthalmology®
P. O. Box 7424
San Francisco, CA 94120-7424
415.561.8500

PEDIATRIC OPHTHALMOLOGY/ ADULT STRABISMUS PREFERRED PRACTICE PATTERN® DEVELOPMENT PROCESS AND

The **Pediatric Ophthalmology/Adult Strabismus Preferred Practice Pattern® Panel** of the American Association for Pediatric Ophthalmology and Strabismus Adult Strabismus Task Force members wrote the Adult Strabismus Preferred Practice Pattern® guidelines (“PPP”). The PPP Panel members discussed and reviewed successive drafts of the document, meeting in person and conducting other review by e-mail discussion, to develop a consensus over the final version of the document.

Pediatric Ophthalmology/Adult Strabismus Preferred Practice Pattern Panel of the American Association of Pediatric Ophthalmology and Strabismus 2017–2019

Chair Linda R. Dagi, MD
Vice Chair: Federico G. Velez, MD

Jonathan M. Holmes, MD
Steven M. Archer, MD
Stacy L. Pineles, MD
Mitchell B. Strominger, MD
Matthew Simon Pihlblad, MD
Evelyn A. Paysse, MD
David Stager Jr, MD
David R. Stager Sr, MD
Hatice Tuba Atalay, MD
Hilda Capo, MD
Natalie C. Kerr, MD
Burton J. Kushner, MD
Sarah E. MacKinnon, CO, COMT
Brian N. Campolattaro, MD
Jason H. Peragallo, MD
Reecha S. Bahl, MD

The **Preferred Practice Patterns Committee** members reviewed and discussed the document during a series of meetings spanning 2017-2019. The document was edited in response to the discussion and comments.

Preferred Practice Patterns Committee 2019

Robert S. Feder, MD, Chair
Roy S. Chuck, MD, PhD
Steven P. Dunn, MD
Christina J. Flaxel, MD
Steven J. Gedde, MD
Francis S. Mah, MD
Randall J. Olson, MD
David K. Wallace, MD, MPH
David C. Musch, PhD, MPH, Methodologist

The Adult Strabismus PPP was then sent for review to additional internal and external groups and individuals in August 2019. All those returning comments were required to provide disclosure of relevant relationships with industry to have their comments considered. Members of the Pediatric Ophthalmology/Strabismus Preferred Practice Pattern Panel reviewed and discussed these comments and determined revisions to the document. The following organizations and individuals returned comments.

FINANCIAL DISCLOSURES

In compliance with the Council of Medical Specialty Societies' Code for Interactions with Companies (available at www.cmss.org/codeforinteractions.aspx), relevant relationships with industry are listed. The Academy has Relationship with Industry Procedures to comply with the Code (available at www.aao.org/about-preferred-practice-patterns). A majority (75%) of the members of the Adult Strabismus Preferred Practice Pattern Panel 2017–2019 had no financial relationship to disclose.

Adult Strabismus Preferred Practice Pattern Panel 2017–2019

Steven M. Archer, MD: No financial relationships to disclose
 Hatice Tuba Atalay, MD: No financial relationships to disclose
 Reecha S. Bahl, MD:
 Brian N. Campolattaro, MD: No financial relationships to disclose
 Hilda Capo, MD: No financial relationships to disclose
 Linda R. Dagi, MD: Boston Neurosciences
 Jonathan M. Holmes, MD: Grant support from National Institutes of Health and Research to Prevent Blindness
 Natalie C. Kerr, MD: No financial relationships to disclose
 Burton J. Kushner, MD: NovaSight – Scientific Advisory Board member
 Sarah E. MacKinnon, CO, COMT: No financial relationships to disclose
 Evelyn A. Paysse, MD: No financial relationships to disclose
 Jason H. Pergallo, MD: No financial relationships to disclose
 Matthew Simon Pihlblad, MD: No financial relationships to disclose
 Stacy L. Pineles, MD: No financial relationships to disclose
 Mitchell B. Strominger, MD: No financial relationships to disclose
 David R. Stager Sr, MD: No financial relationships to disclose
 David Stager Jr, MD: No financial relationships to disclose
 Federico G. Velez, MD: Grant support from Omeros, Bausch+Lomb, Retrophin, Research to Prevent Blindness

Pediatric Ophthalmology/Strabismus Preferred Practice Patterns Committee 2019

David K. Wallace, MD, PhD: No financial relationships to disclose
 Stephen P. Christiansen, MD: No financial relationships to disclose
 Katherine A. Lee, MD, PhD: No financial relationships to disclose
 Christie L. Morse, MD: Grant Support from Luminopia
 Michael X. Repka, MD, MBA: No financial relationships to disclose
 Derek T. Sprunger, MD: No financial relationships to disclose
 Michele Melia, ScM: No financial relationships to disclose

Preferred Practice Patterns Committee 2019

Roy S. Chuck, MD, PhD: No financial relationships to disclose
 Steven P. Dunn, MD: No financial relationships to disclose
 Robert S. Feder, MD: No financial relationships to disclose
 Christina J. Flaxel, MD: No financial relationships to disclose
 Steven J. Gedde, MD: No financial relationships to disclose
 Francis S. Mah, MD: No financial relationships to disclose
 Randall J. Olson, MD: No financial relationships to disclose
 David K. Wallace, MD, MPH: No financial relationships to disclose
 David C. Musch, PhD, MPH: No financial relationships to disclose

Secretary for Quality of Care

Timothy W. Olsen, MD: No financial relationships to disclose

Academy Staff

Ali Al-Rajhi, PhD, MPH: No financial relationships to disclose
 Andre Ambrus, MLIS: No financial relationships to disclose
 Susan Garratt, Medical Editor: No financial relationships to disclose
 Meghan Daly: No financial relationships to disclose
 Flora C. Lum, MD: No financial relationships to disclose
 Doris Mizuiri: No financial relationships to disclose

The disclosures of relevant relationships to industry of other reviewers of the document from January to October 2019 are available online at www.aao.org/ppp

TABLE OF CONTENTS

OBJECTIVES OF PREFERRED PRACTICE PATTERN GUIDELINES	P332
METHODS AND KEY TO RATINGS	P333
HIGHLIGHTED FINDINGS & RECOMMENDATIONS FOR CARE	P334
SECTION I. ADULT STRABISMUS OVERVIEW	
INTRODUCTION	P335
Disease Definition.....	P336
Patient Population.....	P336
Clinical Objectives.....	P336
BACKGROUND	P336
Prevalence.....	P336
Rationale for Treatment.....	P336
SECTION II. COMMON AND CLINICALLY IMPORTANT MANIFESTATIONS OF ADULT STRABISMUS	
SECTION IIa. PERSISTENT OR RECURRENT CHILDHOOD STRABISMUS	
INTRODUCTION	P339
Disease Definition.....	P339
Patient Population.....	P339
Clinical Objectives.....	P340
BACKGROUND	P340
Prevalence.....	P340
Natural History.....	P340
Rationale for Treatment.....	P340
CARE PROCESS	P341
Patient Outcome Criteria.....	P341
Diagnosis.....	P341
History.....	P341
Examination.....	P341
Management.....	P343
Monitor/Observe.....	P343
Nonsurgical.....	P343
Surgical.....	P343
Provider and Setting.....	P343
Counseling and Referral.....	P343
SECTION IIb. SENSORY STRABISMUS	
INTRODUCTION	P344
Disease Definition.....	P344
Patient Population.....	P344
Clinical Objectives.....	P344
BACKGROUND	P344
Prevalence.....	P344
Natural History.....	P344
Rationale for Treatment.....	P345
CARE PROCESS	P345
Patient Outcome Criteria.....	P345
Diagnosis.....	P345
History.....	P345
Examination.....	P345
Management.....	P346
Monitor/Observe.....	P346
Nonsurgical.....	P346
Surgical.....	P346
Provider and Setting.....	P346
Counseling and Referral.....	P346
SECTION IIc. CONVERGENCE INSUFFICIENCY	
INTRODUCTION	P347
Disease Definition.....	P347
Patient Population.....	P347

Clinical Objectives	P347
BACKGROUND	P347
Incidence	P347
Risk Factors	P347
Natural History	P347
Rationale for Treatment	P348
CARE PROCESS	P348
Patient Outcome Criteria	P348
Diagnosis	P348
History	P348
Examination	P348
Management	P349
Monitor/Observe	P349
Nonsurgical	P349
Surgical	P349
Provider and Setting	P349
Counseling and Referral	P349
<hr/>	
SECTION II<i>d</i> ACQUIRED STRABISMUS RELATED TO AGING AND MYOPIA	
INTRODUCTION	P350
Disease Definition	P350
Divergence Insufficiency	P350
Sagging Eye Syndrome	P350
Strabismus fixus (“Heavy Eye Syndrome”)	P351
Patient Population	P351
Clinical Objectives	P351
BACKGROUND	P351
Prevalence and Risk Factors	P351
Divergence Insufficiency	P351
Sagging Eye Syndrome	P351
Strabismus fixus or “Heavy Eye”	P352
Natural History	P352
Rationale for Treatment	P352
CARE PROCESS	P352
Patient Outcome Criteria	P352
Diagnosis	P352
History	P352
Examination	P353
Management	P354
Divergence Insufficiency	P354
Sagging Eye Syndrome	P355
Strabismus fixus	P355
Provider and Setting	P356
Counseling and Referral	P356
Divergence Insufficiency/Sagging Eye Syndrome	P356
Strabismus fixus	P356
<hr/>	
SECTION II<i>e</i>. THYROID EYE DISEASE	
INTRODUCTION	P358
Disease Definition	P358
Patient Population	P358
Clinical Objectives	P358
BACKGROUND	P358
Incidence	P358
Risk Factors	P358
Natural History	P359
Rationale for Treatment	P359
CARE PROCESS	P359
Patient Outcome Criteria	P359
Diagnosis	P359
History	P359
Examination	P359
Management	P360

Observation	P361
Nonsurgical	P361
Surgical.....	P361
Provider and Setting	P363
Counseling and Referral	P363

SECTION II*f*. STRABISMUS AFTER ORBITAL TRAUMA

INTRODUCTION	P364
Disease Definition	P364
Patient Population.....	P364
Clinical Objectives	P364
BACKGROUND	P365
Prevalence and Risk Factors	P365
Natural History	P365
Rationale for Treatment.....	P365
CARE PROCESS	P365
Diagnosis.....	P365
History	P365
Examination.....	P365
Management.....	P366
General Guidelines	P366
Guidelines for Treating Strabismus	P367
Provider and Setting	P368
Counseling and Referral	P368

SECTION II*g*. STRABISMUS ASSOCIATED WITH OTHER OPHTHALMIC SURGERY

INTRODUCTION	P369
Disease Definition	
Cataract Extraction or Keratoplasty.....	P369
Glaucoma Filtering Procedures (including trabeculectomy and glaucoma plate reservoir surgery)	P370
Scleral Buckling Procedures.....	P370
Pterygium Surgery.....	P370
Blepharoplasty and Eyelid Procedures	P370
Patient Population.....	P371
Clinical Objectives	P371
BACKGROUND	P371
Cataract Extraction	P371
Glaucoma Filtering Procedures	P371
Scleral Buckling Procedures.....	P372
Blepharoplasty and Eyelid Procedures	P372
Natural History.....	P372
Rationale for Treatment.....	P372
CARE PROCESS	P373
Patient Outcome Criteria	P373
Diagnosis.....	P373
History	P373
Examination.....	P373
Management.....	P374
Monitor/Observe.....	P374
Nonsurgical	P374
Surgical.....	P374
Provider and Setting	P375
Counseling and Referral	P375

SECTION III*h*. SUPERIOR OBLIQUE PALSY

INTRODUCTION	P376
Disease Definition	P376
Patient Population.....	P376
Clinical Objectives	P376
BACKGROUND	P377
Incidence	P377
Risk Factors.....	P377
Natural History.....	P377
Rationale for Treatment.....	P377
CARE PROCESS	P377

Patient Outcome Criteria	P377
Diagnosis	P377
History	P377
Examination	P378
Management	P378
Monitor/Observe	P378
Nonsurgical	P378
Surgical	P378
Provider and Setting	P379
Counseling and Referral	P379

SECTION III. SKEW DEVIATION

INTRODUCTION	P380
Disease Definition	P380
Patient Population	P381
Clinical Objectives	P381
BACKGROUND	P381
Prevalence	P381
Risk Factors	P381
Natural History	P381
Rationale for Treatment	P381
CARE PROCESS	P381
Patient Outcome Criteria	P381
Diagnosis	P382
History	P382
Examination	P382
Management	P383
Provider and Setting	P383
Counseling and Referral	P383

SECTION IIj. ABDUCENS PALSY

INTRODUCTION	P384
Disease Definition	P384
Patient Population	P385
Clinical Objectives	P385
BACKGROUND	P385
Incidence	P385
Risk Factors	P385
Rationale for Treatment	P385
CARE PROCESS	P385
Patient Outcome Criteria	P385
Diagnosis	P385
History	P386
Examination	P386
Ancillary Testing	P386
Management	P387
Monitor/Observe	P387
Nonsurgical	P387
Surgical	P387
Provider and Setting	P388
Counseling and Referral	P388

SECTION IIIk. OCULOMOTOR PALSY

INTRODUCTION	P389
Disease Definition	P389
Patient Population	P389
Clinical Objectives	P389
BACKGROUND	P389
Incidence	P389
Risk Factors	P389
Rationale for Treatment	P390
CARE PROCESS	P390
Patient Outcome Criteria	P390
Diagnosis	P390
History	P391

Examination.....	P391
Management.....	P392
Monitor/Observe.....	P392
Nonsurgical.....	P392
Surgical.....	P392
Provider and Setting.....	P393
Counseling and Referral.....	P393

SECTION III. MYASTHENIA GRAVIS

INTRODUCTION	P394
Disease Definition.....	P394
Patient Population.....	P394
Clinical Objectives.....	P394
BACKGROUND	P395
Prevalence.....	P395
Risk Factors.....	P395
Natural History.....	P395
Rationale for Treatment.....	P395
CARE PROCESS	P395
Patient Outcome Criteria.....	P395
Diagnosis.....	P395
History.....	P396
Examination.....	P396
Management.....	P397
Provider and Setting.....	P397
Counseling and Referral.....	P397

SECTION II*m*. FIXATION SWITCH DIPLOPIA

INTRODUCTION	P398
Disease Definition.....	P398
Patient Population.....	P398
Clinical Objectives.....	P398
BACKGROUND	P398
Prevalence and Risk Factors.....	P398
Natural History.....	P399
Rationale for Treatment.....	P399
CARE PROCESS	P399
Patient Outcome Criteria.....	P399
Diagnosis.....	P399
History.....	P399
Examination.....	P400
Management.....	P400
Monitor/Observe.....	P400
Nonsurgical.....	P400
Surgical.....	P400
Provider and Setting.....	P400
Counseling and Referral.....	P401

SECTION II*n*. RETINAL MISREGISTRATION (BINOCULAR RETINAL DIPLOPIA)

INTRODUCTION	P402
Disease Definition.....	P402
Patient Population.....	P402
Clinical Objectives.....	P402
BACKGROUND	P402
Prevalence and Risk Factors.....	P402
Natural History.....	P402
Rationale for Treatment.....	P403
CARE PROCESS	P403
Patient Outcome Criteria.....	P403
Diagnosis.....	P403
History.....	P403
Examination.....	P403

Management.....	P404
Monitor/Observe.....	P404
Nonsurgical.....	P404
Surgical.....	P404
Provider and Setting.....	P405
Counseling and Referral.....	P405
<hr/>	
<i>SECTION III. COMPLICATIONS OF PERFORMING ADULT STRABISMUS SURGERY</i>	
INTRODUCTION.....	P406
BACKGROUND.....	P406
Prevalence and Risk Factors.....	P406
CARE PROCESS.....	P406
Postoperative Concerns.....	P406
Mild Concerns.....	P406
Moderate Concerns.....	P407
Major Concerns.....	P407
Provider and Setting.....	P408
Counseling and Referral.....	P408
<hr/>	
<i>SECTION IV. TECHNICAL CONSIDERATIONS WHEN PERFORMING ADULT STRABISMUS SURGERY</i>	
INTRODUCTION.....	P409
CARE PROCESS.....	P409
Surgical Planning and Management.....	P409
Anticoagulants.....	P409
Adjustable Sutures.....	P409
Microtropias.....	P410
Chemodenervation.....	P410
Anesthesia.....	P410
Complex Strabismus.....	P410
Intraoperative Issues.....	P411
Provider and Setting.....	P411
Counseling and Referral.....	P411
APPENDIX 1. GLOSSARY OR TERMS.....	P412
APPENDIX 2. ALGORITHM FOR APPROACHING ADULT STRABISMUS BASED ON PRESENTATION OF DEVIATION.....	P413
APPENDIX 3. LITERATURE SEARCHES FOR THIS PPP.....	P414
APPENDIX 4. RELATED ACADEMY MATERIALS.....	P415
REFERENCES.....	P416

Background:

Strabismus has an estimated incidence of 4% in the adult population. Commonest causes include unresolved or recurrent childhood strabismus, sensory strabismus, divergence insufficiency or sagging eye syndrome, Graves orbitopathy, 4th and 6th cranial nerve palsies and convergence insufficiency. Other notable causes include orbital trauma, third nerve palsy, myasthenia gravis, myopic strabismus fixus, skew deviation, retinal misregistration (“dragged-fovea diplopia”) and strabismus occurring after other ophthalmic procedures.

This Preferred Practice Pattern (PPP) details evaluation and management of all these disorders, surgical considerations unique to adults with strabismus, and improvements in quality of life often experienced by those successfully treated. The PPP recommendations are based on Cochrane-identified reliable systematic reviews.

Rationale for treatment:

Treating adult strabismus can improve binocular function including stereoacuity and binocular fields and can reduce binocular inhibition, diplopia and confusion, associated compensatory head posture, and asthenopia. Successful treatment yields psychosocial benefits due to restoration of normal eye alignment and eye contact.

Care Process:

Pre-existing suppression increases risk for the development of fixation switch diplopia, which can occur when the previously nondominant eye becomes the dominant eye as a result of monovision or optical changes associated with cataract surgery. Fixation switch diplopia may also occur if vision loss from diseases such as macular degeneration or diabetic retinopathy leaves the previously nondominant eye with better acuity.

The risk of new-onset diplopia after strabismus surgery in adults undergoing treatment for unresolved childhood strabismus without previous diplopia is under 1%, and the risk of serious sight-threatening complications is exceedingly rare. Marked improvement in health-related quality of life after successful strabismus surgery is reported in both diplopic and nondiplopic patients, including improvements in general function, reading, self-perception and social interactions.

OBJECTIVES OF PREFERRED PRACTICE PATTERN® GUIDELINES

As a service to its members and the public, the American Academy of Ophthalmology has developed a series of Preferred Practice Pattern® guidelines that **identify characteristics and components of quality eye care**. Appendix 1 describes the core criteria of quality eye care.

The Preferred Practice Pattern® guidelines are based on the best available scientific data as interpreted by panels of knowledgeable health professionals. In some instances, such as when results of carefully conducted clinical trials are available, the data are particularly persuasive and provide clear guidance. In other instances, the panels have to rely on their collective judgment and evaluation of available evidence.

These documents provide guidance for the pattern of practice, not for the care of a particular individual. While they should generally meet the needs of most patients, they cannot possibly best meet the needs of all patients. Adherence to these PPPs will not ensure a successful outcome in every situation. These practice patterns should not be deemed inclusive of all proper methods of care or exclusive of other methods of care reasonably directed at obtaining the best results. It may be necessary to approach different patients' needs in different ways. The physician must make the ultimate judgment about the propriety of the care of a particular patient in light of all of the circumstances presented by that patient. The American Academy of Ophthalmology is available to assist members in resolving ethical dilemmas that arise in the course of ophthalmic practice.

Preferred Practice Pattern® guidelines are not medical standards to be adhered to in all individual situations. The Academy specifically disclaims any and all liability for injury or other damages of any kind, from negligence or otherwise, for any and all claims that may arise out of the use of any recommendations or other information contained herein.

References to certain drugs, instruments, and other products are made for illustrative purposes only and are not intended to constitute an endorsement of such. Such material may include information on applications that are not considered community standard, that reflect indications not included in approved U.S. Food and Drug Administration (FDA) labeling, or that are approved for use only in restricted research settings. The FDA has stated that it is the responsibility of the physician to determine the FDA status of each drug or device he or she wishes to use, and to use them with appropriate patient consent in compliance with applicable law.

Innovation in medicine is essential to ensure the future health of the American public, and the Academy encourages the development of new diagnostic and therapeutic methods that will improve eye care. It is essential to recognize that true medical excellence is achieved only when the patients' needs are the foremost consideration.

All Preferred Practice Pattern® guidelines are reviewed by their parent panel annually or earlier if developments warrant and updated accordingly. To ensure that all PPPs are current, each is valid for 5 years from the "approved by" date unless superseded by a revision. Preferred Practice Pattern guidelines are funded by the Academy without commercial support. Authors and reviewers of PPPs are volunteers and do not receive any financial compensation for their contributions to the documents. The PPPs are externally reviewed by experts and stakeholders, including consumer representatives, before publication. The PPPs are developed in compliance with the Council of Medical Specialty Societies' Code for Interactions with Companies. The Academy has Relationship with Industry Procedures (available at www.ao.org/about-preferred-practice-patterns) to comply with the Code.

Appendix 2 contains the International Statistical Classification of Diseases and Related Health Problems (ICD) codes for the disease entities that this PPP covers. The intended users of the Esotropia and Exotropia PPP are ophthalmologists.

METHODS AND KEY TO RATINGS

Preferred Practice Pattern® guidelines should be clinically relevant and specific enough to provide useful information to practitioners. Where evidence exists to support a recommendation for care, the recommendation should be given an explicit rating that shows the strength of evidence. To accomplish these aims, methods from the Scottish Intercollegiate Guideline Network¹ (SIGN) and the Grading of Recommendations Assessment, Development and Evaluation² (GRADE) group are used. GRADE is a systematic approach to grading the strength of the total body of evidence that is available to support recommendations on a specific clinical management issue. Organizations that have adopted GRADE include SIGN, the World Health Organization, the Agency for Healthcare Research and Policy, and the American College of Physicians.³

- ◆ All studies used to form a recommendation for care are graded for strength of evidence individually, and that grade is listed with the study citation.
- ◆ To rate individual studies, a scale based on SIGN¹ is used. The definitions and levels of evidence to rate individual studies are as follows:

I++	High-quality meta-analyses, systematic reviews of randomized controlled trials (RCTs), or RCTs with a very low risk of bias
I+	Well-conducted meta-analyses, systematic reviews of RCTs, or RCTs with a low risk of bias
I-	Meta-analyses, systematic reviews of RCTs, or RCTs with a high risk of bias
II++	High-quality systematic reviews of case-control or cohort studies High-quality case-control or cohort studies with a very low risk of confounding or bias and a high probability that the relationship is causal
II+	Well-conducted case-control or cohort studies with a low risk of confounding or bias and a moderate probability that the relationship is causal
II-	Case-control or cohort studies with a high risk of confounding or bias and a significant risk that the relationship is not causal
III	Nonanalytic studies (e.g., case reports, case series)

- ◆ Recommendations for care are formed based on the body of the evidence. The body of evidence quality ratings are defined by GRADE² as follows:

Good quality	Further research is very unlikely to change our confidence in the estimate of effect
Moderate quality	Further research is likely to have an important impact on our confidence in the estimate of effect and may change the estimate
Insufficient quality	Further research is very likely to have an important impact on our confidence in the estimate of effect and is likely to change the estimate Any estimate of effect is very uncertain

- ◆ Key recommendations for care are defined by GRADE² as follows:

Strong recommendation	Used when the desirable effects of an intervention clearly outweigh the undesirable effects or clearly do not
Discretionary recommendation	Used when the trade-offs are less certain—either because of low-quality evidence or because evidence suggests that desirable and undesirable effects are closely balanced

- ◆ The Highlighted Findings and Recommendations for Care section lists points determined by the PPP Panel to be of particular importance to vision and quality of life outcomes.
- ◆ All recommendations for care in this PPP were rated using the system described above. Ratings are embedded throughout the PPP main text in italics.
- ◆ Literature searches to update the PPP were undertaken in March 2016, February 2017, and June 2019 in the PubMed and Cochrane databases. Complete details of the literature searches are available in Appendix 3.

HIGHLIGHTED FINDINGS & RECOMMENDATIONS FOR CARE

Strabismus in adults has profound negative effects on quality of life and many aspects of day-to-day function. Strabismus surgery very often improves quality of life and function, and there are instruments to assess these aspects of evaluation and treatment. Patients with diplopia tend to have greatest improvements in functional domains, and nondiplopic patients tend to have greatest improvements in psychosocial domains.

Recessions of the restricted muscles are the mainstay of surgical correction in thyroid eye disease. Resection is generally avoided in restrictive disease out of concern for further reducing ductions and operating on a rectus muscle that would best be spared to provide ciliary artery supply to the anterior segment. However, it can be a useful adjunct in select cases, particularly when extremely large recessions have not fully corrected the alignment.

Screening for a history of childhood amblyopia or strabismus, checking spectacles for prism, and performing a cycloplegic refraction and cover testing are recommended for all patients undergoing refractive or cataract surgery, especially for those patients for whom monovision is planned. Patients with a history of childhood strabismus and suppression are particularly at risk for developing fixation switch diplopia. This form of diplopia results when the previously nondominant eye becomes the dominant eye as a result of intended or unintended monovision by refractive manipulation or cataract surgery. A trial of monovision with contact lenses is prudent prior to corneal or lenticular refractive surgery to determine whether surgically induced monovision will result in new-onset diplopia. The development of asymmetric vision loss from other common diseases such as macular degeneration, myopia with axial elongation in the previously dominant eye, or diabetic retinopathy when the nondominant eye is left with better acuity may also result in fixation switch diplopia.

SECTION I. ADULT STRABISMUS OVERVIEW

INTRODUCTION

DISEASE DEFINITION

Strabismus is misalignment of the eyes and may be congenital or acquired. Although more typically associated with the pediatric population, strabismus is quite common among adults, with an estimated incidence of 4% in this population.⁴⁻⁶ The causes of strabismus in the adult population are numerous, in part because the challenges to ocular alignment common in the pediatric population persist, and because new disorders destabilizing alignment occur secondary to aging, vision loss, myopia, endocrine and neurologic disorders, and iatrogenic and non-iatrogenic trauma to the globe or orbit. Notable causes of strabismus in the adult population include:

- Recurrent or unresolved childhood strabismus
- Sensory strabismus
- Convergence insufficiency
- Divergence insufficiency
- Sagging eye syndrome
- Strabismus associated with high axial myopia
- Strabismus fixus
- Graves' disease
- Orbital trauma
- Strabismus associated with other ophthalmic surgery
- Fourth nerve palsy
- Skew deviation
- Sixth nerve palsy
- Third nerve palsy
- Myasthenia gravis
- Fixation switch diplopia
- Retinal Misregistration or Binocular Retinal Diplopia

Accordingly, accurate diagnosis of the etiology of strabismus in the adult population requires the expertise to recognize associated signs and symptoms and familiarity with studies that may confirm the diagnosis. In addition, the goal(s) of treatment may impact the plan for surgical or nonsurgical intervention. Adult patients often have unique concerns associated with functional vision as well as psychosocial concerns that affect quality of life. In the past, most emphasis was on improving motor alignment, but it is now understood that the goals of treatment should be much broader and include sensory recovery when possible as well as gains in psychosocial and functional domains of vision-related quality of life.

Success rates depend on the subpopulation studied and the goals of surgery, but overall they are approximately 80% after one procedure^{5,7,8} and may exceed 95% if a second procedure is performed on eyes failing the first intervention.⁴ Intractable postoperative diplopia in primary gaze for adult patients without diplopia prior to intervention occurs in 1% or fewer cases.^{4,7,9,10} Satisfactory resolution of diplopia in primary position for those who present for treatment of diplopia is possible more than 95% of the time, although diplopia in eccentric gaze may persist.⁵

PATIENT POPULATION

The patient population is adults with strabismus.

CLINICAL OBJECTIVES

- Perform a clinical examination and ancillary testing as indicated to diagnose the cause of strabismus
- Counsel the patient on the diagnosis and treatment options
- Consult other medical providers if the diagnosis indicates the need for multidisciplinary management
- Establish priorities in the goal-directed management of strabismus (improved eye contact and appearance of alignment (reconstructive), enhancing binocular potential, or reduction or resolution of diplopia and/or compensatory head posture^{11,12})
- Inform the patient's primary care and other health care providers of the diagnosis and treatment plan

BACKGROUND

PREVALENCE

Individual practice estimates vary based on setting and provider. Intelligent Research in Sight (IRIS) registry data document a prevalence of 2.7% in ophthalmology practices.^{4-6,13}

RATIONALE FOR TREATMENT

In general, the goal of adult strabismus surgery is to optimize the functional visual status of patients while also addressing psychosocial concerns. The potential benefits of strabismus surgery in adults include:

- Improvement in binocularity (ranging from simultaneous perception to stereopsis)^{1,4,7,14-17}
- Improvement in diplopia or compensatory head position^{4,5,7}
- Normalization of binocular visual field¹⁸
- Improvement in binocular summation or resolution of binocular inhibition¹⁹
- Reduction of asthenopia
- Psychosocial benefits related to the restoration, rehabilitation, and improvement in an abnormal facial appearance secondary to ocular misalignment^{4,6,7,20-26}

The overall rate of success for achieving satisfactory ocular alignment cannot easily be summarized because of the vast heterogeneity within this group and the lack of consensus on what constitutes “success.” However, analysis of several studies comprising multiple strabismus subtypes suggests that the overall success rate approaches 80%,^{4,7,27} with resolution of diplopia in a similar proportion.^{4,7,27} Functional improvement in binocularity can also be achieved in many patients. Although the highest level of binocularity (high-grade stereopsis) requires good vision in each eye, orthotropia and baseline binocular potential, lower levels of binocularity (such as simultaneous perception or peripheral fusion) can be achieved in patients with poorer vision or longstanding strabismus. Additionally, patients with poor vision in one eye or even infantile-onset strabismus can achieve improvement in binocular summation after surgery.¹⁹ Successful strabismus surgery may also increase the binocular visual field in patients with esotropia.¹⁸

For individual patients, a realistic functional goal for surgical success is dependent on their strabismus subtype as well as the duration of strabismus. For example, in patients with strabismus acquired during adulthood, the functional goal of surgery is likely to be resolution of or improvement in diplopia or compensatory head position and high-grade stereopsis. However, in adults with a longstanding history of infantile-onset strabismus, achieving bifoveal fixation is not a realistic goal, and functional goals would therefore include normalization of visual fields, improvement in binocular summation, or improvement of diplopia or compensatory head position, if present. It is important to measure and document diplopia in addition to ocular alignment,²⁸ and there are now methods to quantify diplopia. The field of binocular single vision can be plotted on a Goldmann perimeter,²⁹ a cervical range-of-motion device can be used to record diplopia in specific positions of gaze,^{30,31} or the Diplopia Questionnaire can be used to assess the frequency of diplopia in specific positions of gaze.³²

Aside from the functional goals of surgery described above, psychosocial concerns are also important. Patients with strabismus endure both psychosocial and economic hardships, such as difficulty obtaining employment,³³ receiving promotions,³⁴ and overcoming negative social bias.²⁵ Assessment of psychosocial aspects of the impact of strabismus is best achieved using patient-reported outcomes measures (PROMs). These PROMs are typically questionnaires completed by the patient and then evaluated and scored. The Adult Strabismus-20³⁵ questionnaire was developed using a rigorous method of conducting individual patient interviews to identify concerns and to generate potential questions. A master questionnaire was then refined by eliminating questions that were not broadly applicable, that had marked ceiling or floor effects, or that were limited by socioeconomic status or location.³⁵ Subsequent studies revealed that the questions should be further subdivided into two psychosocial domains (self-perception and interactions) and two function domains (reading function and general function).³⁶

Using PROM questionnaires, several studies have reported marked improvement in health-related quality of life after strabismus surgery in both diplopic and nondiplopic patients.^{22,37-39} In some patients, this improvement has

been found to correlate with improvements in binocular function.⁴⁰ In general, patients with diplopia tend to have greatest improvements in function domains, and nondiplopic patients tend to have greatest improvements in psychosocial domains.³⁸ Nevertheless, even adults with limited binocular potential have been found to have function-related benefits from strabismus surgery.⁴¹ The use of PROM questionnaires adds to previous methods of assessing residual motor angle of deviation and the presence or absence of diplopia.^{28,39} Additionally, even some patients who might have been classified as surgical failures, based on residual angle and diplopia, report dramatic improvements in health-related quality of life, often attributable to improvements in psychosocial issues.⁴² In addition to improvements in health-related quality of life, other facets of mental health such as mood, depression, anxiety, social avoidance, and self-esteem have been found to improve after strabismus surgery in adults.^{22,43-45} Strabismus surgery may also have a positive impact of other aspects of overall health, such as reducing falls in the elderly.⁴⁶

Nevertheless, despite improvements in binocular function and psychosocial issues for most adults undergoing strabismus surgery, there are some patients who do not perceive an improvement in quality of life. Such lack of improvement is likely multifactorial, but it may be due to depressive symptoms that are not at the level of clinical depression,⁴⁷ other mental illnesses,⁴⁸ or unrealistic expectations.⁴⁹ Therefore, physicians must counsel patients preoperatively to ensure that there is mutual understanding about realistic goals of surgery and—if there are mental health issues—that these are identified and appropriate referrals made.

Although the primary goal of strabismus surgery is typically ocular realignment,²⁷ patient-specific surgical success metrics should be based on achieving a goal mutually set by the physician and the patient. This goal should incorporate the patient's primary concerns as well as the physician's determination of which goals are achievable considering the underlying etiology, previous treatment history, and disease duration. Specific, goal-determined metrics for surgical success have been suggested for patients with esotropia and exotropia.^{11,12}

These suggested metrics^{11,12} combine ratings of the following four goals:

- Binocular potential
- Reconstruction of ocular alignment
- Resolution or reduction of diplopia
- Improvement of compensatory head position, or ocular torticollis

In summary, strabismus in adults has profound negative effects on quality of life and many aspects of day-to-day function. There is excellent evidence that strabismus surgery very often improves quality of life and function, and there are now questionnaires to assess these aspects of evaluation and treatment.

SECTION II. COMMON AND CLINICALLY IMPORTANT MANIFESTATIONS OF ADULT STRABISMUS

IIa. PERSISTENT OR RECURRENT CHILDHOOD STRABISMUS

INTRODUCTION

DISEASE DEFINITION

Persistent or recurrent childhood strabismus in adults is strabismus that originated in early childhood before visual maturity (most often defined as before 9 years of age).^{5,7,8} This type of adult strabismus arises in several different ways:

- Childhood strabismus that was untreated
- Decompensation of previously asymptomatic strabismus
- Recurrence of a previously treated strabismus
- Evolution of consecutive strabismus after childhood treatment

PATIENT POPULATION

The patient population is adults who had onset of strabismus in early childhood.

CLINICAL OBJECTIVES

- Counsel the patient on the diagnosis and treatment options
- Provide goal-directed management of strabismus (to restore eye alignment for improved self-image, restore binocular vision, if possible, and reduce diplopia or compensatory head posture, if present)
- Inform the patient's other health care providers about the diagnosis and treatment plan

BACKGROUND

PREVALENCE

Prevalence varies according to setting. The authors of one report found that 60% of cases in their adult strabismus clinic had recurrent or previously untreated childhood strabismus.^{5,7}

NATURAL HISTORY

The ocular misalignment in adults with persistent or recurrent childhood strabismus will not resolve spontaneously. However, signs and symptoms may range in severity from mild (that is psychosocially acceptable) to large-angle misalignment of the eyes, with or without diplopia.

RATIONALE FOR TREATMENT

Psychosocial concerns are among the many reasons for considering surgical intervention in cases of childhood strabismus presenting or re-presenting in the adult years.^{4,5,7,11,12,16-19} These include poor self-perception, impaired social interactions, and poor eye contact. The psychosocial benefits of such intervention have been extensively reviewed.^{6,8,20-22,24-26,50} In addition, increased difficulty in maintaining binocular fusion or the development of increasing compensatory head positioning to maintain binocular fusion, and episodic diplopia are reasons to consider intervention as well.

Although there is a vast range of presenting patterns, consecutive exotropia after prior surgery for esotropia is a particularly common form of this type of strabismus. Whereas anisometropia, amblyopia, hypermetropia, and dissociated vertical deviation (DVD) are risk factors for consecutive exotropia in childhood,^{51,52} adduction deficits are more typically associated with consecutive exotropia in the adult population and require a specific surgical approach.^{53,54}

Adults with a history of childhood strabismus often have a successful outcome from surgery later in life. Over 90% of adults treated with strabismus surgery demonstrate improvement in alignment or in binocular function, and as many as 25% achieve both after surgery in their adult years.⁵ In a study of 359 adults with longstanding strabismus, an absence of diplopia prior to strabismus surgery, and attainment of postoperative motor alignment within 8 prism diopters of orthophoria, 86% demonstrated postoperative binocularity based on testing with Bagolini lenses (striated lenses used to test for suppression and for normal or abnormal retinal correspondence).^{16,55} In another study of adults with a history of infantile esotropia and failure to obtain motor alignment by 2 years of age but who achieved motor alignment within 8 prism diopters of orthophoria as adults, all achieved peripheral fusion (Worth 4-Dot at near) and nearly half achieved 200 or more arc seconds of stereopsis.¹⁷ It is not always possible to predict which patients will acquire sensory fusion. However, patients with a history of congenital esotropia and a positive response to prism adaptation often demonstrate postoperative fusion along with good motor alignment.⁵⁶ In a review of outcomes of strabismus surgery,

postoperative diplopia is a concern but, although transient diplopia after surgery is common,⁹ patients can be reassured that persistent diplopia after successful surgery occurs in 1% or fewer patients,^{4,7,10} even in those whose preoperative prism testing suggests that it may occur.

CARE PROCESS

PATIENT OUTCOME CRITERIA

Treatment in adult strabismus is goal directed, and targeted outcomes may include:

- Restoration of normal ocular alignment and appearance, and improved self-image
- Restoration of binocular function
- Reduction of diplopia (if present)
- Reduction of compensatory head position (if present)

DIAGNOSIS

History

- Ocular misalignment in an adult with a history of persistent or recurrent childhood strabismus.
- Strabismus angle and direction may be the same as original presentation in childhood or different as a result of aging of the extraocular muscles or the impact of prior strabismus surgery
- History of chronicity is important. An acute change or newly symptomatic diplopia may warrant evaluation for other causes such as cranial nerve palsy, thyroid eye disease (TED), or fixation switch diplopia. (See appropriate subsections of this PPP.) Formal neuro-ophthalmic evaluation may be indicated in some cases where presentation suggests other neurologic or systemic disease. An attempt should be made to acquire and review past clinical and surgical records as well as any prior imaging studies.

Examination

The examination should include the following elements:

- A careful review of the current optical correction (glasses) and the presence of any ground-in or overlay prism, and the impact that the current correction might have on alignment
- Manifest refraction to identify refractive barriers to binocular alignment or fusion
- Assessment of alignment by light reflex testing (e.g., Krimsky) to compare with cover test measurements and identification of abnormal angle kappa

- Dry manifest and cycloplegic refraction, which may reveal anisometropia or high hyperopia, providing clues to original ocular motor disturbance. Consideration should be given to changing the current correction, which might resolve strabismus
- Complete motility examination, including cover-uncover and alternate-cover testing as well as testing for binocular fusion and stereopsis.⁵⁷ Strabismus patterns suggestive of cranial nerve palsy, skew deviation, or the presence of new-onset nystagmus, proptosis or inflammatory changes may indicate central nervous system or endocrine pathology (see sections on cranial nerve palsies, skew deviation and thyroid eye disease). These disorders can, of course, impact the population of patients with unrelated childhood strabismus and warrant further evaluation and potentially different treatment.
- Inspection of the ocular surface for conjunctival scars (prior incision sites) and exposure of the thinned sclera behind anatomical insertions (evidence of likely muscle recession), because inspection can provide clues indicating details of prior extraocular muscle surgery
- Inspection of the interpalpebral fissures for evidence of possible prior vertical or horizontal rectus muscle resection (smaller interpalpebral fissure) or recession (larger interpalpebral fissure)
- Prism testing to simulate the desired postsurgical alignment and the range of overcorrection and undercorrection comfortably tolerated and unlikely to result in diplopia. With adult strabismus originating in early childhood, however, the response to prism can be misleading owing to frequent coexistent anomalous retinal correspondence, which often changes postoperatively. Often a patient will have diplopia when the misalignment is corrected with prism but will rapidly readapt to the same correction when induced by surgery, resulting in a very low incidence of new longstanding postoperative diplopia.¹⁰
- Assessment for ocular torsion by sensory testing or by anatomic evidence of torsion noted during indirect ophthalmoscopy, particularly in patients with vertical strabismus. Fortunately, it is very rare for torsional diplopia to be problematic in adult patients with early childhood onset strabismus due to either suppression or torsional anomalous retinal correspondence, which nearly always readapts postoperatively.
- Imaging, such as computed tomography (CT), magnetic resonance imaging (MRI), or orbital ultrasound may aid in localization of previously operated extraocular muscles, although nearly all these cases can be managed without imaging using careful preoperative and intraoperative assessment.

MANAGEMENT

Monitor/Observe

The patient should be monitored/observed if symptoms are mild, occasional, and well tolerated or if the patient is opposed to treatment.

Nonsurgical

For refractive error, consider whether alignment might be improved using all the information gained from dry and cycloplegic refraction, for example, by correction of hyperopia and appropriate bifocal or progressive lenses for adults approaching presbyopia. Reversal of monovision may be necessary and may resolve symptoms for some patients (see Section II.m. Fixation Switch Diplopia). The impact of this intervention can often be appraised in-office.⁴ Prisms to address some forms of diplopia and orthoptic exercises to address some forms of diplopia and asthenopia can also be considered in some cases.

Surgical

Correction of childhood strabismus in adults is generally surgical but, because a broad range of conditions may be responsible, the specifics of the surgical treatment will vary. However, there are often sequelae of previous surgery (such as underaction of a recessed muscle, restriction of a scarred muscle, or unsightly conjunctival scarring) that should be addressed to optimize the postoperative alignment. Many patients, particularly those with a history of infantile esotropia, have poor fusion along with accompanying sensory adaptations such as suppression and anomalous retinal correspondence. As adults, the majority readily adapt to the new ocular alignment resulting from strabismus surgery, although some may require more time to adapt to this change.

PROVIDER AND SETTING

Diagnosis and management of persistent or recurrent childhood strabismus require the training and clinical judgment of an experienced ophthalmologist. Working under the supervision of an ophthalmologist, orthoptists can be an asset in the examination, diagnosis, and nonsurgical management of adult strabismus. Surgical treatment of childhood-onset strabismus in adults is often challenging because of pre-existing surgical scarring, uncertainty about extraocular muscle attributes and location, possible limited fusional skills, and (in rare cases) impaired ability to adapt to new alignment.

COUNSELING AND REFERRAL

The ophthalmologist should discuss the findings, explain the disorder, provide a diagnosis, and discuss management options with the patient and any caregivers.

SECTION IIb. SENSORY STRABISMUS

INTRODUCTION

DISEASE DEFINITION

Sensory strabismus denotes an ocular misalignment in the setting of vision loss in one or both eyes. There are myriad causes of sensory strabismus, which include the following:

- Congenital structural ocular defects (i.e., optic nerve hypoplasia)
- Amblyopia from anisometropia or deprivation (i.e., pediatric cataract)
- Acquired vision loss from ophthalmic disease or trauma (e.g., glaucoma, retinal detachment, or optic atrophy)

PATIENT POPULATION

The patient population is adults with sensory strabismus.

CLINICAL OBJECTIVES

- Counsel the patient on the diagnosis and treatment options
- Provide goal-directed management of strabismus (reconstruction of ocular alignment and, in some cases, restoration of binocular function and reduction of diplopia)
- Inform the patient's other health care providers about the diagnosis and treatment plan

BACKGROUND

PREVALENCE

About 7% of adults over the age of 60 who have been treated with strabismus surgery have sensory strabismus.⁷

NATURAL HISTORY

Loss of visual acuity in one or both eyes and loss of binocular function often results in compromised alignment. Whereas esotropia is more common in early childhood, later onset vision loss is more typically associated with exotropia. Sixty-nine percent of this population present with exotropia versus 31% who present with esotropia.⁵⁸ Coexisting vertical misalignment is not uncommon.^{59,60}

RATIONALE FOR TREATMENT

Although improvements in binocular function are uncommon after the surgical treatment of sensory strabismus, there are significant benefits to patients following ocular realignment. In esotropic patients, ocular realignment can yield improvement in peripheral vision and visual field expansion.⁸ Also, enhanced emotional health, self-esteem, employment opportunities, and social interactions have been well documented after the correction of sensory strabismus.^{5,6,20-22,24-26} Long-lasting improvement in sensory strabismus is common despite the lack of binocular potential in most patients.²³

CARE PROCESS

PATIENT OUTCOME CRITERIA

- Restoration of normal ocular alignment and appearance, with improved self-image
- Potential for improvement in other psychosocial domains

DIAGNOSIS

History

A detailed medical and ocular history, including specific questions about patient symptoms and perception of ocular misalignment, may be helpful.

Examination

Complete sensorimotor examination should be performed, and misalignment should be measured by prism and alternate cover test, if possible. However, in the setting of significant vision loss, an estimation of binocular alignment is often best accomplished using the Krimsky, modified Krimsky, or Hirschberg tests at distance and near.⁵⁷ Misalignment is appraised when the better sighted eye is fixated on an accommodative target, because that is often the angle that warrants repair with surgical intervention. If there is eccentric fixation with the poorer seeing eye, the prism and alternate cover test may be misleading. A modified Krimsky or Hirschberg test, using a muscle light at 1/3 meter, may better guide surgical management.

The presence of treatable causes of vision loss should be determined prior to strabismus surgery and treated as possible or appropriate. Sometimes this will improve the ability to maintain normal alignment as may occur after cataract extraction in a patient with a history of prior excellent binocular fusion. At other times, treatment may only increase symptoms of diplopia and patients may defer or delay this intervention in order to minimize diplopia awareness.

MANAGEMENT

Monitor/Observe

The patient should be monitored/observed if symptoms are mild, occasional, and well tolerated or if the patient is opposed to treatment.

Nonsurgical

Chemodenervation (botulinum toxin) can yield long-term improvement in ocular alignment in some cases.⁶¹

Surgical

Surgical treatment for sensory strabismus includes the complete realm of current strabismus surgical techniques, with some surgeons favoring the use of adjustable sutures.⁷ Patients with sensory strabismus may also suffer from asymmetric eyelid or globe position (i.e., ptosis, proptosis, enophthalmos, or exophthalmos). In some cases, these eyelid abnormalities may be iatrogenic and associated with prior orbital or retinal surgery or trauma. In such cases, use of large extraocular muscle recessions can also improve concomitant ptosis or enophthalmos via its effect on globe position within the orbit. Similarly, large extraocular resections can reduce proptosis and exophthalmos by repositioning the globe within the orbit. Such dual benefits can be particularly important to patients who may not have the means to afford elective oculoplastic surgery.⁶²

PROVIDER AND SETTING

Diagnosis and management of sensory strabismus requires the training and clinical judgment of an experienced ophthalmologist. Working under the supervision of an ophthalmologist, orthoptists can be an asset with the examination and diagnosis of sensory adult strabismus.

COUNSELING AND REFERRAL

The ophthalmologist should discuss the findings, explain the disorder, provide diagnosis, and discuss management options with the patient and any caregivers. The risks of strabismus surgery in patients with sensory strabismus are like those of any patient undergoing strabismus surgery and include the remote risk of scleral perforation, new onset diplopia, and (in select cases) disruption of extraocular muscles or dislodging of orbital implants. (See Section IIg. Iatrogenic Strabismus.)

SECTION IIc. CONVERGENCE INSUFFICIENCY

INTRODUCTION

DISEASE DEFINITION

Convergence insufficiency is a binocular disorder associated with eyestrain, headaches, blurred vision, horizontal diplopia, or a need to close one eye to avoid diplopia while reading or engaged in near activities.⁵⁰ Difficulty concentrating, movement of print, and loss of comprehension after short periods of reading are described as well.⁵⁰ It is also associated with exophoria or exotropia at near.⁶³

PATIENT POPULATION

The patient population is adults with convergence insufficiency.

CLINICAL OBJECTIVES

- Counsel the patient on the diagnosis and treatment options
- Provide goal-directed management of symptoms (reduction of asthenopia, improved reading, binocular vision, and/or reduction of diplopia)
- Communicate with the patient's other health care providers on the diagnosis and treatment plan

BACKGROUND

INCIDENCE

Convergence insufficiency has an annual incidence of 8.4 per 100,000 people and represents 15.7% of new-onset adult strabismus cases. Though the median age of new-onset adult cases is 69 years old, some adults present after decompensation of convergence insufficiency that began earlier in life.^{64,63}

RISK FACTORS

A history of concussion,⁶⁵ recurrent sub-concussive events,⁶⁶ and certain central nervous system disorders such as Parkinson's disease⁶⁷ are associated with convergence insufficiency.

NATURAL HISTORY

In general, convergence insufficiency does not improve, but symptoms may vary as demands for near work change over time. Cases of convergence insufficiency secondary to concussion may improve over time.^{65,68}

RATIONALE FOR TREATMENT

Treatment for convergence insufficiency is offered to ameliorate asthenopia and intermittent diplopia at near and to enhance ability to perform activities requiring binocularity at near.

CARE PROCESS

PATIENT OUTCOME CRITERIA

Treatment of convergence insufficiency in adult strabismus is symptom directed, and targeted outcomes may include the following:

- Resolution of asthenopia or increasing comfort with reading and near work
- Control of diplopia at near
- Improvement in binocular function at near

DIAGNOSIS

The diagnosis of a patient with convergence insufficiency includes a comprehensive examination of adult strabismus patient and the following:

- Detailed sensorimotor evaluation
- Assessment of refractive status
- Dilated fundus exam

History

A detailed medical history should include information/medical records on prior ocular surgery and diseases or trauma to the central nervous system. Assessment and quantification of patient symptoms can be achieved using the Convergence Insufficiency Symptom Survey and/or the Diplopia Questionnaire.⁶⁹

Examination

A sensorimotor exam in the presence of convergence insufficiency demonstrates the following:^{64,70,71}

- Exophoria greater at near than distance
- Insufficient positive fusional vergence at near (<20 PD mean positive fusional vergence blur or failing Sheards' criterion; mean positive fusional vergence measured less than twice the near phoria magnitude)
- Distant near point convergence (> 6 cm)

It should always be verified that the optical correction is appropriate for near activities.

MANAGEMENT

Monitor/Observe

The patient should be monitored/observed if symptoms are mild, occasional, and not bothering the patient or if the patient is opposed to treatment.

Nonsurgical

Convergence orthoptic exercises are often helpful. Office-based training appears to be more effective than home-based exercises in children. However, in young adults (19–30 years old) office-based training was found to be more effective than home-based training at improving positive fusional vergence but not near point of convergence or patient symptoms.^{50,72} In general, results of convergence training are less consistent in the adult population than in children.⁷² Nonsurgical treatment can also include prism reading glasses.⁷³

Surgical

Strabismus surgery may be helpful in some cases, particularly when a manifest distance deviation is present, symptoms are consistent, and prism reading glasses are not satisfactory. Lateral rectus recession (based on distance deviation) and/or medial rectus resection (based on near deviation) have been reported to be successful for surgical management,^{74,75} although other options (including chemodenervation,⁷⁶ slanting insertions and augmentation of lateral rectus recessions) have been studied and have possible advantages in certain populations.⁷⁷

PROVIDER AND SETTING

Diagnosis and management of convergence insufficiency requires the training, clinical judgment, and experience of an ophthalmologist familiar with this diagnosis, and treatment may benefit from the assistance of an orthoptist or an optometrist.

COUNSELING AND REFERRAL

The ophthalmologist should discuss the findings, explain the disorder, provide a diagnosis, and discuss management options with the patient and any caregivers.

SECTION II.d. ACQUIRED STRABISMUS RELATED TO AGING AND MYOPIA

INTRODUCTION

DISEASE DEFINITION

Acquired strabismus related to aging and myopia focuses on forms of strabismus typically associated with aging of the extraocular muscle and pulley complex and with exacerbation of this in the myopic eye—divergence insufficiency, sagging eye syndrome, and strabismus fixus (“heavy eye”).

Divergence Insufficiency

Divergence insufficiency is characterized by an esotropia that increases with distance fixation and may also be known as age-related distance esotropia. Patients present with an acquired comitant esotropia that is at least 10 prism diopters larger at distance than at near⁷⁸ and complain about progressive or subacute-onset double vision at distance (e.g., while driving or watching television). They rarely have diplopia at near. Primary divergence insufficiency may be associated with decompensation of a long-standing esodeviation, loss of fusion, or mechanical changes to the extraocular muscles.⁷⁸ Secondary divergence insufficiency is associated with neurological disease and typically caused by a lesion to a supranuclear divergence center, subtle sixth nerve palsy, neurologic abnormality associated with pontine tumors, or head trauma.^{79,80} (See Section IIi. Abducens Palsy.)

Sagging Eye Syndrome

Some cases of divergence insufficiency may be seen in association with an age-related degeneration of the lateral rectus-superior rectus (SR-LR) connective tissue band known as sagging eye syndrome.⁸¹ This band typically maintains a fixed distance between the lateral rectus and the superior rectus as they course posteriorly, but age or other degeneration can result in a medial shift of the superior rectus and an inferior shift of the lateral rectus due to failure of this connective tissue band. As the lateral rectus sags downward, abduction becomes impaired and esotropia results. The esotropia is often greater at distance than at near. This downward shift of the lateral rectus muscle may be responsible for an often-associated small-angle hypotropia, although other extraocular muscle and pulley abnormalities have been reported in addition to the inferior sagging of the lateral rectus and the disruption of the SR-LR band.^{81,82}

Sagging eye syndrome also shares some imaging characteristics with myopic strabismus fixus; however, myopic strabismus fixus results in more extreme displacement of the lateral rectus, nasal displacement of the superior rectus muscle, and superotemporal prolapse of the globe.

Strabismus Fixus (“Heavy Eye Syndrome”)

Strabismus fixus is progressive large-angle esotropia and hypotropia with a limitation in ocular rotation in patients with longstanding pathological high myopia. As a result of the increased axial length, there is development of a staphyloma or a staphylomatous-like change in globe dimensions that results in rupture of the SR-LR band. An inferior shift of the lateral rectus muscle⁸³ and a nasal shift of the superior rectus muscles ensue.^{84,85 86,87} Globe dislocation (prolapse) into the superotemporal orbit and outside the confines defined by the lateral rectus and superior rectus occurs. Ocular rotations in myopic strabismus fixus are much more severely altered than in sagging eye syndrome; there is a component of mechanical restriction not seen in sagging eye syndrome, likely secondary to secondary medial rectus contracture as well as globe prolapse into the superotemporal orbit. Not at all cases of axial high axial myopic result in strabismus fixus. In some cases the globe elongation is axial only, superotemporal globe dislocation does not occur, and the patient may be treated as if he or she has classic divergence insufficiency.⁸⁶

PATIENT POPULATION

The patient population is adults with divergence insufficiency, sagging eye syndrome, or strabismus fixus.

CLINICAL OBJECTIVES

- Counsel the patient on the diagnosis and treatment options
- Provide goal-directed management of strabismus (restoration of binocularity and control of diplopia and, when severe, reconstruction of normal appearing alignment, improved eye contact, and self-image)
- Communicate with the patient’s other health care providers about the diagnosis and treatment plan

BACKGROUND

PREVALENCE AND RISK FACTORS

Divergence Insufficiency

The annual incidence of 6.0 per 100,000 people represents 10.6% of new-onset adult strabismus cases.⁶³ The median age of presentation is 74 years.⁶³ Divergence insufficiency typically presents after 50 years of age, and its frequency increases with age.⁶³

Sagging Eye

The prevalence of sagging eye syndrome as a distinct variant of divergence insufficiency is unknown because the clinical description is relatively new, and not all practitioners distinguish this entity from the

more general descriptor, divergence insufficiency. Sagging eye occurs more frequently in myopic patients, and the most common age of participants in research studies is 66 to 69.^{81,88,89}

Strabismus Fixus or “Heavy Eye”

The prevalence globally is unknown but has been estimated to be 2.65% among high myopes in Japan.⁹⁰ Progressive strabismus fixus is most often associated with middle or older age, with less severe divergence insufficiency predating this progression.^{91,92} Severe myopia with an axial length of more than 27mm is characteristic.^{83,84,87}

NATURAL HISTORY

The strabismus and diplopia caused by divergence insufficiency, sagging eye syndrome, and strabismus fixus will not resolve spontaneously. Strabismus fixus is often the most progressive in severity.^{86,92}

RATIONALE FOR TREATMENT

Diplopia, the inability to make eye contact, and severe ocular misalignment preventing proper eye examinations or other needed ophthalmic surgery (in the case of strabismus fixus) warrant treatment.

CARE PROCESS

PATIENT OUTCOME CRITERIA

Treatment of adult strabismus is symptom directed, and targeted outcomes may include:

- Reduction of diplopia
- Improving/returning binocular vision
- Reconstruction of ocular alignment
- Reduction of compensatory head position (if present)

DIAGNOSIS

History

Patients present with a history of subacute onset of binocular diplopia from esotropia, worse at distance, and sometimes associated with modest vertical misalignment. This group of disorders is progressive, and may begin to impact alignment at near. Detailed medical history should include the use of prism correction in glasses.⁹³ Symptoms first become apparent with distant fixation (e.g., while driving) and most commonly after age 50 years for classic divergence insufficiency⁶³. Symptoms are similar for sagging eye syndrome, with associated small-angle vertical and torsional diplopia at times; presentation with sagging eye syndrome is more common in the seventh decade of life or older. Associated changes of blepharoptosis

(29%), deep superior lid sulcus defect (64%) and a history of blepharoplasty, brow lift, or facelift surgery has been noted in some cases.⁸¹ Heavy eye or myopic strabismus fixus is associated with very high axial myopia of more than 27mm. Onset may begin in the earlier decades of adult life with chronic progression of a more extreme esotropia and possible hypotropia often associated with mechanical restriction.^{83,84,87}

Examination

Divergence Insufficiency

- More esotropia at distance than at near (usually 10 prism diopters or more)
- Similar esotropia in right and left gaze in the absence of pontine or other neurological pathology or significant abduction nystagmus
- No limitation on forced duction under anesthesia

Sagging Eye Syndrome

- Esotropia, often greater at distance, and sometimes accompanied by a small vertical deviation and cyclotropia^{81,82}
- Deviations are nearly comitant, except for possible distance-near disparity
- Mild to no limitation of ocular rotation
- Associated changes of blepharoptosis (29%), deep superior lid sulcus defect (64%) with a previous history of blepharoplasty, brow lift, or facelift surgery in some cases⁸¹

Strabismus Fixus

- Severe myopia, typically -8.00 diopters or more but often much greater
- Axial length of more than 27 mm
- Large-angle ocular deviation of esotropia with or without hypotropia
- Limitation of ocular rotations such as abduction or elevation
- An SR-LR dislocation angle of $121^\circ \pm 7^\circ$ (measuring the angle between the centroids of the superior rectus muscle and lateral rectus muscle on quasicoronal imaging)⁸⁶

A complete ocular motility examination for these syndromes should include cover testing at near and distance in primary and secondary gaze positions and evaluation of torsion for patients with vertical misalignment. In patients with myopic strabismus fixus there may be limited rotations and measurements can be obtained only with the modified prisms light reflex (Krimsky) test.

High-resolution orbital imaging is useful for evaluation of patients with likely sagging eye or myopic strabismus fixus to look for evidence of disruption of the LR-SR band. This characteristic is best seen on coronal T1-weighted images obtained without fat suppression. The lateral rectus sags downward,

creating a large angle between the lateral rectus and superior rectus (typically $104^\circ \pm 11$) for patients with sagging eye syndrome. ⁸⁶There is fat prolapse within this potential space.

In contrast, for patients with myopic strabismus fixus (“heavy eye syndrome”) the angle between the lateral rectus and the superior rectus is much larger (described as $121^\circ \pm 7^\circ$) and there is frank prolapse of the globe within this space. The globe itself demonstrates axial elongation and often posterior enlargement. ^{81-84, 86}

Brain imaging and further neurologic workup is indicated if the patient presents with significant abduction nystagmus and lateral incomitance suggesting the alternative diagnosis of sixth nerve palsy, or with signs or symptoms of elevated intracranial pressure such as headache and papilledema or other neurologic decline which may result in 6th nerve palsy. (See Chapter IIj)

Conditions resembling myopic strabismus fixus and presenting with restrictive esotropia with or without hypotropia include orbital trauma, chronic complete 6th nerve palsy, thyroid eye disease and acquired fibrosis of the extraocular muscles but are readily distinguished based on history and characteristic orbital imaging.

MANAGEMENT

Divergence Insufficiency

Monitor/Observe

The patient should be monitored/observed if symptoms are mild and occasional or if the patient is opposed to treatment.

Nonsurgical

Fresnel or ground-in prisms can be temporary (prior to surgical correction) or long-term treatment options.⁹³ Patients should be counseled that the magnitude of prism correction needed to control diplopia may increase over time and that the ability to control the diplopia when glasses are not used will likely decline. There is little evidence to support the use of fusional exercise for the treatment of divergence insufficiency. In fact, previous studies have reported no benefit.⁹⁴

Surgical

Lateral rectus resection⁹⁵ as well as medial rectus recession^{95,96} have proven successful at resolving divergence insufficiency esotropia. Surgery can be performed bilaterally or unilaterally.^{78,97}

Typically, a greater surgical dose (than indicated in the standard tables) is needed for this type of esotropia. Therefore, some surgeons find adjustable sutures very useful with a target angle of a 2 to 4 prism diopters of exophoria in the distance.

It is useful to check convergence amplitudes at near prior to surgery. The presence of robust convergence amplitudes at near generally protects the patient from developing postoperative diplopia with convergence insufficiency at near.⁹⁶

Sagging Eye Syndrome

Monitor/Observe

The patient should be monitored/observed if symptoms are mild and occasional or if the patient is opposed to treatment.

Nonsurgical

Fresnel or ground-in prisms are helpful for patients with new-onset deviation, intermittent or constant and small in angle.

Surgical

Surgical prognosis for this group of patients is quite favorable and can be addressed using a variety of techniques, including marginal insertional tenotomies,⁸⁹ recessions, resections, and plications.⁹⁸

Surgical resolution or reduction of diplopia has been particularly beneficial for patients who don't otherwise need glasses for distance vision.⁸⁸ As described for patients with divergence insufficiency unrelated to sagging eye syndrome, more than typical recession of the medial rectus muscles is usually needed.⁹⁶

Strabismus Fixus

Monitor/Observe

The patient should be monitored/observed if he or she is opposed to treatment.

Nonsurgical

Prisms are not typically an option to correct the baseline strabismus but may be used postoperatively in patients with residual deviation

Surgical

In general, surgery is the only alternative to correct the large-angle esotropia and frequent hypotropia and to normalize ocular rotations. Referral to a retina specialist for preoperative evaluation should be considered to ensure that progressive myopic degeneration is not associated with active retinal

pathology requiring treatment prior to strabismus surgery. Measuring the angle between the SR muscle the LR muscle (dislocation angle) is helpful in determining the severity of the disease and for planning the surgery.⁸³⁻⁸⁵ A forced duction test to determine if limitation to ocular rotation is the result of a medial rectus muscle restriction or, more rarely, an orbital mechanical restriction resulting from the increased axial length and adjacency of the globe to the lateral orbital wall should be performed at the onset of surgery. If the forced duction test confirms restriction to abducting rotation, the medial rectus muscle should be recessed. However, some orbital mechanical restriction may be present even after medial rectus recession. In such cases, restriction to abduction may persist, limiting the outcome of the surgery.^{87,92,99,100} Medial rectus recession is typically accompanied by one of several muscle union procedures that join the superior rectus to the lateral rectus to reposition the muscle paths. The classical approach is the Yokoyama procedure, a vessel-sparing suture union of the superior rectus and lateral rectus 15 mm posterior to their insertions, typically accompanied by a medial rectus recession.⁸⁷ Many variants have been described, including union by a silicone sleeve¹⁰¹ and the use of a three-suture lateral rectus-superior rectus union to successfully reduce more extreme degrees of esotropia.¹⁰²

In some cases of very high axial myopia and esotropia, prolapse of the globe beyond the confines of the superior and lateral rectus may not be present. Such cases can be surgically managed like sagging syndrome or basic divergence insufficiency and do not typically require loop myopexy to resolve misalignment and diplopia.⁸⁶

PROVIDER AND SETTING

Diagnosis and management of divergence insufficiency and associated sagging eye syndrome and myopic strabismus fixus benefit from the training and clinical judgment of an experienced ophthalmologist. Working under the supervision of an ophthalmologist, orthoptists can be an asset in the examination, diagnosis, and nonsurgical management when appropriate.

COUNSELING AND REFERRAL

Divergence Insufficiency/Sagging Eye Syndrome

Magnetic resonance imaging and referral for central nervous system evaluation should be considered if other signs, such as abduction nystagmus, papilledema, or neurologic decline, are present.

Strabismus Fixus

Magnetic resonance imaging is often helpful in confirming the diagnosis of strabismus fixus. Referral to a retina specialist for preoperative evaluation should be considered to ensure that progressive myopic degeneration is not associated with active retinal pathology that, untreated, might increase risk of post-

operative retinal tear or detachment. Exposure keratopathy should be monitored and treated in cases of associated exophthalmos sometimes seen with high axial myopia or referred to an oculoplastic specialist for more definitive care. The ophthalmologist should discuss the findings, explain the disorder, provide a diagnosis, and discuss management options with the patient and any caregivers.

SECTION IIe. THYROID EYE DISEASE

INTRODUCTION

DISEASE DEFINITION

Thyroid eye disease is an autoimmune disorder characterized by congestion and inflammation of the orbit and surrounding tissues.¹⁰³ Typical ocular findings include soft tissue congestion with enlargement of the preseptal fat pads, eyelid retraction, exophthalmos, restrictive extraocular myopathy, and optic neuropathy.¹⁰⁴ Vision can be compromised from corneal exposure or optic neuropathy or as a result of development of diplopia secondary to congestive and restrictive extraocular muscle myopathy.

PATIENT POPULATION

The patient population is adults with strabismus and thyroid eye disease.

CLINICAL OBJECTIVES

- Counsel the patient on the diagnosis and treatment options
- Carefully monitor patients at risk for vision loss secondary to compressive optic neuropathy due to crowding at the orbital apex or severe exposure keratopathy from eyelid retraction with or without exophthalmos
- Manage binocular diplopia, compensatory head posture, and sometimes associated elevation in IOP
- Refer to an orbital specialist if the patient experiences vision-threatening disease, moderate-to-severe exophthalmos and/or significant orbital pain related to thyroid eye disease
- Inform the patient's other health care providers about the diagnosis and work collaboratively on the treatment plan

BACKGROUND

INCIDENCE

The incidence of TED in an adult Caucasian population is 16 per 100,000 per year in women and 2.9 per 100,000 per year in men.¹⁰⁵

RISK FACTORS

Thyroid eye disease can occur at any age, but onset is most often in the fourth to fifth decade of life.¹⁰⁶ There is a predilection for TED among women (8:1).¹⁰⁷ Risk of TED causing restrictive strabismus increases with

age.^{108,109} Smoking, diseases resulting in reduced oxygen saturation (such as emphysema), and exposure to ionizing radiation increase the risk for and severity of orbitopathy.^{110,111} A history of prior orbital decompression is associated with an increased risk of strabismus,¹¹² an association that worsens with age.¹⁰⁸ Radioactive iodine treatment, high anti-thyroid antibody titer and serum vitamin D deficiency are independent risk factors for developing TED.^{113,114}

NATURAL HISTORY

Between 30% and 50% of patients with TED develop restrictive myopathy. Ocular motility is restricted initially by inflammatory edema and later by fibrosis. The most frequently affected muscle in TED is the inferior rectus, followed by the medial rectus,¹¹⁵ although more global extraocular muscle involvement is common.

RATIONALE FOR TREATMENT

Motility impairment causing diplopia and compensatory head posture is a frequent manifestation of TED. This impacts visual function, affects quality of life, and can have profound socioeconomic consequences.¹¹⁶

CARE PROCESS

PATIENT OUTCOME CRITERIA

Treatment of thyroid eye disease is symptom directed, and targeted outcomes may include the following:

- Recognition and prevention of primary vision loss due to optic neuropathy, exposure keratopathy, and elevation in intraocular pressure (IOP)
- Restoration of ocular alignment
- Reduction of diplopia
- Improvement of compensatory head position

The goal of the strabismus surgeon is to re-establish single binocular vision in primary gaze and reading position and a substantial usable field of single binocular vision.

DIAGNOSIS

History

A detailed medical and ocular history should include specific questions about weight gain or loss, tachycardia, and unexplained fatigue potentially secondary to hyperthyroidism or hypothyroidism.

Strabismus is likely to be associated with diplopia and, in some cases, a compensatory head posture (i.e.,

ocular torticollis, often a chin-up position in this population). Because the incidence of myasthenia is increased in patients with TED, assessment for the coexistence of myasthenia is suggested if indicated by findings on clinical examination.

Examination

The examination should include a full sensorimotor examination, noting evidence of mechanical restriction. Forced ductions can confirm restriction but classic features, such as fixation duress (brow elevation and augmentation of eyelid retraction on attempted ocular elevation), may confirm the restrictive nature of the associated strabismus. Hypotropia of the affected eye(s) with esotropia is the most frequent deviation owing to involvement of the inferior and medial rectus muscles, although other rectus muscles are commonly involved, resulting in other strabismus patterns. More global extraocular muscle involvement may be apparent on orbital imaging or with forced duction testing.^{117,118}

The examination should also include the following elements:

- Binocular field testing to map the region of single binocular vision. Duction deficits can be measured and monitored using uniocular fields of fixation.
- Measurement of the exophthalmos by exophthalmometer, which is important diagnostically and to follow clinical course.
- Surveillance for optic neuropathy, paying close attention to acuity, color vision, visual fields, pupillary exam, and fundus exam (for disc edema or optic atrophy).
- Ocular coherence tomography and Humphrey visual fields, which provide ancillary information and are used to screen for or monitor possible associated compressive optic neuropathy.

Screening and management of possible associated optic neuropathy may fall within the expertise of the co-managing orbital specialist, e.g. neuro-ophthalmologist or oculoplastic surgeon.

Orbital CT or MRI can be performed to confirm the diagnosis and evaluate the size of the extraocular muscles and the volume of orbital fat. Imaging features include tendon-sparing enlargement of one or more of the extraocular muscles and proptosis. Muscle involvement and proptosis are often bilateral but frequently asymmetric.¹¹⁸ Imaging may also help determine whether the superior oblique is involved and demonstrate the degree of orbital apex crowding. The size of the rectus muscles as measured by CT does not however directly correlate with the degree of muscle dysfunction.¹¹⁹

Thyroid function and associated immune studies may be ordered, although this is typically handled by the associated primary care or endocrinology specialist; patients may be hyperthyroid, hypothyroid, or euthyroid at the time of presentation with TED.¹²⁰

MANAGEMENT

Ocular lubricants are almost always needed to combat exposure related to eyelid retraction and proptosis.

Punctal plugs can also be useful. Patients should be counseled to cease smoking.¹⁰⁷

Selenium supplementation in patients with selenium deficiency has been shown to reduce some inflammatory symptoms in patients with milder TED,¹²¹ perhaps in part through an antioxidant effect.¹²² It does not impact control of hyperthyroidism in populations, at least in populations that are not selenium deficient.¹²³ Treatment with teprotumumab, a human monoclonal antibody inhibitor of IGF-IR demonstrated to attenuate the actions of IGF-I, thyrotropin, thyroid-stimulating immunoglobulins, and immunoglobulins in patients with Graves' disease reduces proptosis and the clinical activity score of disease in many with active disease.¹²⁴

Orbital decompression, high-dose steroids, or radiation treatment should be considered, as indicated, for severe proptosis or optic neuropathy.¹²⁵ In patients with concurrent proptosis and significant strabismus, the predictable worsening of proptosis following recession of fibrotic muscles may warrant consultation with an orbital specialist to consider orbital decompression surgery prior to strabismus surgery. If orbital decompression is indicated, strabismus repair should be delayed until after the decompression because new onset or exacerbated strabismus may result.¹²⁶⁻¹²⁸ Shift of the extraocular muscles and the globe into newly available space, or, in some cases, disinsertion and reinsertion of the inferior oblique muscle to improve exposure, can significantly impact alignment.¹²⁹⁻¹³¹ There is some evidence that preserving the orbital strut may diminish the risk of new-onset strabismus.^{126,132}

Observation¹³³

Patients can be observed if there is no diplopia in primary gaze or reading position and should be observed if the angle of strabismus is not yet stable. Observation is also necessary if the patient requires orbital decompression surgery, as this procedure often changes ocular alignment.^{134,135}

Nonsurgical

Fresnel or ground-in prism can provide temporary relief from diplopia while awaiting definitive treatment or may be suitable for modest residual deviation after surgical correction.¹⁰⁷ Chemodenervation during the active phase of the disease is advocated by some for temporary relief of diplopia. Its use may favorably reduce the misalignment left after the initial inflammatory stage of the disease.¹³⁶⁻¹³⁹

Surgical

Surgery is required in most patients with persistent diplopia in primary or reading positions of gaze. This is usually undertaken when the inflammatory stage has subsided and the angle of deviation has been stable for at least 6 months,^{118,140} but earlier surgery in select patients can also have satisfactory outcomes and shorten the period of disability.¹⁴¹ Quiescence is usually determined on clinical grounds.¹⁴² Less frequently, MRI

sequences T2, FSE or fast spin echo, postcontrast T1 (T1Gad) signal intensity ratios and normalized-apparent diffusion coefficient (n-ADC)¹⁴³ and water content on STIR (Short TI Inversion Recovery) sequences may be used to determine if the disease has become quiescent.¹⁴⁴

Recessions of the restricted muscles are the mainstay of surgical correction. Resection is generally avoided in restrictive disease out of concern for further reducing ductions;¹¹⁸, but can be a useful adjunct in select cases,¹⁴⁵ particularly when extremely large recessions have not fully corrected the alignment.

The rectus muscles of the thyroid patient can be severely tight. Thyroid eye disease is the most commonly identified risk factor for development of “pulled in two syndrome,”¹⁴⁶ an unplanned horizontal transection of a rectus muscle that seems to spontaneously occur while it is hooked during surgery. Because this transection takes place typically 4 to 9 mm or further from the anatomical insertion, recovery of the already taught distal end can prove quite challenging.¹⁴⁶ Care should be taken during surgery to avoid this complication.

Surgery for horizontal deviations is more successful than surgery for vertical strabismus (84% vs. 66% success after the primary surgery).¹⁴⁰ Because the orbitopathy often affects the inferior rectus muscle, vertical deviations are more common.¹⁴⁷ Recession of the inferior rectus muscle is frequently complicated by consecutive hypertropia, in part, because of suboptimal contact of the recessed muscle with the globe,¹⁴⁸ ipsilateral superior rectus involvement,¹⁴⁹⁻¹⁵¹ or imbalanced contralateral disease.^{152,153} Use of the Kushner semi-adjustable suture technique may help minimize unanticipated muscle drift,¹⁵⁰ as may intentional undercorrection of the inferior rectus recession¹¹⁷ with the use of adjustable sutures,¹⁵⁴ wider spreading of the muscle to prevent sagging of the center of the insertion over time,¹⁵¹ and the use of permanent polyester sutures. Large bilateral inferior rectus recession may result in an A-pattern with unanticipated exotropia in downgaze as well as intorsion. This occurs because the superior oblique becomes the dominant infraductor;^{107,112} and may be exacerbated by primary involvement of the superior oblique muscle in the disease process.¹⁵⁵ Because managing vertical deviations in TED is complex, a step-by-step approach appraising preoperative and intraoperative forced ductions of all extraocular muscles and attention to preoperative and intraoperative ocular torsion may significantly minimize the risk of an undesired postoperative result.^{151,155} Recession of the inferior rectus muscle, even with careful dissection from the lower lid retractors, may result in lower lid retraction. Releasing restriction with recession of rectus muscles may result in increased proptosis of the globe.¹⁵⁶ Preoperative counseling with the patient and communication with the treating orbital surgeon are important in this regard. Recession of tenon’s capsule from overlying conjunctiva may augment the effect of rectus muscle recession and in turn improve postoperative ductions and the range of single binocular vision in select cases.^{157,158}

Surgeons generally prefer an absorbable suture (6–0 polyglactin) for isolating the muscle and reattaching it to the globe. Some surgeons favor non-absorbable sutures for large recessions of the inferior rectus muscle because they may reduce the risk of postoperative overcorrection.¹²⁰ The role of adjustable suture surgery in TED remains controversial. Some surgeons claim more successful results,¹⁵⁹ whereas others never use the technique because of concern over possible overcorrection and/or muscle slippage.¹⁶⁰ Some surgeons advocate a “relaxed muscle positioning technique” where the muscles are recessed to a position where they rest freely on the globe without tension.¹⁶¹ In patients with concurrent proptosis and significant strabismus, the predictable worsening of proptosis following recession of fibrotic muscles may warrant consultation with an orbital specialist for orbital decompression surgery prior to strabismus surgery.¹⁵⁶

PROVIDER AND SETTING

Diagnosis and management of strabismus in a patient with TED requires the training and clinical judgment of an experienced ophthalmologist comfortable with very complex strabismus and managing severe restrictive disease. Working under the supervision of an ophthalmologist, orthoptists can be an asset with the examination, diagnosis, and nonsurgical management of TED.

COUNSELING AND REFERRAL

A multidisciplinary approach to TED treatment is recommended, combining the expertise of endocrinology, oculoplastics, and neuro-ophthalmology as indicated. The ophthalmologist should discuss the findings, explain the disorder, provide diagnosis, and discuss management options with the patient and any caregivers.

SECTION II.f. STRABISMUS AFTER ORBITAL TRAUMA

INTRODUCTION

DISEASE DEFINITION

Strabismus after orbital trauma is common and may be present along with other ophthalmic, medical, and surgical conditions. Although all life-threatening and vision-threatening conditions need to be addressed before treating strabismus, the presence and pattern of ocular misalignment may indicate other orbital or central nervous system trauma guiding primary triage, imaging, and treatment.

Determining the cause of diplopia after orbital trauma requires a detailed history, examination, and, often, imaging. The etiology of the strabismus may be multifactorial, including direct damage to the extraocular muscles and surrounding orbital structures or contemporaneous trauma to the central nervous system. Rectus or oblique muscle avulsion, partial or complete “loss,” flap tear,^{162,163} hemorrhage, edema, or paresis may occur in addition to orbital hemorrhage or edema, soft tissue swelling, and fracture of orbital bones, with and without entrapment of muscle, fat, or muscle pulleys. Cranial neuropathies,¹⁶⁴ disorders of accommodation or convergence,¹⁶⁵ disruption of fusion, fusional amplitudes, saccades and smooth pursuit, decompensation of previous heterophoria, and other supranuclear defects may result in diplopia.¹⁶⁶

Diplopia is very common after orbital trauma and reported to occur in 58% to 68% of blowout fractures.¹⁶⁷⁻¹⁶⁹ Strabismus surgery was required in 7% to 24% of cases in two series of patients with orbital floor fractures.^{170,171} Less commonly, strabismus can occur iatrogenically after sinus surgery^{172,173} or other periocular surgeries, including surgery to the eyelids (See Section IIg Strabismus Associated With Other Ophthalmic Surgery).¹⁷⁴

PATIENT POPULATION

The patient population is adults with strabismus following orbital trauma.

CLINICAL OBJECTIVES

- Counsel the patient on the diagnosis and treatment options
- Provide goal-directed management of strabismus (reconstructive restoration of binocular vision, or treatment of diplopia or compensatory head posture)
- Inform the patient’s other health care providers of the diagnosis and treatment plan.

BACKGROUND

PREVALENCE AND RISK FACTORS

In self-reported population studies, the incidence of trauma in adults ranged from 1.7% to 19.8%.¹⁷⁵⁻¹⁷⁷ In all of these studies, younger age and male sex were identified as risk factors.¹⁷⁵⁻¹⁷⁷

NATURAL HISTORY

Diplopia may be transient following ocular trauma, but if it has not resolved within 6 months it is unlikely that it will resolve on its own.

RATIONALE FOR TREATMENT

Diplopia, loss of binocular vision, compensatory head position, and inability to make eye contact all warrant treatment.

CARE PROCESS

DIAGNOSIS

History

A detailed medical and ocular history, including specific questions about symptoms of diplopia, vision loss, and details on the nature and timing of the trauma are helpful.

Examination

A thorough examination should include vision testing, refraction (if possible), pupillary examination, IOP measurement, confrontational visual field testing, slit-lamp examination, a dilated (if safe) or undilated fundus examination (with attention to any torsion), testing of facial sensation, and exophthalmometry. The goal of the primary examination is to rule out any globe injury or sight-threatening injury. Patients with orbital or cranial trauma may also have decreased vision (secondary to corneal scars, traumatic cataract, optic neuropathy, or other damage to the retina or other ocular structures) or decreased visual fields. Care should be taken to note these limitations, as it may help guide test selection during the examination.

A detailed sensorimotor exam should be performed, with attention to versions, ductions, saccades, pursuit, vergence, and near reflex, along with alignment in multiple gaze positions with attention to primary and secondary deviations.¹⁷⁸ Forced duction and forced generation testing may help distinguish restriction from paresis of the extraocular muscles.¹⁷⁹ Double Maddox rod, Lancaster red-green, Hess screen, or synoptophore (especially if there is concern for disrupted central fusion) may also be helpful.

Vital signs looking for any bradycardia or heart block, along with symptoms of dizziness, nausea, vomiting, or loss of consciousness in a patient with orbital trauma may indicate an entrapped muscle causing the oculocardiac reflex.¹⁸⁰ This can be life threatening and usually requires medical and surgical treatment.

Imaging studies are frequently indicated. Computed tomography rather than MRI is required if there is any concern about a possible ferrous-metallic foreign body and often provides sufficient information about the presence of orbital fracture and entrapment. Magnetic resonance imaging provides more precise imaging of the extraocular muscles and surrounding tissues, including the pulley system, and reduces radiation exposure. It can sometimes be performed dynamically and provides additional useful information for planning an intervention.¹⁸¹⁻¹⁸⁴ Occasionally, patients with atypical strabismus demonstrate occult fractures absent a history of trauma recalled by the patient.¹⁸⁵

MANAGEMENT

General Guidelines

All life-threatening and vision-threatening conditions need to be treated before the strabismus. In one series of 379 patients who underwent surgical repair of facial fractures, 5.5% had complete loss of vision in one eye and 0.8% had complete loss of vision in both eyes.¹⁸⁶ Another series of blowout fractures demonstrated serious ocular injury in 24% of cases.¹⁸⁷

Timing of surgical repair of orbital fractures has been debated.^{168,169} Current recommendations for timing of repair of isolated orbital floor fractures are as follows:¹⁸⁸

- Immediate repair:
 - Immediate repair is indicated for patients with CT evidence of an entrapped muscle or periorbital tissue associated with a nonresolving oculocardiac reflex
 - “White-eyed blow-out fracture”¹⁸⁹, a form of trap-door fracture with muscle entrapment and oculocardiac reflex(seen in children) requires urgent repair as well.
 - Globe subluxation into the maxillary sinus, a rare occurrence, demands immediate surgical repair.^{190,191}
- Repair within 2 weeks:
 - Symptomatic diplopia with positive forced ductions or entrapment on CT and minimal improvement over time is best repaired within about 2 weeks. Significant fat or periorbital tissue entrapment can also result in permanent strabismus in the absence of muscle entrapment.¹⁹²
 - Large floor fractures, hypoglobus, and progressive infraorbital hypoesthesia are also best addressed within about 2 weeks.
 - Early enophthalmos or hypoglobus causing facial asymmetry will not resolve and are best addressed within about 2 weeks

- Delayed Repair:
 - Restrictive strabismus and unresolved enophthalmos may benefit from delayed repair
- Observation:
 - Observation may be considered in cases of minimal diplopia (not in primary or downgaze), and good ocular motility without significant enophthalmos or hypoglobus.

Guidelines for Treating Strabismus

Even with repair or observation of orbital fractures, strabismus and diplopia can persist. In a series of 54 patients who underwent repair of orbital blowout fractures, 86% had had diplopia preoperatively and 37% postoperatively.¹⁹³

Monitor/Observe

Some forms of strabismus after orbital trauma will improve with time, and watchful waiting is often a reasonable approach. A short burst of oral steroids can hasten recovery and uncover strabismus that will persist despite resolution of orbital edema/hematoma.

Nonsurgical

In the absence of muscle entrapment, waiting 4 to 6 months after orbital trauma is advised because strabismus may resolve on its own unless substantial fat and orbital pulley entrapment suggests benefit in earlier repair.¹⁹⁴ Conservative treatment such as occlusion, filters, Fresnel prisms, and prism glasses may provide temporary or permanent relief of diplopia.

Surgical

For patients who do not meet the criteria for early surgical intervention, waiting 4 to 6 months after the injury is advised to ensure stability of the misalignment prior to repair.¹⁷¹ The goals of surgical intervention should be clearly discussed with the patient and are often to eliminate diplopia in the primary position and downgaze and to enlarge the field of binocular single vision. More than one operation and supplementation with prism glasses may be required. Every situation is unique, and more than one method of repair is possible.¹⁹⁵ Preoperative forced generation and preoperative and intraoperative forced duction testing is very important.

Fat entrapment can prove nearly as challenging as extraocular muscle entrapment, resulting in fibrotic and adhesion syndromes not readily relieved with dissection around the involved muscle.¹⁹² Adhesions and entrapment may extend well into the deeper orbit, out of reach of the strabismus surgeon.

Adhesion of extraocular muscles, particularly to porous implants, can be equally problematic at times,^{196,197} as can iatrogenic disinsertion of the inferior oblique at its origin, which may be required to place an implant along the nasal wall of the orbit.¹⁹⁸

Some general principles include an attempt to recover “lost” muscles whenever possible.¹⁹⁹ If recovery of a muscle proves impossible or if a muscle is determined to be severely paretic, a transposition procedure may be indicated. Matching restriction with the use of posterior fixation sutures or Scott procedures (recess/resect)²⁰⁰ on the unaffected eye are established methods of expanding the field of single binocular vision. Adjustable sutures are often helpful in these cases.

Because the etiology of the strabismus may be multifactorial and the misalignment incomitant, complete elimination of diplopia is often difficult, if not impossible.

PROVIDER AND SETTING

A multidisciplinary approach may be required and it may be applied in different settings—an emergency department or inpatient or outpatient facilities. Diagnosis and management of strabismus caused by ocular trauma requires the training and clinical judgment of an experienced ophthalmologist. Working under the supervision of an ophthalmologist, orthoptists can be an asset in the examination, diagnosis, and nonsurgical management.

COUNSELING AND REFERRAL

Consultation or comanagement with comprehensive ophthalmology, oculoplastics, neuro-ophthalmology as well as plastics, otolaryngology, emergency department, and neurosurgery may prove necessary, depending on the circumstances of the injury and the timing of the strabismus evaluation.

SECTION IIg. STRABISMUS ASSOCIATED WITH OTHER OPHTHALMIC SURGERY

INTRODUCTION

This section focuses on strabismus acquired after the following procedures:

- Cataract extraction or Keratoplasty
- Glaucoma filtering
- Scleral buckling
- Pterygium excision
- Blepharoplasty and Ptosis Repair

Strabismus sometimes resulting in diplopia has been reported after virtually any periocular procedure including major orbital surgery as well as dacryocystorhinostomy. A detailed discussion on management of these causes of strabismus in the adult population is outside the purview of this PPP. However, determining whether muscle or nerve damage is responsible and whether paresis versus restriction is the major cause is a common theme that informs the evaluation and treatment of all forms of strabismus associated with other ophthalmic surgery.²⁰¹

DISEASE DEFINITION

Iatrogenic strabismus can occur following different procedures or treatments.

Cataract extraction or keratoplasty:

Anesthetic myotoxicity following retrobulbar or peribulbar anesthesia for any ocular procedure including cataract extraction or keratoplasty may occur. Initial presentation is usually transient paresis followed by deviation of the eye into the field of action of the involved extraocular muscle. The hypertropia or hypotropia may result from restriction of the involved extraocular muscle when damage is extensive, or as an overaction pattern due to focal contracture or muscle hypertrophy.²⁰²⁻²⁰⁶ Superior and inferior rectus muscles are the most commonly injured by regional and local anesthesia, in retrobulbar or peribulbar blocks,²⁰⁷ but any muscle including the superior and inferior oblique muscles, may be involved as well.²⁰⁸⁻
211

Surgical manipulation of orbital tissue from a bridle suture under a rectus muscle can also result in small-angle strabismus due to nicking the rectus muscle, local bleeding, and scar formation. Likewise, temporary disinsertion and subsequent reattachment of an extraocular muscle in the course of repairing a globe laceration may result in strabismus. Causes of binocular diplopia after cataract surgery or keratoplasty in

addition to local anesthetic myotoxicity and direct surgical manipulation of the extraocular muscles and periorbital tissue include: previously undiagnosed TED;²¹² pre-existing/unmasked binocular disorders; and fixation switch diplopia. These conditions are addressed in other sections of this PPP.

Glaucoma Filtering Procedures (including trabeculectomy and glaucoma plate reservoir surgery)

Motility disturbances occur from a variety of causes, including mass effect from the implant or associated bleb, scarring, fat adhesion, or incorporation of adjacent extraocular muscles.²¹³ These complications result in a wide array of motility patterns, including Brown syndrome, partial disinsertion of the superior oblique muscle, and restriction of gaze in the direction of the adjacent muscle.²¹⁴⁻²¹⁸

Scleral Buckling Procedures

Following scleral buckling procedures, the root cause of the resulting strabismus may be multifactorial. Patients may develop strabismus secondary to loss of fusion, poor vision, aniseikonia, direct trauma to the muscles, myotoxicity from retrobulbar anesthesia, malposition of a detached muscle, scar tissue formation, muscle slippage or disinsertion, entanglement of the superior oblique tendon, and mass effect.²¹⁹⁻²²² Fusional disturbance, aniseikonia, and torsional diplopia may sometimes accompany repair of retinal detachment, even without scleral buckling. These threats to binocular fusion increase the complexity of treating the mechanical aspect of strabismus induced by a buckling procedure.²²³

Pterygium Surgery

New-onset diplopia can occur after pterygium surgery as a result of direct injury to the adjacent medial rectus or florid scarring associated with recurrence.²²⁴⁻²²⁷ This can result in consecutive exotropia from medial rectus damage or restrictive incomitant esotropia from scarring.²²⁴⁻²²⁷

Blepharoplasty and Eyelid Procedures

New onset diplopia can occur after upper lid blepharoplasty, sometimes associated with trochlear damage,^{228,229} and after lower lid blepharoplasty, sometimes due to damage to the inferior rectus.²³⁰ Scarring and hemorrhage in adjacent tissue or fat adherence²³¹ has been implicated among other mechanisms.

New-onset diplopia can occur after ptosis repair as a result of late recognition of previously existing strabismus. The classic example would be double elevator palsy with a limitation of upgaze that is recognized only after the associated ptosis is repaired.

PATIENT POPULATION

The patient population is adults who have strabismus associated with other ophthalmic surgeries that may disrupt normal extraocular muscle function or sensory fusion.

CLINICAL OBJECTIVES

- Counsel the patient on the diagnosis and treatment options
- Provide goal-directed management of strabismus (to restore binocular vision, or minimize diplopia or compensatory head posture, and in some cases for the reconstructive benefit to improve eye alignment, eye contact, and self-image)
- Inform the patient's other health care providers, and in particular their ophthalmic specialists, of the diagnosis and treatment plan

BACKGROUND

Cataract extraction and keratoplasty

Incidence (anesthetic myotoxicity)

There is a 0.18% incidence of secondary strabismus²³² and a 0.23% incidence of secondary strabismus for cases involving retrobulbar block anesthesia used most often for cataract surgery. Diplopia may be transient or persist.²³²

Risk Factors

Risk factors that increase the incidence of secondary strabismus after retrobulbar or peribulbar block are injection by a nonophthalmologist, left eye injection, and the absence of hyaluronidase in the block.^{233,234}

Topical anesthesia is associated with a lower risk of diplopia than regional anesthesia. It is more typically associated with other factors that threaten binocular stability, such as the choice of monovision for cataract surgery or fixation switch diplopia.

Fixation switch diplopia occurs if a previously suppressed eye becomes the dominant eye. (See Section Iik. Oculomotor Palsy.)

GLAUCOMA-FILTERING PROCEDURES

Incidence

Transient strabismus occurs in 1% of patients after trabeculectomy^{201,235} and in 3% of patients following glaucoma plate reservoir surgery.^{201,235,236} Persistent motility disorders can range from 2% to 77%²³⁵ following glaucoma plate reservoir surgery depending, in part, on the type of implant used, the length of

follow-up, and whether the setting was one that afforded an adequate audit of postoperative alignment. One center reported a prevalence of binocular diplopia of 21% in those treated with plate reservoir surgery and 3% in those treated with trabeculectomy.²¹³

Risk Factors

Advanced age is a risk factor for the development of binocular diplopia.²³⁵ Superior placement of plate reservoir versus inferior placement may be associated with less risk of diplopia in the reading position.^{201,235}

SCLERAL-BLUCKLING PROCEDURES

Incidence

Ocular motility disturbance is reported in up to 60% of patients after retinal detachment repaired by scleral buckle.²³⁷ The strabismus may be transient and resolve within 6 months. Persistent strabismus, however, has been reported in up to 23% of patients treated with an encircling scleral buckle procedure, although not all required strabismus surgery.²³⁸ In another single center study of 1030 patients treated with a scleral buckling procedure, only 3.8% had persistent strabismus and were referred for intervention.²³⁹

Risk Factors

The risk of strabismus after placement of a radial scleral buckle is substantially less than after placement of an encircling band.²³⁸

BLEPHAROPLASTY AND EYELID PROCEDURES

Incidence

The incidence of strabismus is very low, estimated at under 3% (three cases in 920 procedures) and much lower in association with other eyelid procedures.²⁴⁰

Risk Factors

Excessive cautery, hemorrhage, and misdirected dissection likely causes strabismus, but there are no other identified risk factors.

NATURAL HISTORY

As noted above, diplopia may be transient following other ocular surgeries, but if it has not resolved or demonstrated improvement within 6 months of the procedure, diplopia is less likely to resolve on its own.

RATIONALE FOR TREATMENT

Diplopia, loss of binocular vision, compensatory head position, and inability to make eye contact with poor eye alignment all warrant treatment.

CARE PROCESS

PATIENT OUTCOME CRITERIA

- Reduction of diplopia
- Improvement in or return of binocular vision
- Improvement of compensatory head position
- Restoration of ocular alignment, improved eye contact, and self-esteem.

DIAGNOSIS

History

A detailed medical and ocular history, including specific questions about particular surgical procedures, anesthetic used, and onset of patient symptoms should be obtained.

Examination

A detailed sensorimotor evaluation, assessment of refractive status, and dilated fundus examination should be performed to assess the oculomotor status, including possible ocular torsion impacting fusion. In-office forced ductions, if tolerated, may help determine the significance of the restrictive component. If this is not possible, the impact of mechanical restriction can be determined at the time of surgery.

Strabismus following retrobulbar or peribulbar block is characterized by an initial paresis with underaction of the affected muscle or more extensive contracture resulting in limitation strabismus, followed by segmental contracture of the affected muscle resulting in overaction of the muscle. The most commonly affected muscle is the inferior rectus muscle (70%).²⁰² Strabismus following glaucoma plate reservoir surgery usually presents within 3 months of glaucoma implant placement, often within the first month.^{218,236} Superotemporal implants more frequently cause hypertropia and exotropia, and restriction or scarring may create a “pseudoresection” effect on adjacent muscles.^{218,241} Superonasal implants more frequently cause hypotropia.^{215,217,218,236} In patients who present with ocular deviation away from the implant, the mechanical bulk of the implant (e.g., in the superior nasal quadrant) may be responsible.^{133,214,217,218}

In patients who have had scleral buckling, strabismus is usually incomitant and restrictive with limitations to ocular rotations. Approximately 50% of the patients with diplopia have a torsional component, usually excyclotropia.²¹⁹ Evaluation on the synoptophore is helpful, using fusible targets with square contours, to determine how much torsional correction is needed to restore single vision.

In patients postblepharoplasty or other eyelid surgery, strabismus may be transient. Many cases improve after 8 to 15 months if it is the result of local injury or hemorrhage without permanent loss of function or significant scarring.²⁴⁰ As diplopia is often incomitant, prism correction is rarely satisfactory in the long run and a combination of imaging, forced ductions, and surgical exploration may be required to maximize the outcome.

MANAGEMENT

Monitor/Observe

The patient should be monitored/observed if symptoms are mild, occasional, and not bothering the patient or if the patient is opposed to treatment. If the potential compromise to optic nerve function with removal of the reservoir is too great for patients with a glaucoma plate reservoir, other options such as prism correction, occlusion, and contralateral eye surgery may need to be considered. Close communication with the physician treating the patient's glaucoma often clarifies a course of action that facilitates surgical treatment of the secondary strabismus, along with a method of controlling IOP.

Nonsurgical

Transient strabismus is common, so early treatment with prisms may be offered. Prisms may also be helpful for residual diplopia following strabismus surgery.

Surgical

For patients with persistent strabismus, prisms and surgery are recommended. Patients may require multiple surgeries, including surgery in the non-affected eye. In general, surgery of the affected eye is indicated in patients who have limited ocular rotations in the affected eye. Surgery on the non-affected eye may be considered when, for example, surgery designed to match restrictions seems preferable, or when there is minimal mechanical strabismus and surgery on the contralateral eye is preferable to reduce the risk of destabilizing the achieved outcome for the involved eye.²¹⁸

For patients with a glaucoma plate reservoir, if the potential compromise to optic nerve function with removal of the reservoir is too great, other options such as prism correction or occlusion may need to be considered. Close communication with the physician treating the patient's glaucoma often clarifies a course of action that facilitates surgical treatment of the secondary strabismus, along with a method of controlling IOP. When operating in the field of a glaucoma implant, the surgeon should be prepared to manage hypotony and the added risk of intraocular infection if an intraocular breach occurs.

Generally, careful evaluation with forced ductions at the time of surgery will clarify the mechanism of the induced strabismus. High resolution MRI may provide additional insight into the multiple causes of misalignment and thus inform management.²⁴²

In patients with a scleral buckle, factors associated with better surgical outcomes include small preoperative deviation and minimally restricted ocular rotations. In patients with ocular torsion, exploration of the superior oblique tendon and the inferior rectus muscles should be considered.²¹⁹ The benefits of removing a scleral buckle are controversial. Some surgeons believe it is almost never necessary to remove the buckle and they will recess, resect, and transpose muscles and tendons over, under, and around the hardware, whereas other surgeons prefer to remove the buckle at the time of strabismus surgery.^{243 244} The risk of retinal re-detachment is about 8% after scleral buckle removal.²⁴⁵ Preoperative discussion with the specialist who placed the periocular hardware, or another colleague in this subspecialty, should address the risks associated with displacement of this hardware. Some procedures might benefit from having both surgeons present and scrubbed for the strabismus repair.

Chemodenervation (botulinum toxin) has proven successful in some cases.²⁴⁶ Regardless of the etiology, a careful sensorimotor evaluation with attention to torsional strabismus and incomitance, forced ductions, and surgical exploration may be necessary to optimize outcomes because the details of repair will be determined on a case-by-case basis,

PROVIDER AND SETTING

Diagnosis and management of strabismus occurring after other ocular surgery requires the training and clinical judgment of an experienced ophthalmologist. Communication, as possible, should be established with the surgeon who is performing the original surgical procedure that is associated with the development or exacerbation of strabismus. Working under the supervision of an ophthalmologist, orthoptists can be an asset in the examination, diagnosis, and nonsurgical management. Optometrists may add additional support in the management of aniseikonia, or contact lens fitting, as appropriate.

COUNSELING AND REFERRAL

The ophthalmologist should discuss the findings, explain the disorder, provide diagnosis, and discuss management options with the patient, the referring ophthalmic surgeon, and any caregivers. When surgical treatment of the strabismus is considered, consultation with the specialist who performed the initial surgery, or another ophthalmologist with expertise in the relevant subspecialty is recommended. This should include a discussion of the potential impact of removing or disrupting implanted hardware. Review of the surgical record from the index case can provide additional information on the approach to the surgical field

SECTION IIh. SUPERIOR OBLIQUE PALSY

INTRODUCTION

DISEASE DEFINITION

Superior oblique palsy (SOP) is due to partial or complete paralysis of the fourth cranial nerve (trochlear nerve), resulting in weakness of the superior oblique muscle. The motility disturbance creates a combination of vertical, torsional, and, to a lesser degree, horizontal incomitant strabismus pattern. Both congenital and acquired forms exist, with the presumed congenital type often presenting for the initial evaluation in adulthood.²⁴⁷

Patients will show hypertropia of the involved eye, often accompanied by a compensatory head tilt away from the affected eye. Complaints include diplopia, asthenopia, and/or anomalous head posture. Patients with decompensated congenital SOP may have facial asymmetry, demonstrating a shorter maxilla on the opposite side of the SOP (and thus reduced distance between the corner of the mouth and lateral canthus).²⁴⁸

Head trauma (including concussion) is one of the most common identifiable causes of both unilateral and bilateral acquired superior oblique palsy, although in extremely rare cases isolated trochlear schwannomas and giant cell arteritis can result in acquired SOP.^{249-251, 247}

Skew deviation has a motility pattern that can resemble the misalignment seen with superior oblique palsy. Distinguishing characteristics, particularly related to fundus torsion, symptoms of ocular tilt and, at times, the impact of upright versus supine positioning of the patient are described at length in Section Iii. Skew Deviation.²⁵² Distinction is critical as skew deviation is more frequently associated with less benign etiology.

PATIENT POPULATION

The patient population includes adults with strabismus associated with congenital or acquired superior oblique palsy.

CLINICAL OBJECTIVES

- Determine if SOP is congenital or acquired and unilateral or bilateral
- Counsel the patient on the diagnosis and the treatment options
- Provide goal-directed management of strabismus (reconstructive to enhance binocular vision, reduce diplopia or a compensatory head posture)
- Inform the patient's other health care providers of the diagnosis and treatment plan

BACKGROUND

INCIDENCE

Superior oblique palsy is one of the common types of vertical strabismus seen in adults. Annual incidence has been reported to be 6.3 cases per 100,000 people, with a higher incidence among males than females.⁶³

RISK FACTORS

Risk factors include head trauma and age-related decompensation of congenital weakness.

NATURAL HISTORY

Patients may experience no diplopia or only intermittent diplopia in cases of longstanding and presumed congenital superior oblique palsy. A longstanding and effective compensatory head position minimizes diplopia awareness by avoiding the field of action of the weak superior oblique muscle.

RATIONALE FOR TREATMENT

Diplopia, compensatory head position sometimes associated with neck pain, and asthenopia warrant treatment.

CARE PROCESS

PATIENT OUTCOME CRITERIA

Treatment in adult strabismus is symptom directed, and targeted outcomes may include:

- Reconstruction of ocular alignment
- Improved binocular vision
- Improved control of diplopia, especially in the primary position and in side gaze
- Reduction in compensatory head position

DIAGNOSIS

History

A detailed medical and ocular history, including specific questions about prior head trauma, diplopia, and compensatory head posture is important. Sometimes a review of prior photos demonstrates a pattern of longstanding and potentially worsening compensatory head posture.

Examination

A sensorimotor evaluation with special attention is recommended to measure torsion and determine position of gaze with the greatest deviation. The Parks Bielschowsky three-step test is often used to confirm the diagnosis. Hypertropia is greatest in opposite lateral gaze and head tilt to the same side. Assessing whether torsion is a barrier to fusion is an essential part of the evaluation. Quantifying the magnitude and direction of torsional diplopia enhances surgical planning. As the superior oblique intorts, excyclotorsion is commonly found and may be documented with Double Maddox Rod or Lancaster Red Green testing and by noting fundus torsion.

Refractive status should be included in the examination. A neurological evaluation and neuroimaging are controversial but are rarely indicated in cases of isolated unilateral SOP or bilateral cases in which trauma is the known cause. Symptomatic diplopia with poor fusional amplitudes may be an indication for brain and/or orbital MRI with contrast, because it may indicate an acquired SOP due to trochlear schwannoma. Neuroimaging should always be performed if there are additional central nervous system signs or symptoms.²⁵³ Occult thyroid eye disease can present as new-onset vertical diplopia with a positive three-step test²⁵⁴ and giant cell arteritis remains within the differential diagnosis.

Exaggerated forced ductions often reveal a lax superior oblique tendon in many patients with presumed congenital SOP.²⁵⁵ Forced ductions done in-office or at the time of surgery may reveal evidence of an ipsilateral limitation of downgaze due to superior rectus contracture or contralateral restriction of elevation due to inferior rectus contracture.

MANAGEMENT

Monitor/Observe

The patient should be monitored/observed if symptoms are mild, occasional, and not bothering the patient or if the patient is opposed to treatment.

Nonsurgical

Small vertical deviations may be managed with prism glasses, although lateral incomitance, if present, often precludes successful implementation.

Surgical

Torsional surgery will be needed if torsion is a barrier to fusion (typically in bilateral cases or severe unilateral cases due to trauma or cases associated with neurosurgery). Larger and incomitant deviations most often require surgical intervention. Some patients with smaller deviations may prefer surgical repair or prism correction. The goal of surgery is to improve the vertical and torsional deviation, improve the head posture, and improve the area (field) of single binocular vision. A variety of surgical choices exist, and the

decision for which muscle(s) to operate on depends on the magnitude of deviation in primary gaze, the degree of torsion, and the field of gaze with greatest deviation. The most common procedures used include the following (in combination or alone):

- Inferior oblique weakening by recession or myectomy (ipsilateral)
- Inferior rectus weakening (contralateral)²⁵⁶
- Superior oblique strengthening, for example, tuck (recommended for lax tendons in presumed congenital SOP²⁵⁵), advancement for vertical and torsional deviations,²⁵⁷ or a version of the Harada-Ito procedure, advancing only the anterior SO fibers that affect torsion (ipsilateral)^{258,259}
- Superior rectus weakening (ipsilateral)²⁶⁰

Many of the above procedures may be performed using adjustable suture techniques; the target angle should be a small undercorrection because overcorrection, particularly in downgaze, is extremely poorly tolerated.

PROVIDER AND SETTING

Management of SOP, specifically surgery, requires the training and clinical judgment of an experienced ophthalmologist and in some cases a neuro-ophthalmologist.²⁵⁶ Working under the supervision of an ophthalmologist, orthoptists can be an asset in the examination, diagnosis, and nonsurgical management of SOP.

COUNSELING AND REFERRAL

If the SOP is not isolated or is associated with other neurological signs and symptoms, neuroimaging and referral to a neurologist or neuro-ophthalmologist should be considered. Small vertical fusional amplitudes in a case of isolated SOP, absent a history of trauma, may indicate an acquired cause and should be evaluated with neuroimaging. The ophthalmologist should discuss the findings, explain the disorder, provide diagnosis, and discuss management options with the patient and, as appropriate, with a neuro-ophthalmologist, or other specialist, as indicated.

SECTION III. SKEW DEVIATION

INTRODUCTION

DISEASE DEFINITION

Skew deviation is a vertical strabismus associated with disorders of the end-organ vestibular pathways within the ear (such as acute vestibular neuronitis) or associated supranuclear utriculo-ocular pathways within the posterior fossa including both the brainstem and cerebellum.²⁶¹⁻²⁶⁵ The characteristic vertical strabismus may be comitant or incomitant and results in vertical diplopia associated with ocular torsion, torticollis, and a tilt of the vertical visual field referred to as the ocular tilt reaction.^{252,266} The ocular tilt reaction produces a head tilt towards the shoulder of the hypotropic eye and both eyes rotate in the direction of the head tilt. If the patient experiences tilt of the vertical visual field, it will be in the same direction as the head tilt.²⁶⁷ With skew deviation, the hypertropic eye will demonstrate fundus incyclotorsion and the hypotropic eye will demonstrate fundus excyclotorsion.²⁶⁷ This characteristic helps to distinguish it from fourth nerve palsy, where the hypertropic eye is most typically excyclotorted. (In the absence of skew deviation, head tilt results in a compensatory fundus rotation opposite the direction of the head tilt.) Ocular torsion in skew may be conjugate or dysconjugate.

It is critical to distinguish skew deviation from fourth nerve palsy because causes of skew deviation demand immediate recognition and sometimes treatment (e.g., acute vestibular neuronitis, demyelination, or stroke) and urgent imaging of the brain and brainstem (MRI with and without contrast seeking evidence of demyelination, stroke, or mass lesion) may be needed. Most cases of isolated fourth nerve palsy (discussed in detail in Section IIIh. Superior Oblique Palsy) are more benign in etiology. Because vertical misalignment in superior oblique nerve palsy may become comitant over time and skew may be comitant or incomitant, and because both characteristically demonstrate head tilt away from the hypertropic side, the classic three-step test may not distinguish the two. The upright-supine test (a fourth step for the three-step test) has been proposed after demonstration that hypertropia reduces by 50% in the supine position for patients with skew deviation (sensitivity 80%; specificity, 100%). Subsequent to introduction of the upright-supine test, other investigators demonstrated that this distinctive decrease in hypertropia was not reliably found in patients with acute onset skew deviation.²⁶⁸ These authors concluded that the upright-supine test was not a reliable method to distinguish *acute* skew deviation (onset within 2 months) from SOP, although this test might prove useful in the setting of more longstanding skew deviation.

PATIENT POPULATION

The patient population consists of adults with acute peripheral vestibulopathy (vestibular neuronitis), or demyelination, ischemia, or mass lesions affecting the vestibular supranuclear pathways within the region of the brainstem and cerebellum

CLINICAL OBJECTIVES

- Recognition of skew deviation and institution of appropriate ancillary testing and referral to colleagues with expertise in otolaryngology or neurology, as indicated for further evaluation and management

BACKGROUND

PREVALENCE

The prevalence of skew deviation is unknown because it is associated with a variety of etiologies.

RISK FACTORS

Because there are multiple disparate causes, risk factors vary for skew deviation. Vestibular neuronitis can occur at any age. Demyelinating disease affects females more than males and both demyelination and trauma are more common in younger adults. Cardiovascular risk factors associated with stroke, such as a history of hypertension, diabetes, hyperlipidemia and smoking, have a greater impact in the aging population.

NATURAL HISTORY

Vestibular neuronitis may be self-limiting and respond to medical intervention, and transient ischemia in the posterior fossa may, likewise, cause a transient skew deviation that resolves over time.²⁵² More profound ischemic damage or mass lesions often result in long-lasting symptoms of skew deviation.

RATIONALE FOR TREATMENT

Control of disabling diplopia and perceived tilt of the subjective visual vertical warrant treatment.

CARE PROCESS

PATIENT OUTCOME CRITERIA

Treatment in adult strabismus is symptom directed, and targeted outcomes may include:

- Improved binocular vision
- Improved control of diplopia

- Reduced tilt of the subjective visual vertical

DIAGNOSIS

History

Skew deviation is almost always acute to subacute in onset. However, if the etiology is demyelination or a slow-growing tumor, the onset may be more insidious. Skew associated with acute vestibular neuronitis will likely be associated with severe vertigo, dizziness, nausea, and vomiting, whereas skew in association with brainstem or cerebellar demyelination, stroke, or a mass lesion, will demonstrate associated neurologic features that may include nystagmus, INO, hemiparesis, sensory loss, ataxia, and Horner's syndrome, to name a few, depending on the locus of the pathology, and may be acute to subacute in onset.

A history of neurological symptoms (motor or sensory changes, ataxia, headache) or symptoms of vertigo and nausea, in addition to the classic vertical diplopia and head tilt may help guide additional evaluation. Vertical diplopia and commonly torticollis and subjective tilting of the perceived visual world are characteristic.^{252,266}

Examination

The examination should include the following elements:

- Complete ophthalmic examination with emphasis on the sensorimotor evaluation and completion of the three-step test and consideration of the upright-supine test.
- Careful checking for other neuro-ophthalmic signs and symptoms looking for Horner's syndrome, cranial nerve palsy, internuclear ophthalmoplegia (INO), nystagmus, and hearing loss
- Fundus examination to check for papilledema or optic atrophy
- Visual field testing, which may provide additional information on the etiology
- Abnormalities in the rostral pons and midbrain (e.g., INO) will result in contralateral hypotropia and head tilt, whereas abnormalities in the vestibular periphery, medulla, and more caudal pons will result in ipsilateral hypotropia and head tilt.²⁶⁷

MANAGEMENT

The primary diagnostician should refer the patient for evaluation by indicated neurology or otolaryngology specialists. Initial treatment with prism may be helpful to manage diplopia while waiting for possible recovery, and botox, prism, or strabismus surgery may be considered for cases that do not resolve. The goals of surgery should be customized for the individual patient, who may be bothered to different degrees by diplopia, head tilt, and perceived tilting of the visual vertical. These interventions may help reduce both vertical and torsional diplopia, they may reduce the perceived tilting of the visual field, and in select cases they may prove successful at resolving head tilt.²⁶⁹⁻²⁷¹

PROVIDER AND SETTING

Diagnosis and management of skew deviation requires the training and clinical judgment of an experienced ophthalmologist and in some cases a neuro-ophthalmologist. Working under the supervision of an ophthalmologist, orthoptists can be an asset in the examination, diagnosis, and nonsurgical management of SOP.

COUNSELING AND REFERRAL

Referral to specialists in neurology, otolaryngology, or neuro-otology may be indicated based on the likely cause of the skew deviation.

SECTION IIj. ABDUCENS PALSY

INTRODUCTION

DISEASE DEFINITION

Abducens palsy is also known as sixth nerve palsy. It typically presents with an acute onset of horizontal double vision, worse at distance than at near and worse laterally toward the side of the affected nerve. Most often the double vision is noticed by the patients in primary position, but in partial paralysis it may only be noted on lateral gaze. Some patients present with a head turn to compensate for the diplopia caused by the paralysis. The incomitant horizontal misalignment described can result in disabling and disturbing diplopia at onset.²⁷² Symptoms may be less bothersome, or even subtle, if the palsy is partial, gradual, and chronic, permitting the development of horizontal fusional amplitudes. The diplopia may become more apparent with exhaustion or systemic illness, or in extreme horizontal gaze.

The majority of acute sixth nerve palsies in the adult population are vasculopathic, associated with risk factors such as diabetes and hypertension.²⁷³ The onset of double vision is acute, may be accompanied by pain, and does not have any associated neurologic or ocular findings. Most palsies resolve after 6 months, and about one-third resolve within 8 weeks. If no recovery is apparent by 6 months, approximately 40% of patients demonstrate a serious underlying pathology warranting further evaluation.²⁷⁴ The elderly who present with symptoms of scalp or temporal region tenderness, or pain with chewing (jaw claudication) may have giant cell arteritis, a more serious vasculopathic disorder that can result in permanent visual loss if not promptly diagnosed and treated.

Other common causes of sixth nerve palsy are trauma and neoplasm. Traumatic etiology is usually self-evident and may include a history of head injury, typically involving a basilar skull fracture, or an acute rise in intracranial pressure from an intracranial bleed.^{275,276}

A sixth nerve palsy caused by an intracranial neoplasm may be either insidious or acute. Neurologic changes may include other motor deficits, depending on the topographic location detailed below. Evaluation for facial and extremity motor weakness, third- and fourth-cranial nerve involvement, visual field defect, and central acuity from optic nerve involvement, IOP, and proptosis all help in localization. Bilateral sixth-nerve involvement can be seen in the clival chordoma as well as increased intracranial pressure or a meningeal process.^{275,277} A sixth nerve palsy can be associated with demyelinating diseases such as multiple sclerosis. Because lesions typically involve the pons, other neurologic findings are present, most notably a facial palsy, because the seventh nerve curves over the sixth-nerve nucleus. However, isolated cranial nerve VI palsy is the most common in adults. Postviral sixth nerve palsy can occur, but it is typically a diagnosis of exclusion.²⁷⁸

PATIENT POPULATION

The patient population is adults with strabismus caused by sixth nerve palsy.

CLINICAL OBJECTIVES

- Determine the etiology of the sixth nerve palsy
- Counsel the patient on the diagnosis and treatment options
- Provide goal-directed management of strabismus (typically to reduce symptoms of diplopia or secondary compensatory head posture diplopia)
- Inform the patient's other health care providers of the diagnosis and treatment plan

BACKGROUND

INCIDENCE

The annual incidence of new-onset sixth nerve palsy is approximately 11 per 100,000.²⁷³

RISK FACTORS

Risk factors relate to etiology but, as vascular etiology is the most common, both hypertension and diabetes increase the risk.

RATIONALE FOR TREATMENT

Diplopia, loss of binocular vision, compensatory head position, and inability to make eye contact all warrant treatment.

CARE PROCESS

PATIENT OUTCOME CRITERIA

Treatment in adult strabismus is symptom directed, and targeted outcomes may include:

- Reduction of diplopia
- Resolution of torticollis
- Reconstruction of ocular alignment
- Improvement of binocular vision

DIAGNOSIS

Understanding the path of the sixth nerve aids localization of the lesion as well as the cause.²⁷⁹ The sixth nerve originates in the abducens nucleus of the pons. Thus, lesions involving the sixth nerve nucleus often are accompanied by an ipsilateral facial paralysis or a complete horizontal gaze deficit. Within the pons, it courses through the corticospinal tracts, and thus, lesions involving the sixth in this region can lead to a contralateral

hemiparesis. The nerve then ascends in the subarachnoid space and passes underneath the petroclinoid ligament to enter into the cavernous sinus. Tethering of the nerve along this pathway make it susceptible to stretching from increased intracranial pressure, cerebrospinal fluid inflammation, infection, infiltration, or compression from clival tumors.

In the cavernous sinus, the sixth nerve is in close proximity to the intracavernous carotid artery; ocular sympathetics; and cranial nerves three, four, and the first division of the trigeminal nerve. Thus, carotid artery aneurysms, inflammatory cavernous sinus processes, or other structural lesions may include a concomitant Horner's syndrome, third nerve palsies and fourth-nerve palsies, or facial pain.²⁸⁰ The sixth nerve then passes through the superior orbital fissure into the orbit.²⁸¹ Orbital infections, mass lesions, or inflammation can affect the sixth nerve as well as the lateral rectus muscle itself. Associated proptosis and optic neuropathy may be present. Venous congestion from either an orbital process or back pressure from cavernous sinus lesions can cause chemosis with increased IOP.

History

A detailed medical history should include information and medical records on prior ocular surgery, a history of diabetes or hypertension, and complaints of specific additional symptoms, including facial weakness, motor weakness, headache, fever, proptosis, vision loss, scalp pain or jaw claudication that might reflect the anatomical locus and cause of sixth nerve pathology.

Examination

The examination should include the following elements:

- Complete ophthalmic evaluation with emphasis on best-corrected acuity, a check for afferent defect, and color acuity to screen for orbital and cavernous sinus pathology
- Sensorimotor examination demonstrating incomitant esotropia, typically greater at distance, and possibly associated with abduction nystagmus
- Fundus examination to look for papilledema or optic atrophy as indicators of elevated intracranial pressure

Ancillary Testing

Neuroimaging should be considered in all young patients or in any patient manifesting other cranial neuropathies, other neurologic change or elevated IOP, or if there are no compelling vasculopathic risk factors. Study should seek possible evidence of neoplasm, demyelination, stroke, vascular abnormality, or signs of infectious or inflammatory etiology. Referral to a neuro-ophthalmologist or neurologist for further evaluation may be indicated in some cases.

In an elderly patients with hypertension, hyperlipidemia or diabetes, and without temporal tenderness, jaw claudication or scalp pain, evaluation may be limited to determining blood pressure, serum glucose level, and hemoglobin A1c. Follow-up is necessary to determine if the palsy spontaneously resolves. In the absence of resolution or improvement, MRI of the brain with and without contrast may be indicated. In the elderly with a history of scalp tenderness, jaw claudication, or pain, the erythrocyte sedimentation rate and C-reactive protein should be checked immediately and a temporal artery biopsy performed if the results indicate possible giant cell arteritis. Consultation with a neuro-ophthalmologist may facilitate a biopsy and initiation of treatment.

Evidence of increased intracranial pressure with papilledema, bilateral sixth nerve palsy, or meningeal signs (stiff neck with headache) suggests a need for lumbar puncture following neuroimaging to measure intracranial pressure and look for meningitis (infectious, inflammatory, or carcinomatous) or demyelination. Systemic serology in this instance should include Lyme and syphilis testing.²⁸²

MANAGEMENT

A detailed treatment of the sixth nerve palsy is initially directed to the primary cause. Neuroimaging should be considered in all young patients or in any patient manifesting other cranial neuropathies, other neurologic change or elevated IOP, or signs of elevated intracranial pressure, or if there is no compelling vasculopathic risk factor. In the aging population with vasculopathic risk factors, lack of resolution over time suggests a need for neuroimaging. At onset, a history of scalp tenderness, jaw claudication, or pain should prompt evaluation for possible giant cell arteritis. From the ocular motility standpoint, symptomatic intervention is to reduce diplopia and torticollis and to restore binocular vision.

Monitor/Observe

The patient should be monitored/observed if symptoms are mild or if the patient is opposed to treatment.

Nonsurgical

Nonsurgical treatment for abducens palsy can include occlusion (with a patch over one eye or with a Bangerter filter or satin tape applied to a lens of the glasses) unless a comfortable region of single binocular vision is achieved with minimal compensatory head posture. Prisms can also be used temporarily, and if the deviation remains stable and fusion can be achieved, a ground-in base-out prism can be incorporated into the lenses.²⁸³ Chemodenervation (botulinum toxin) of the medial rectus muscle may help reduce secondary contracture and the severity of compensatory head position.^{284,285}

Surgical

Strabismus surgical management is generally offered when the deviation persists after 6 months from onset. A small residual deviation with some residual abducting force of the lateral rectus past the midline usually responds well to a medial rectus recession and lateral rectus resection. Other options include a contralateral medial rectus recession, with or without posterior fixation, with or without ipsilateral lateral rectus resection, to balance ductions. Larger deviations with no abducting force of the lateral rectus (confirmed by

force generation testing) usually necessitate some form of transposition procedure of the vertical recti laterally (often combined with medial rectus weakening by recession or injection of botulinum toxin) either initially or subsequently.

Many techniques for vertical rectus transposition have been described, including full-tendon or partial-tendon transfer, of one or both vertical rectus muscles, with or without an augmentation suture.^{278,286-289} Partial tendon transfer, or loop myopexy, may decrease the incidence of anterior segment ischemia, since three extraocular muscles are not operated on at the same time.^{289,290} Superior rectus muscle transposition alone with simultaneous medial rectus recession has similar advantages. When performing transposition of both vertical rectus muscles, staging the procedure by performing transpositions followed months later by medial rectus recession also decreases the risk of anterior segment ischemia.²⁹¹

PROVIDER AND SETTING

Diagnosis and management of sixth nerve palsy requires the training and clinical judgment of an experienced ophthalmologist. Working under the supervision of an ophthalmologist, orthoptists can be an asset in the examination, diagnosis, and nonsurgical management of sixth nerve palsy.

COUNSELING AND REFERRAL

Neuroimaging should be considered in all young patients or in any patient manifesting other cranial neuropathies, other neurologic change or elevated IOP, or signs of elevated intracranial pressure, or if there are no compelling vasculopathic risk factors. In the aging population with risk factors, lack of resolution over time suggests a need for neuroimaging. Referral should also be considered to those providers who have expertise in neuro-ophthalmology and adult strabismus, if the primary diagnosis is uncertain, and for directed treatment. The ophthalmologist should discuss the findings, explain the disorder, provide diagnosis, and discuss management options with the patient and, as appropriate, with a neuro-ophthalmologist, or other subspecialist, as indicated. Despite the number of strabismus surgical options for repair, patients should be advised that the goal of treatment is to eliminate diplopia in the primary position and to create a reasonable field of single binocular vision. Patients will most likely continue to have diplopia in more extreme lateral gaze because of the difficulty in balancing ductions given the underlying neurological deficit.

SECTION IIk. OCULOMOTOR PALSY

INTRODUCTION

DISEASE DEFINITION

Oculomotor palsy is also known as a third nerve palsy and is the second most common cranial neuropathy.²⁹²

Patients usually present with diplopia secondary to misalignment that has both a horizontal and vertical component, and sometimes with difficulty reading secondary to accommodative deficiency. Because the eyelid can be partially or completely ptotic, the subjective complaint of diplopia may be lessened because visual axis may be occluded.

The presentation is an incomitant deviation. In addition to ptosis from levator dysfunction, paresis of the superior rectus, inferior oblique, medial rectus, and the inferior rectus muscles typically leaves the eye abducted and infraducted as a result of preserved lateral rectus and superior oblique muscle function. Variants of misalignment may be present, particularly if the location of the inciting pathology is intracavernous or intraorbital, since the nerve has already divided into an upper and lower division. The pupil may or may not be involved, and it is important to note this characteristic, because it helps direct the evaluation.

PATIENT POPULATION

The patient population is adults with strabismus caused by oculomotor palsy.

CLINICAL OBJECTIVES

- Determine the etiology of the third nerve palsy
- Counsel the patient on the diagnosis and treatment options
- Provide goal-directed management of strabismus (reconstruction, binocular vision, or reduction of diplopia)
- Inform the patient's other health care providers of the diagnosis and treatment plan

BACKGROUND

INCIDENCE

The annual incidence of acquired third-nerve palsy is approximately 4 per 100,000.²⁹³

RISK FACTORS

Patients with hyperlipidemia, hypertension, and diabetes are at greater risk of vasculopathic third nerve palsy.^{293,294} Elderly with symptoms of scalp or temporal tenderness or jaw claudication are at risk for third nerve palsy due to giant cell arteritis.

RATIONALE FOR TREATMENT

Diplopia, loss of binocular vision, compensatory head position, and reconstruction of alignment all warrant treatment consideration.

CARE PROCESS

PATIENT OUTCOME CRITERIA

Treatment in adult strabismus is symptom directed, and targeted outcomes may include:

- Reconstruction of ocular alignment with improved eye contact and self-image
- Improvement of binocular vision
- Reduction of diplopia
- Reduction of torticollis

DIAGNOSIS

The third nerve follows a course from its origination in the midbrain to the orbit.²⁹⁵ The third-nerve nucleus lies near the midline of the midbrain. It is composed of four paired subnuclei and one unpaired subnucleus. The unpaired central caudal nucleus innervates both ipsilateral and contralateral elevator palpebral muscles. If complete third nerve palsy is accompanied by contralateral superior rectus weakness, the lesion is nuclear. Localization of the lesion by associated findings and symptoms is important in determining further workup, establishing an etiology, and directing treatment. Lesions involving the superior cerebellar peduncle cause ipsilateral cerebellar ataxia,²⁹⁶ lesions involving the red nucleus cause ipsilateral flapping hand tremor and ataxia,²⁹⁷ and lesions involving the cerebral peduncle cause ipsilateral hemiplegia or hemiparesis.

Within the subarachnoid space, the third nerves pass close to the tentorial edge and lateral to the posterior communicating artery. Aneurysms in this location cause a pupil-involving third nerve palsy, although the pupil may appear normal at presentation.^{249,298} The nerve passes along the tentorial edge and adjacent to the most medial aspect of the temporal lobe (the uncus). Mass lesions or intracranial bleeding can force the uncus through the tentorial notch, causing compression.²⁹⁹

The nerve then enters the cavernous sinus, and pathology there may be accompanied by sixth nerve and fourth nerve paralysis.³⁰⁰ Within the cavernous sinus the third nerve separates into superior and inferior divisions. Both enter into the orbit through the superior orbital fissure. The superior division innervates the superior rectus and the levator. The inferior division sends parasympathetic fibers into the ciliary ganglion, the pupillary sphincter, the ciliary (accommodation), the inferior oblique, the medial rectus, and inferior rectus. Divisional palsy typically localizes the lesion to the orbit. If the lesion involves the orbital apex or orbit, there may be associated optic neuropathy and proptosis.

History

A detailed medical and ocular history should include specific questions about patient symptoms, speed of onset of the strabismus, and possible associated unilateral or bilateral ptosis or other neurologic symptoms (such as ataxia, tremor, hemiplegia, sixth nerve or fourth nerve palsy, and noted pupillary asymmetry, and vision loss).

Examination

A comprehensive eye examination with particular attention to sensorimotor exam, evidence of ptosis and anisocoria, and pupillary responses in bright and dim illumination. It should also include a fundus examination to evaluate for the presence of papilledema or optic atrophy.

Evaluation of the third nerve palsy depends on the presumed location of the lesion and is based on other accompanying neurologic findings. Isolated third nerve palsy, however, is what most clinicians encounter. The important characteristics are whether the pupil is involved and the extent of the motility disorder and ptosis. A classic pupil-sparing third nerve palsy has normal pupillary function, complete ptosis, and complete (related) motility dysfunction. In this situation, the etiology is almost always secondary to microvascular disease with associated diabetes, hypertension, or hyperlipidemia.²⁹³ However, even if the pupil is unaffected, when there is partial extraocular muscle involvement or incomplete ptosis, one cannot be certain of a microvascular etiology; a compressive lesion, for example, might present this way. In this situation, it is recommended to proceed either with neuroimaging including an MRI with gadolinium and magnetic resonance angiography (MRA) or computed tomography angiography (CTA). In some instances of vasculopathic third nerve palsy, the pupil may be involved, although mildly.

Pupil-involving third nerve palsy is more concerning. A compressive lesion must be ruled out, urgently, especially an aneurysm involving the posterior communicating artery. Active force generation testing in the office may help identify muscles with residual function (which may be responsive to resection) vs. completely paretic muscles (where resection will not be effective and the muscle should be left intact to preserve ciliary circulation).³⁰¹ Neuroimaging, including MRA or CTA is recommended.³⁰² If there is a high suspicion of aneurysm despite a normal MRA or CTA, then a catheter angiogram should be considered after a brain MRI with and without contrast and specific attention to the third nerve is performed. Tumors, including meningioma, schwannoma, and metastatic lesions, are in the differential. Other causes include trauma, subarachnoid hemorrhage, viral illnesses, demyelinating disease, and leptomeningeal disorders.²⁹³ If the neuroimaging is normal, the next step would be serologic testing for infectious diseases (such as syphilis and Lyme), with consideration given to lumbar puncture that would include glucose, protein, cell count, and cytology and culture.

MANAGEMENT

Management of a third nerve palsy is directed towards the cause and then management of the diplopia.

Monitor/Observe

With complete ptosis, many patients are not troubled by diplopia until their lid is elevated.

Nonsurgical

If the patient experiences diplopia, chemodenervation (botulinum toxin) of an opposing extraocular muscle or the levator or use of occlusion can temporize while waiting for further recovery of function.³⁰³ Prisms, either press-on or ground-in, are often helpful, either while waiting for further recovery or treating residual diplopia (following partial recovery or following surgical correction). Despite all efforts to alleviate diplopia in the primary position, the incomitant nature of the deficit results in diplopia with minimal shift of gaze from the primary position. Many patients wear an eye patch or occlusive contact lens or MIN lens (Fresnel, Inc.) for times when the diplopia is most bothersome. A deficit of accommodation may cause difficulty reading. Uniocular progressive lenses or bifocals in younger patients can be prescribed to aid accommodation.

Surgical

Surgical management is complicated, and success often depends on the amount of residual deficit.³⁰⁴ A residual exotropia with ability to adduct past the midline typically responds well to recession of the lateral rectus muscle combined with resection of the medial rectus muscle (with or without adjustment), with or without vertical transposition.^{305,306} Likewise, in partial third nerve palsy, ipsilateral weakening of the superior oblique muscle, or its anterior intorting fibers might reduce the hypotropia and intorsion as a result of inferior oblique weakness. Recession with or without posterior fixation of muscles on the contralateral eye can also be used to expand the field of binocular single vision.

For complete paralysis, many other techniques have been tried with variable success.³⁰⁷ Some form of weakening procedure of the lateral rectus muscle is typically required, whether supramaximal recession, extirpation, or suturing to the periosteum of the lateral orbital rim.³⁰⁸ Sometimes this is combined with nasal transposition of the superior oblique muscle toward the medial rectus muscle insertion or maximal medial rectus resection for its tethering effect.^{309,310} Recently, nasal transposition of the split lateral rectus muscle to the medial rectus muscle insertion has been performed with some success.³¹¹

Post-operative prism correction may be required to allow for fusion in the primary or reading position. Ptosis surgery should be tempered if the Bell's response is extremely impaired, increasing the risk of exposure keratopathy. Patients treated surgically often have significant diplopia awareness outside of a region of binocular fusion and may benefit from part-time occlusion or a fogging contact lens for high-risk activities like driving a motor vehicle. Patients with concomitant injury to other structures in the brain or

brainstem may have central fusion disruption and be unable to fuse despite otherwise satisfactory post-operative alignment.

PROVIDER AND SETTING

Diagnosis and management of third nerve palsy requires the training, clinical judgment, and the experience of providers with expertise in neuro-ophthalmology and adult strabismus. Working under the supervision of an ophthalmologist, orthoptists can be an asset in the examination, diagnosis, and nonsurgical management of patients with third nerve palsy.

COUNSELING AND REFERRAL

The ophthalmologist should discuss the findings, explain the disorder, provide diagnosis, and discuss management options with the patient and any caregivers.

SECTION III. MYASTHENIA GRAVIS

INTRODUCTION

The term *myasthenia gravis* refers to a group of B-cell mediated autoimmune disorders that profoundly affect activity at the neuromuscular junction causing variable weakness exacerbated by fatigue.³¹² Although generalized myasthenia gravis affects large motor groups and sometimes includes ocular features, ocular myasthenia gravis affects only the levator, orbicularis oculi, and the extraocular muscles. It is known as the great masquerader because presentation can mimic many types of incomitant strabismus with or without ptosis.

DISEASE DEFINITION

Acetylcholine is released at the neuromuscular junction at the onset of an action potential and migrates across the synapse to reach the associated striated muscle. Acetylcholine receptor antibodies have been demonstrated in nearly all patients with generalized myasthenia and in 40% to 77% of patients with ocular myasthenia.

Twitch fibers in extraocular muscles are thought to be particularly susceptible to fatigue, and this characteristic as well as the fewer number of acetylcholine receptor antibodies in these muscles may be responsible for the common ocular manifestations.³¹³

PATIENT POPULATION

The patient population includes adults with myasthenia gravis without geographic or racial predilection, although this disorder occurs in children as well in the form of transient neonatal myasthenia (transplacental transmission), congenital myasthenia (not immune mediated), and juvenile autoimmune myasthenia. Patients are at risk for having or developing thymoma.

CLINICAL OBJECTIVES

- Recognize the disorder to initiate appropriate workup and referral to other subspecialties, including neurology
- Ensure proper medical and surgical treatment, and initiate short-term and subsequent long-term management of associated ptosis and strabismus

Thymectomy is indicated, certainly in the presence of thymoma, but also for specific age-based and immune-based characteristics for which thymectomy may substantially reduce clinical symptoms.³¹²

BACKGROUND

PREVALENCE

The incidence ranges from 0.04 to 5/100,000 per year, and prevalence estimates are 0.5 to 12.5/100,000 per year.³¹⁴

RISK FACTORS

There is increased risk for myasthenia gravis in the presence of autoimmune thyroid disease and thymoma.³¹⁵

NATURAL HISTORY

Onset in adults is usually in the third to fourth decade of life but sometimes much later in males. If the disorder is generalized, it may involve bulbar, limb, and respiratory muscles, which can lead to life threatening respiratory failure. Fifty percent of patients with myasthenia present with ocular symptoms only (typically ptosis and variable strabismus and diplopia), and of these 50% to 80% develop generalized systemic myasthenia within a few years.^{316,317}

RATIONALE FOR TREATMENT

Minimizing extraocular motility impairment, diplopia, and compensatory head position that can affect visual function, quality of life, and its socioeconomic consequences warrant treatment.

CARE PROCESS

PATIENT OUTCOME CRITERIA

Treatment is goal directed, and targeted outcomes may include:

- Recognition of disease and prevention of morbidity and mortality from generalized myasthenia gravis
- Reduction of diplopia (if present)
- Restoration of normal ocular alignment, appearance, and improved self-image
- Restoration of binocular function
- Reduction of compensatory head position (if present)

DIAGNOSIS

Variable incomitant strabismus may be accompanied by variable ptosis, both of which worsen with fatigue. Strabismus and associated diplopia may take on an entirely different pattern with fatigue or repetition of examination. Additionally, a period of rest or ice pack test in the physician's office may temporarily reduce or

eliminate both the extraocular motility disturbances and ptosis. Ptosis worsens with fatigue (prolonged upgaze) and may have associated Cogan lid-twitch sign. Ptosis of the contralateral eye may worsen upon manual elevation of the eye, with more severe ptosis due to Hering's law. Ocular saccades are often slow. Patients may also present with lid retraction as a result of associated TED.³¹⁸ Pupils are typically not affected but may in rare cases show impaired or slow responses.^{319,320}

History

Patients may present with a history of acquired variable strabismus, diplopia and ptosis. Those with antecedent generalized disease may have variable motor weakness, respiratory fatigue, difficulty with chewing, swallowing, holding up the head and slurred speech.

Examination

Complete sensorimotor examination and external examination is critical, with attention to the presence of strabismus, which changes over the course of prolonged examination, and variable ptosis with possible Cogan lid-twitch sign, and slow saccades. The Ice Test-application of an ice pack over the closed eyes for 2 minutes in the case of ptosis and for 5 minutes in the case of strabismus may demonstrate a reduction of ptosis of about 2 mm and a reduction of misalignment. This phenomenon, thought to relate to diminished anticholinesterase activity, is highly specific to this disorder.^{321,322} A rest test without an ice pack can also be used to aid in diagnosis.³²³

Tensilon (edrophonium) testing may be considered but is best performed by a practitioner experienced with proper intravenous administration, because associated muscarinic activity (excess tearing, salivation, sweating, abdominal cramping, bradycardia, bronchospasm hypotension, and syncope) can occur. The test should be performed in a monitored setting and atropine available for potential administration. It is 95% sensitive for generalized myasthenia and 86% sensitive in cases of ocular myasthenia.³²⁴

The presence of antiacetylcholine receptor antibody (AChR-Ab-binding, blocking, or modulating) can confirm the diagnosis; however, about 20% of patients with generalized myasthenia and about half of those with ocular myasthenia are seronegative. About one-third of these seronegative patients will be seropositive for muscle-specific kinase (anti MuSKAb), and lipoprotein-related protein 4 (LRP4) has been associated with generalized and ocular myasthenia gravis as well.³²⁵

Repetitive nerve stimulation testing (positive in only one-third of patients with ocular myasthenia) and the far more sensitive single fiber electromyography (positive in over 90% of patients with ocular myasthenia) may also assist in diagnosis.³²⁶ In many centers, single fiber EMG is considered the gold standard for diagnosis.

MANAGEMENT

Pyridostigmine bromide administered orally two to four times a day is the first-line treatment for myasthenia gravis, but about half of patients with strabismus-associated myasthenia show minimal response. In contrast, about 66% to 85% of patients show a positive response to corticosteroids.³²⁷ For some patients, various forms of immunosuppressive therapy with azathioprine, known to be effective, and other agents under current investigation may be offered by treating neurologists. Thymectomy is indicated in some cases, always in the presence of thymoma, and may substantially reduce symptoms for certain subpopulations with myasthenia gravis.³¹²

Diplopia and strabismus are highly variable and not readily remedied with prism. Remission or stabilization of the disease is often possible after 2 to 3 years of treatment,³²⁸ and at that point surgical intervention for strabismus may be considered if desired or if prism use is insufficient. Particular care is indicated in the use of anesthetic agents given any evidence of associated weakness of the respiratory muscles. Surgical management, with and without the use of adjustable sutures, has met with modest success in cases where there is a stabilized primary deviation, sometimes exacerbated by fatigue.³²⁹⁻³³⁴ More than one procedure may prove necessary.

PROVIDER AND SETTING

Diagnosis and management of myasthenia gravis requires the training and clinical judgment of an experienced ophthalmologist typically working in concert with a treating neurologist.

COUNSELING AND REFERRAL

Counseling and referral to a neurologist or neuro-ophthalmologist, and sometimes a general surgeon, is often indicated in the management of myasthenia. The ophthalmologist should discuss the findings, explain the disorder, provide a diagnosis, and discuss management options with the patient and any caregivers and be aware of any comorbidities such as respiratory distress that might present with generalization of the disease.

SECTION II m. FIXATION SWITCH DIPLOPIA

INTRODUCTION

DISEASE DEFINITION

In patients with childhood strabismus who have a suppression scotoma in their nondominant eye, fixation switch diplopia may occur because of a change in ocular fixation preference.³³⁵ Prior to their change in eye fixation preference, such patients do not perceive diplopia as the result of a suppression scotoma that was formed during childhood in the previously nondominant eye. However, when visual acuity in the previously dominant eye declines, fixation preference may switch to the previously nondominant eye. The previously dominant eye does not have a suppression scotoma, so for the first time, patients with “childhood” strabismus may experience double vision.

The largest study of fixation switch diplopia included 16 patients with a history of childhood strabismus who later presented with diplopia.³³⁶ The most common underlying etiologies were the use of monovision for the treatment of presbyopia in 38%, the development of myopia in the previously preferred eye in 25%, and incorrect refractive correction in 38% of patients. A trial of monovision with contact lenses is prudent prior to corneal or lenticular refractive surgery to determine whether surgically induced monovision will result in new-onset diplopia. Other published rare causes of fixation switch diplopia include a corneal ulcer and resultant scar in the dominant eye of a patient with monofixation syndrome and amblyopia³³⁷ and retinal detachment in the dominant eye of patients with strabismus and amblyopia.³³⁵

PATIENT POPULATION

The patient population includes adults with fixation switch diplopia.

CLINICAL OBJECTIVES

- Counsel the patient on the diagnosis and treatment options
- Manage diplopia
- Inform the patient’s other health care providers of the diagnosis and treatment plan

BACKGROUND

PREVALENCE AND RISK FACTORS

Prevalence and incidence are unknown. Risk factors include any ophthalmic disorder or intervention that switches fixation to the previously nondominant eye in a patient with latent or manifest strabismus.

NATURAL HISTORY

Fixation switch diplopia is a subacute complaint of new onset diplopia after any ophthalmic disorder or intervention that switches fixation to the previously nondominant eye in a patient with latent or manifest strabismus.

RATIONALE FOR TREATMENT

Diplopia warrants treatment.

CARE PROCESS

PATIENT OUTCOME CRITERIA

- Reduction or elimination of symptomatic diplopia

DIAGNOSIS

Fixation switch diplopia is the development of new-onset diplopia when fixation preference has shifted to the previously nondominant eye.

History

A detailed medical history includes information on past ocular conditions and ocular fixation preference. Careful documentation of symptoms experienced when fixating with the previously preferred eye, and when fixing with the newly preferred eye, can confirm the diagnosis. A positive family history of strabismus is common.³³⁸ Kushner and Kowal³³⁹ recommend a minimal screening procedure consisting of obtaining a history of childhood eye disease or treatments (such as patching or eye muscle surgery), checking spectacles for prism, cycloplegic refraction, and cover testing for all patients undergoing corneal or lenticular refractive surgery, especially for those planning to induce monovision.

Common scenarios in which fixation switch diplopia occurs include:

- Monovision has been induced by optical means or by refractive surgery
- Myopia with axial elongation has developed in a previously dominant eye
- Following refractive surgery, if the outcome favors fixation with the previously nondominant eye
- An unbalanced refraction has been used that encourages fixation with the nondominant eye
- Following cataract surgery in a previously nondominant eye when the surgery results in better visual acuity of the nondominant eye compared with the dominant eye³³⁶

- Following asymmetric vision loss from other common diseases such as macular degeneration or diabetic retinopathy when the nondominant eye is left with better acuity

Examination

Comprehensive eye examinations of adult strabismus patients need to include:

- Detailed sensorimotor evaluation
- Assessment of refractive status
- Dilated fundus examination

Enabling fixation with the previously dominant eye can be done to confirm a history of monofixation and suppression before the change in ocular fixation preference occurred.

MANAGEMENT

Monitor/Observe

The patient should be monitored/observed if symptoms are mild or occasional or if the patient is opposed to treatment.

Nonsurgical

An attempt can be made to “switch” fixation back to the dominant eye, by pursuing refractive correction.

Patients will gradually experience less diplopia if dominance is re-established in the previously dominant eye. In cases where the fixation cannot be switched back due to permanent and untreatable vision loss, vision in the newly dominant eye should be optimized with refractive correction and the use of prisms.

Rarely, fixation switch diplopia cannot be alleviated, and in those cases occlusion must be contemplated as a last resort.

Surgical

In cases where the fixation cannot be switched back because of permanent and untreatable vision loss, strabismus surgery may be an option if there is a significant angle of misalignment and a demonstrated ability to relieve diplopia with prism correction by establishing a different alignment at which the patient can suppress.

PROVIDER AND SETTING

Fixation switch diplopia should be managed by an ophthalmologist with expertise in the diagnosis of longstanding childhood strabismus and abnormalities of binocular function. Working under the supervision of an ophthalmologist, orthoptists can be an asset in the examination, diagnosis, and nonsurgical management of fixation switch diplopia.

COUNSELING AND REFERRAL

Patients should be advised that they have an excellent prognosis if fixation can be switched back to the dominant eye. They should be counseled to avoid any procedures or refractive corrections that result in a switch of fixation to their nondominant eye. The ophthalmologist should discuss the findings, explain the disorder, provide diagnosis, and discuss management options with the patient and any caregivers.

SECTION II.n. RETINAL MISREGISTRATION

(BINOCULAR RETINAL DIPLOPIA)

INTRODUCTION

DISEASE DEFINITION

Retinal disease that causes distortion or displacement of the fovea in one or both eyes—such as subretinal or epiretinal membranes or after retinal detachment involving the macula—can cause binocular diplopia. In these cases, binocular retinal misregistration (often manifesting as metamorphopsia, micropsia or macropsia, or foveal ectopia) renders the foveal images in the two eyes too dissimilar to fuse.^{340,341} When binocular retinal misregistration results in diplopia, central and peripheral fusion are in conflict, described as central-peripheral rivalry.^{342,343} In this situation, most often the stronger peripheral contribution to motor fusion brings the peripheral retinas into alignment and leaves the fovea of each eye misaligned.

PATIENT POPULATION

The patient population includes adults with binocular retinal diplopia.

CLINICAL OBJECTIVES

- Counsel the patient on the diagnosis and treatment options
- Manage diplopia
- Inform the patient's other health care providers of the diagnosis and treatment plan

BACKGROUND

PREVALENCE AND RISK FACTORS

The prevalence of subretinal neovascular membranes and macular epiretinal membranes is 2% for individuals under 60 years of age and increases to as much as 12% for those over 70.^{344,345} Between 16% and 37% of those diagnosed with epiretinal membrane or other maculopathy have binocular retinal diplopia.^{343,346} With aging of the population, it is likely that retinal disease will be an increasingly important cause of diplopia.

NATURAL HISTORY

Within days to weeks of development of maculopathy or foveal abnormality, binocular retinal diplopia may develop, and this only rarely improves over time.

RATIONALE FOR TREATMENT

Diplopia warrants treatment.

CARE PROCESS

PATIENT OUTCOME CRITERIA

Treatment for binocular retinal diplopia includes diminishing diplopia.

DIAGNOSIS

Binocular diplopia develops within days to weeks of worsening maculopathy or foveal abnormality because the foveal image in the two eyes becomes too dissimilar to fuse.

History

A detailed medical history should include information on ocular conditions and specifically retinal disease involving the macula.

Examination

An examination should include any history of retinal disease affecting the macula of one or both eyes. A full orthoptic examination is warranted because a proportion of patients who have maculopathy and diplopia have other forms of treatable strabismus.³⁴⁷ Prism alternate cover testing demonstrates either no strabismus or a small vertical deviation. Any diplopia relief from prism correction is most often transient, although in rare patients it may be helpful. Metamorphopsia may be identified on the Amsler grid test and quantified using M-Charts, and aniseikonia (unequal images) can be documented and quantified using the Awaya test. (See Glossary)

For dragged-fovea diplopia syndrome, the lights on/off test is pathognomonic. In this test, a small white-on-black test letter is shown and, when peripheral fusion cues are eliminated by darkening the room, central fusion allows the test letter to be seen singly. When the room lights are turned on, peripheral fusion reasserts itself, the images of the test letter separate and diplopia resumes.³⁴³ This test is not effective unless the entire room is darkened with no cues to peripheral fusion such as door frames or background lighting on a computer monitor. An alternative to the lights-on lights-off test for those who are unable to eliminate all peripheral cues in their examination rooms is the optotype-frame test.³⁴⁷ (See Glossary) For the optotype-frame test, the patient is requested to fixate an isolated (uncrowded) Snellen optotype on an illuminated

monitor and to describe whether the letter itself is single or double. Assuming it is single, the patient is asked whether the frame of the monitor is single or double. If maintaining a single frame causes diplopia of the letter, peripheral fusion has taken over and foveal diplopia syndrome is present. Stronger peripheral fusion makes it impossible to maintain central single binocular vision when foveal image disparity has become too great.

MANAGEMENT

Monitor/Observe

The patient should be monitored/observed if symptoms are mild or occasional or if the patient is opposed to treatment.

Nonsurgical

Although cover testing in patients with binocular retinal diplopia often demonstrates small-angle strabismus that is nearly always vertical, prismatic or surgical correction of this deviation is not curative because it does not resolve the mismatch of distorted macular images or the conflict between foveal and peripheral alignment. Even so, intervention can sometimes reduce symptoms. Reduced diplopia awareness has been reported with the use of prism correction or fogging in some patients.³⁴⁸ Fogging the vision in one eye, which eliminates the foveal conflict by producing a central scotoma,³⁴⁹ has been the most successful. Blenderm™ surgical tape applied to the spectacle lens has been used,³ but Scotch Satin™ tape³⁴³ or Bangerter foils³⁴⁹ are generally better tolerated, or use of an occlusive contact lenses. A small amount of prism in addition to a Bangerter foil can provide better relief from diplopia in some difficult cases.³⁵⁰

Surgical

If superimposition of the foveal images by synoptophore or prism does not satisfactorily resolve or diminish subjective diplopia, strabismus surgery is unlikely to be successful. It may be considered if improved binocular alignment reduces symptoms incompletely addressed by fogging or optical correction alone, or if superimposition of the foveal images by synoptophore diminishes subjective diplopia. It is important to remember that some patients with retinal misregistration have treatable causes of diplopia as well³⁴⁷. There is emerging evidence that peeling of the epiretinal membrane may be effective in addressing binocular retinal diplopia in a proportion of patients,³⁴⁸ but retinal surgery for epiretinal membrane appears to be a double-edged sword because some nondiplopic patients become diplopic following this retinal procedure.³⁵¹

PROVIDER AND SETTING

A complaint of diplopia normally prompts referral to a pediatric ophthalmologist, orthoptist or neuro-ophthalmologist, many of whom are familiar with the diagnosis and management of this perplexing problem.

COUNSELING AND REFERRAL

Patients with binocular retinal diplopia are generally already under the care of a retina specialist, from whom they are typically referred. While the underlying retinal disease often needs ongoing care, surgical treatment such as membrane peeling improves diplopia only in a proportion of patients. The strabismus specialist may need to discuss the potential benefits of membrane peeling with the retina specialists. The potential value of prism improved refractive correction and strabismus surgery to reduce diplopia awareness in some cases should not be overlooked. The patient should be counseled, however, that this condition usually does not improve spontaneously, and fogging of one eye may be the most suitable long-term solution. The ophthalmologist should discuss the findings, explain the diagnosis, and discuss management options with the patient and any caregivers.

SECTION III. COMPLICATIONS OF PERFORMING ADULT STRABISMUS SURGERY

INTRODUCTION

Although complications can occur as a result of any surgical procedure, the risk of sight-threatening complications is particularly low with strabismus surgery.^{27,352,353} The more common complications are minor, often self-limited, or treated with topical medications. More serious complications are fortunately rare.

BACKGROUND

PREVALENCE AND RISK FACTORS

Severe complications from strabismus surgery have been estimated to be 1 in 400 (globe perforation, severe infection, slipped or lost muscle and scleritis), with 1 in 2,400 resulting in a poor or very poor outcome.³⁵³

CARE PROCESS

POSTOPERATIVE CONCERNS

The following postoperative concerns are common to adults as well as children after strabismus surgery. Postoperative concerns with a higher incidence in the adult population are indicated.

Mild Concerns

These are best treated with observation or a short course of common supportive therapy and include:³⁵⁴

- Foreign body sensation
- Corneal abrasion
- Allergic reaction
- Delle (2.2%–18.9%, higher risk in reoperations and transpositions)^{355,356}
- Subconjunctival hemorrhage
- Chemosis
- Mydriasis
- Reduced accommodation
- Conjunctival scar
- Visible muscle insertion
- Thin visible/dark sclera

- Persistent injection over the surgical site
- Postoperative nausea
- Pyogenic granuloma (2.1%)³⁵⁷
- Tenon's prolapse
- Epithelial inclusion cyst (0.25%)³⁵⁸
- Advancing plica semilunaris
- Significant conjunctival scar

Persistent Tenon's prolapse, pyogenic granuloma, epithelial inclusion cyst, advancing plica semilunaris, and conjunctival scar are sometimes addressed with minor surgical intervention.

Moderate Concerns

Ocular Misalignment

- Overcorrection or undercorrection (possibly treated with additional strabismus surgery)
- Limitation of eye ductions (possibly treated with additional strabismus surgery)
- Loss of binocular function (may benefit from additional strabismus surgery, orthoptic intervention, or use of a prism)

Globe/Eyelid/Systemic Concerns

- Globe perforation (0.08%–5.1%; although serious, most cases have no sequelae but place patient at higher risk for retinal detachment, vitreous hemorrhage, and endophthalmitis).^{353,359-362} Some cases are observed, others are treated with retinopexy.
- Altered eyelid position, common with surgery on the inferior or superior rectus muscles and more notable in patients with thyroid ophthalmopathy (who already may have eyelid retraction). If persistent or of concern, may be addressed with eyelid surgery.
- Oculocardiac reflex (67.9%) or asystole (0.11%) (both usually brief and of no consequence).^{363,364}

Major Concerns

Rare, but very serious complications include:

- Endophthalmitis (1 in 30,000–1 in 185,000)^{359,365}
- Subconjunctival abscess, preseptal/orbital cellulitis (1 in 1,100–1 in 1,900)^{353,365,366}
- Surgically induced necrotizing scleritis (1 in 4,000; more likely in adults)³⁵³
- Slipped muscle (1 in 1,500)³⁵³
- Lost muscle (1 in 4,500; more likely in adults)³⁵³
- Pulled-in-two syndrome (1 in 14,000; more likely in adults)³⁵²
- Retinal detachment (1 in 10,000–1 in 40,000)^{359,367}

- Adhesive syndrome (fat adherence syndrome)³⁶⁸
- Anterior segment ischemia (1 in 6,000; higher risk with age, vascular risk factors, and operating on three or more muscles)³⁵⁷
- Diplopia, rarely intractable (0.8%; more likely in adults)¹⁰
- Postoperative orbital hemorrhage (incidence unknown, exceedingly rare, potentially greater risk for patients on anticoagulation)^{369,370}
- Operating on the wrong eye or muscle (1 in 2,506)³⁷¹

PROVIDER AND SETTING

Diagnosis and management of complications from adult strabismus surgery requires the training, clinical judgment, and experience of a pediatric ophthalmologist or strabismologist.

COUNSELING AND REFERRAL

The ophthalmologist should discuss and explain the findings and discuss management options with the patient. In some cases, treatment may be best managed with the additional expertise of other ophthalmic colleagues with advanced retina, oculoplastics, or immunology expertise, as indicated.

SECTION IV. TECHNICAL CONSIDERATIONS OF PERFORMING ADULT STRABISMUS SURGERY

INTRODUCTION

Strabismus surgery in adults is often more challenging than in children for a variety of reasons. A well thought out surgical plan with preparation for the unexpected is important. Attention should be given to the following special considerations.

CARE PROCESS

SURGICAL PLANNING AND MANAGEMENT

Anticoagulants

Many strabismus surgeons do not routinely stop anticoagulants for strabismus surgery. Temporary discontinuation of anticoagulation medication may reduce intraoperative bleeding, but consultation with the physician prescribing anticoagulation is advised. Reasons for anticoagulation differ and, in some cases, bridging therapy is indicated. Anticoagulation should be restarted immediately or shortly after the procedure.³⁷² It is possible to perform strabismus surgery on patients who are on anticoagulants.³⁷³

Absorbable gelatin sponges with or without thrombin may also be useful in difficult cases but are rarely required for more routine procedures.

Adjustable Sutures

Adjustable sutures are often used by strabismus surgeons, particularly for adult patients, although many surgeons achieve excellent results without the use of adjustable sutures. Advocates for adjustable sutures point to several advantages over fixed sutures, including a second chance at obtaining satisfactory alignment, and the potential to minimize risk of post-operative diplopia. A variety of techniques (bowtie, noose, semiadjustable) exist, and the timing of the adjustment varies with surgeon preference, ranging from immediately in the operation room, several hours after the surgery, and to up to several days following the procedure. This technique may be most helpful in reoperations and unpredictable cases, such as those with restrictive or paralytic strabismus.^{150,154,200,257,311,374,375}

Microtropias

Surgeons will frequently encounter microtropias in adults. Small deviations (<8 prism diopters horizontally and <3 prism diopters vertically) may prove clinically significant causing diplopia or asthenopia. Small horizontal or vertical deviations may be successfully treated using a tenotomy procedure (partial, central snip) to obviate the need for prism correction.^{376 377}

Chemodenervation

At present, intramuscular injection of botulinum toxin into an extraocular muscle may be used alone or in combination with strabismus surgery to treat new onset deviations, to enhance the impact of traditional surgery on large deviations, to address a residual deviation after prior strabismus surgery, and to treat small-angle deviations.^{61,76,139,303,378} Botulinum toxin can also be used to prevent contracture of an ipsilateral antagonist muscle in cases of paralytic strabismus while waiting the requisite period of time for spontaneous resolution before recommending strabismus surgery. A Cochrane Systematic Review found that it was difficult to assess outcomes given the limited number of RCTs.³⁷⁸

Anesthesia

Retrobulbar or peribulbar anesthesia and monitored sedation or pure topical anesthesia are possibilities in adults having unilateral surgery, though general anesthesia may be preferable in the case of reoperation, and complex, bilateral, and longer procedures.

Complex Strabismus

A higher percentage of adults have complex strabismus as a result of scarring from previous strabismus surgery, restriction from orbital trauma, or restriction from other ocular surgeries including glaucoma seton or scleral buckle surgery, the placement of orbital wall implants after trauma, blepharoplasty, dacryocystorhinostomy, pterygium excision or sinus surgery as well as myotoxicity from local anesthesia.²⁰¹ (Many of these concerns are addressed in Section IIg. Strabismus Associated with Other Ophthalmic Surgery.) Scleromalacia may increase the complexity of both surgery and postoperative recovery.

A “stretched scar” (weak attachment between muscle and globe) is a common occurrence in adults who have undergone horizontal rectus muscle surgery in childhood. Suggestive clinical findings include increased deviation in the field of action of the previously operated muscle. It is important to distinguish weak, non-muscular attachments from more robust muscle tissue intraoperatively, as placement of sutures in this non-muscular tissue will lead to early recurrence of the strabismus and further loss of muscle force. Slipped or tenuously attached muscle (which sometimes appears like a stretched scar), and lost muscles are more common in adults and make surgical outcomes less predictable.³⁷⁹ They should be approached with

great care. A meticulous technique is often required to ensure a successful outcome. An experienced assistant can be very helpful. Sometimes a slipped or lost muscle is readily retrieved by tracing its natural path or by taking advantage of fine attachments, if not yet severed, to adjacent extraocular muscles. For example, a slipped inferior rectus muscle may still retain its attachments to the adjacent inferior oblique muscle. If the lost muscle cannot be found, waiting a month until likely adhesion to the globe may facilitate recovery of the previously lost segment, as the muscle can now be hooked. High-resolution orbital imaging may facilitate surgical planning. If this proves technically impossible, a transposition procedure may be considered to replace missing function.^{352,353,380,381}

Intraoperative Issues

The surgeon should also pay careful attention to specific intraoperative issues that are far more common in adults. A second strabismus surgeon or skilled assistant may be needed and ample time allotted. Conjunctiva and Tenon's are frail in the older population. Thin and delicate conjunctiva may make wound closure difficult. Amniotic membrane grafts may sometimes be used in extreme cases. Likewise, careful technique is necessary to prevent pulled-in-two syndrome, in which the muscle belly is torn in two fragments from too vigorous traction on weakened extraocular muscles.¹⁴⁶

Retrobulbar, intramuscular, and intraocular hemorrhage may occur in adult strabismus surgery as a result of the surgery or periorbital anesthesia.^{369,370,382} Although rare, they are potentially vision-threatening complications, and the surgeon should be knowledgeable in their management.

Whereas children will have formed vitreous, liquefied vitreous is common in adults. Consequently, adults have higher risk for retinal detachment following inadvertent scleral perforation of the needle. Various techniques such as short scleral passes may reduce this risk.

PROVIDER AND SETTING

Diagnosis and management of adult strabismus requires the training, clinical judgment, and experience of a pediatric ophthalmologist or strabismologist.

COUNSELING AND REFERRAL

The ophthalmologist should discuss the findings, explain the disorder, provide diagnosis, and discuss management options with the patient and any caregivers.

APPENDIX 1.

Glossary

Awaya Test: A test of aniseikonia that has the patient compare adjacent calibrated halfmoons—one red and one green—to determine the degree of difference in image size and appearance. The images can be presented in any meridian enabling quantification of vertical, horizontal, and oblique aniseikonia.

Bagolini Lenses: Striated lenses used to test for suppression, and normal or abnormal retinal correspondence.

Kushner Semi-Adjustable Technique: A modification of the adjustable suture technique that limits undesired excess recession over time by allowing only a modest degree of secondary adjustment to an otherwise fixed recession. (See reference.¹⁵⁰)

Loop Myopexy: A strabismus surgical procedure wherein suture (typically nonabsorbable) is used to create an adhesion between two adjacent muscles without additional adhesion to sclera. Examples of common use of the loop myopexy technique include loop myopexy between the superior and lateral recti to treat myopic strabismus fixus, and between the superior or inferior rectus muscles and the lateral rectus muscle to improve abduction in the treatment of 6th nerve palsy or Duane syndrome.

SR-LR (Superior Rectus-Lateral Rectus) Band: This band maintains a soft tissue connection between the superior rectus and the lateral rectus muscles as they course posteriorly. Age or staphylomatous growth of the globe can result in a medial shift of the superior rectus and an inferior shift of the lateral rectus as this band of connective tissue fails.

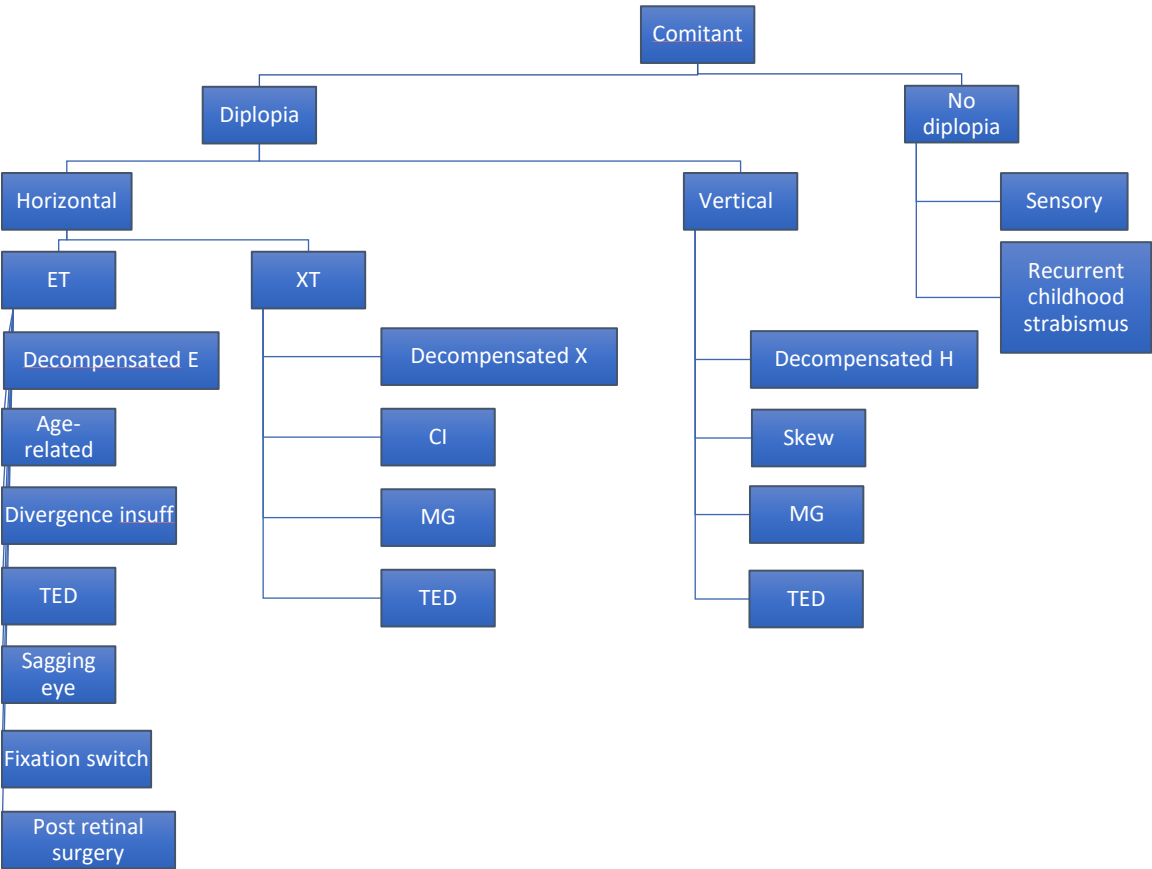
Optotype Frame Test: This is a test of central versus peripheral fusion. The patient is requested to fixate an isolated (uncrowded) Snellen optotype on an illuminated monitor and to describe whether the letter itself is single or double. Assuming it is single, the patient is asked whether the frame of the monitor is single or double. If maintaining a single frame causes diplopia of the letter, peripheral fusion has taken over and foveal diplopia syndrome is present. This is a disorder wherein stronger peripheral fusion makes it impossible to maintain single binocular vision centrally and occurs when foveal image disparity is sufficient to disrupt central fusion.

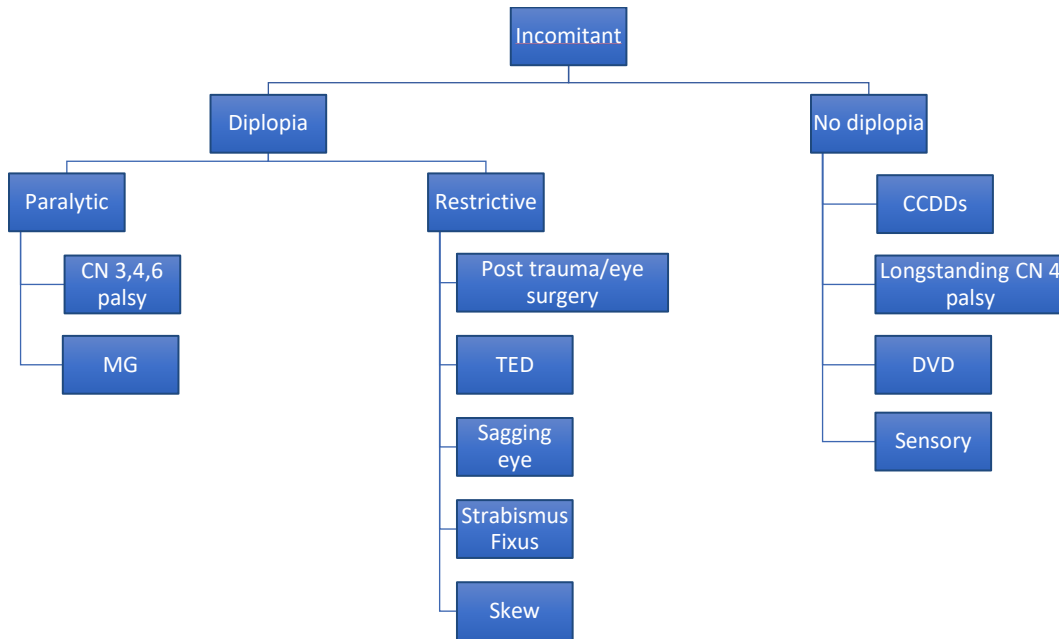
Sagging Eye Syndrome: Some cases of divergence insufficiency may be seen in association with an age-related degeneration of the superior rectus–lateral rectus (SR-LR) connective tissue band. The strabismus is often accompanied by mild ptosis (or a history of treated ptosis) and deep superior lid sulcus defect associated with aging. Divergence insufficiency is common and sometimes there is associated, modest, vertical misalignment of the eyes.

Synoptophore: An instrument that measures the manifest strabismus angle in all planes and allows stimuli to be presented to both eyes at once. The misalignment can be “fixed” by the device and the ability of the patient to fuse the superimposed images can be tested. This device can also be used for orthoptic training, exercising fusional vergences and for predicting whether strabismus surgery may result in binocular fusion.

APPENDIX 2

Algorithm for approaching adult strabismus based on presentation of deviation





APPENDIX 3.

LITERATURE SEARCHES FOR THIS PPP

Literature searches of the PubMed and Cochrane databases were conducted in February 2017; the search strategies were as follows. Specific limited update searches were conducted after June 2019.

"divergence insufficiency" OR "divergence insufficiency esotropia" OR "divergence insufficiency pattern" OR "divergence insufficiency pattern esotropia" OR "divergence insufficiency"
 (convergence[tw] and insufficiency[tw]) OR (("convergence insufficiency" OR "convergence insufficiency and excess" OR "convergence insufficiency and reading study cirs group" OR "convergence insufficiency symptom" OR "convergence insufficiency symptom survey" OR "convergence insufficiency symptom ciss" OR "convergence insufficiency symptom survey questionnaire" OR "convergence insufficiency symptom survey score" OR "convergence insufficiency symptoms" OR "convergence insufficiency treatment" OR "convergence insufficiency treatment trial" OR "convergence insufficiency treatment trial cirt investigator group" OR "convergence insufficiency treatment trial cirt study group" OR "convergence insufficiency treatment trial executive committee" OR "convergence insufficiency treatment trial group" OR "convergence insufficiency treatment trial study group" OR "convergence insufficiency type" OR "convergence insufficiency type intermittent exotropia"))
 (superior oblique palsy) OR (("fourth nerve"[tw] OR "trochlear"[tw] OR "fourth cranial nerve"[tw] OR "cranial nerve iv"[tw])) AND palsy[tw]) OR ("superior oblique palsy"[tw] OR "superior oblique paralysis"[tw] OR "fourth nerve palsy"[tw] OR "fourth nerve paralysis"[tw] OR "trochlear palsy"[tw] OR "trochlear paralysis"[tw] OR "cranial nerve iv palsy"[tw])

APPENDIX 4

RELATED ACADEMY MATERIALS

Basic and Clinical Science Course

External Disease and Cornea (Section 8, 2019–2020)

Focal Points 2018

Module: Adult Strabismus

Clinical Statements – Free download available at <http://one.aao.org/guidelines-browse?filter=clinicalstatement>.

Adult Strabismus Surgery - 2017

Preferred Practice Pattern® Guidelines – Free download available at www.aao.org/ppp.

Amblyopia (2017)

Esotropia and Exotropia (2017)

To order any of these products, except for the free materials, please contact the Academy's Customer Service at 866.561.8558 (U.S. only) or 415.561.8540 or www.aao.org/store.

Orge FH. Strabismus simulator. 2015; <https://www.aao.org/interactive-tool/strabismus-simulator>. Accessed August 13, 2019.

[Complex Strabismus Simulator](#)

Oct 24, 2018 by Faruk H. Orge, MD; K. David Epley, MD

This simulator expands on the basic **Strabismus** Simulator, allowing the exploration of more complex eye deviations such as the alphabet patterns, cranial nerve...

Interactive / Tool

REFERENCES

1. Bagolini B. Sensorial anomalies in strabismus. (suppression, anomalous correspondence, amblyopia). *Documenta ophthalmologica Advances in ophthalmology*. 1976;41(1):1-22.
2. Guyatt GH, Oxman AD, Vist GE, et al. GRADE: an emerging consensus on rating quality of evidence and strength of recommendations. *Bmj*. 2008;336(7650):924-926.
3. Buehl W, Sacu S, Schmidt-Erfurth U. Retinal vein occlusions. *Dev Ophthalmol*. 2010;46:54-72.
4. Kushner BJ. The benefits, risks, and efficacy of strabismus surgery in adults. *Optometry and vision science : official publication of the American Academy of Optometry*. 2014;91(5):e102-109.
5. Hertle RW. Clinical characteristics of surgically treated adult strabismus. *Journal of pediatric ophthalmology and strabismus*. 1998;35(3):138-145; quiz 167-138.
6. Nelson BA, Gunton KB, Lasker JN, Nelson LB, Drohan LA. The psychosocial aspects of strabismus in teenagers and adults and the impact of surgical correction. *Journal of AAPOS : the official publication of the American Association for Pediatric Ophthalmology and Strabismus*. 2008;12(1):72-76 e71.
7. Scott WE, Kutschke PJ, Lee WR. 20th annual Frank Costenbader Lecture--adult strabismus. *Journal of pediatric ophthalmology and strabismus*. 1995;32(6):348-352.
8. Mills MD, Coats DK, Donahue SP, Wheeler DT. Strabismus surgery for adults: a report by the American Academy of Ophthalmology. *Ophthalmology*. 2004;111(6):1255-1262.
9. Scott WE, Kutschke PJ, Lee WR. Diplopia in adult strabismus. *Am Orthoptic J*. 1994;44:66-69.
10. Kushner BJ. Intractable diplopia after strabismus surgery in adults. *Arch Ophthalmol*. 2002;120(11):1498-1504.
11. Chang YH, Melvin P, Dagi LR. Goal-determined metrics to assess outcomes of exotropia surgery. *Journal of AAPOS : the official publication of the American Association for Pediatric Ophthalmology and Strabismus*. 2015;19(4):304-310.
12. Ehrenberg M, Nihalani BR, Melvin P, Cain CE, Hunter DG, Dagi LR. Goal-determined metrics to assess outcomes of esotropia surgery. *Journal of AAPOS : the official publication of the American Association for Pediatric Ophthalmology and Strabismus*. 2014;18(3):211-216.
13. Repka MX, Lum F, Burugapalli B. Strabismus, Strabismus Surgery, and Reoperation Rate in the United States: Analysis from the IRIS Registry. *Ophthalmology*. 2018;125(10):1646-1653.
14. Birch EE, Fawcett S, Stager DR. Why does early surgical alignment improve stereoacuity outcomes in infantile esotropia? *J AAPOS*. 2000;4(1):10-14.
15. Fawcett S, Leffler J, Birch EE. Factors influencing stereoacuity in accommodative esotropia. *Journal of AAPOS : the official publication of the American Association for Pediatric Ophthalmology and Strabismus*. 2000;4(1):15-20.
16. Kushner BJ, Morton GV. Postoperative binocularity in adults with longstanding strabismus. *Ophthalmology*. 1992;99(3):316-319.
17. Morris RJ, Scott WE, Dickey CF. Fusion after surgical alignment of longstanding strabismus in adults. *Ophthalmology*. 1993;100(1):135-138.
18. Kushner BJ. Binocular field expansion in adults after surgery for esotropia. *Arch Ophthalmol*. 1994;112(5):639-643.

19. Pineles SL, Demer JL, Isenberg SJ, Birch EE, Velez FG. Improvement in binocular summation after strabismus surgery. *JAMA ophthalmology*. 2015;133(3):326-332.
20. Burke JP, Leach CM, Davis H. Psychosocial implications of strabismus surgery in adults. *Journal of pediatric ophthalmology and strabismus*. 1997;34(3):159-164.
21. Hatt SR, Leske DA, Kirgis PA, Bradley EA, Holmes JM. The effects of strabismus on quality of life in adults. *American journal of ophthalmology*. 2007;144(5):643-647.
22. Jackson S, Harrad RA, Morris M, Rumsey N. The psychosocial benefits of corrective surgery for adults with strabismus. *The British journal of ophthalmology*. 2006;90(7):883-888.
23. Kraft SP. Outcome criteria in strabismus surgery. *Canadian journal of ophthalmology Journal canadien d'ophtalmologie*. 1998;33(4):237-239.
24. Menon V, Saha J, Tandon R, Mehta M, Khokhar S. Study of the psychosocial aspects of strabismus. *Journal of pediatric ophthalmology and strabismus*. 2002;39(4):203-208.
25. Olitsky SE, Sudesh S, Graziano A, Hamblen J, Brooks SE, Shaha SH. The negative psychosocial impact of strabismus in adults. *Journal of AAPOS : the official publication of the American Association for Pediatric Ophthalmology and Strabismus*. 1999;3(4):209-211.
26. Satterfield D, Keltner JL, Morrison TL. Psychosocial aspects of strabismus study. *Arch Ophthalmol*. 1993;111(8):1100-1105.
27. Mills MD, Coats DK, Donahue SP, Wheeler DT, American Academy of O. Strabismus surgery for adults: a report by the American Academy of Ophthalmology. *Ophthalmology*. 2004;111(6):1255-1262.
28. Hatt SR, Leske DA, Liebermann L, Holmes JM. Comparing outcome criteria performance in adult strabismus surgery. *Ophthalmology* 2012;119(9):1930-1936.
29. Sullivan TJ, Kraft SP, Burack C, O'Reilly C. A functional scoring method for the field of binocular single vision. *Ophthalmology*. 1992;99(4):575-581.
30. Holmes JM, Leske DA, Kupersmith MJ. New methods for quantifying diplopia. *Ophthalmology*. 2005;112(11):2035-2039.
31. Kushner BJ. The usefulness of the cervical range of motion device in the ocular motility examination. *Archives of Ophthalmology*. 2000;118:946-950.
32. Holmes JM, Liebermann L, Hatt SR, Smith SJ, Leske DA. Quantifying diplopia with a questionnaire. *Ophthalmology*. 2013;120(7):1492-1496.
33. Coats DK, Paysse EA, Towler AJ, Dipboye RL. Impact of large angle horizontal strabismus on ability to obtain employment. *Ophthalmology*. 2000;107(2):402-405.
34. Goff MJ, Suhr AW, Ward JA, Croley JK, O'Hara MA. Effect of adult strabismus on ratings of official U.S. Army photographs. *Journal of AAPOS : the official publication of the American Association for Pediatric Ophthalmology and Strabismus*. 2006;10(5):400-403.
35. Hatt SR, Leske DA, Bradley EA, Cole SR, Holmes JM. Development of a quality-of-life questionnaire for adults with strabismus. *Ophthalmology*. 2009;116(1):139-144
36. Leske DA, Hatt SR, Liebermann L, Holmes JM. Evaluation of the Adult Strabismus-20 (AS-20) Questionnaire using Rasch analysis. *Investigative Ophthalmology & Visual Science*. 2012;53(6):2630-2639.
37. Dickmann A, Aliberti S, Rebecchi MT, et al. Improved sensory status and quality-of-life measures in adult patients after strabismus surgery. *Journal of AAPOS : the official*

- publication of the American Association for Pediatric Ophthalmology and Strabismus.* 2013;17(1):25-28.
38. Hatt SR, Leske DA, Holmes JM. Responsiveness of health-related quality of life questionnaires in adults undergoing strabismus surgery. *Ophthalmology.* 2010;117(12):2322-2328.
 39. Hatt SR, Leske DA, Liebermann L, Holmes JM. Changes in health-related quality of life 1 year following strabismus surgery. *American Journal of Ophthalmology.* 2012;153(4):614-619.
 40. Tandon AK, Velez FG, Isenberg SJ, Demer JL, Pineles SL. Binocular inhibition in strabismic patients is associated with diminished quality of life. *Journal of AAPOS : the official publication of the American Association for Pediatric Ophthalmology and Strabismus.* 2014;18(5):423-426.
 41. Liebermann L, Hatt SR, Leske DA, Holmes JM. Improvement in specific function-related quality-of-life concerns after strabismus surgery in nondiplopic adults. *Journal of AAPOS: American Association for Pediatric Ophthalmology & Strabismus.* 2014;18(2):105-109.
 42. Hatt SR, Leske DA, Liebermann L, Holmes JM. Incorporating health-related quality of life into the assessment of outcome following strabismus surgery. *American Journal of Ophthalmology.* 2016;164:1-5.
 43. Xu M, Yu H, Chen Y, Xu J, Zheng J, Yu X. Long-Term Quality of Life in Adult Patients with Strabismus after Corrective Surgery Compared to the General Population. *PloS one.* 2016;11(11):e0166418.
 44. Durnian JM, Owen ME, Marsh IB. The psychosocial aspects of strabismus: correlation between the AS-20 and DAS59 quality-of-life questionnaires. *Journal of AAPOS : the official publication of the American Association for Pediatric Ophthalmology and Strabismus.* 2009;13(5):477-480.
 45. McBain HB, MacKenzie KA, Au C, et al. Factors associated with quality of life and mood in adults with strabismus. *The British journal of ophthalmology.* 2014;98(4):550-555.
 46. Pineles SL, Repka MX, Yu F, Lum F, Coleman AL. Risk of musculoskeletal injuries, fractures, and falls in medicare beneficiaries with disorders of binocular vision. *JAMA ophthalmology.* 2015;133(1):60-65.
 47. Hatt SR, Leske DA, Liebermann L, Philbrick KL, Holmes JM. Depressive symptoms associated with poor health-related quality of life in adults with strabismus. *Ophthalmology.* 2014;121(10):2070-2071.
 48. Mohny BG, McKenzie JA, Capo JA, Nusz KJ, Mrazek D, Diehl NN. Mental illness in young adults who had strabismus as children. *Pediatrics.* 2008;122(5):1033-1038.
 49. McBain H, MacKenzie K, Hancox J, Ezra DG, Adams GG, Newman SP. What do patients with strabismus expect post surgery? The development and validation of a questionnaire. *The British journal of ophthalmology.* 2016;100(3):415-419.
 50. Convergence Insufficiency Treatment Trial Study Group. Randomized clinical trial of treatments for symptomatic convergence insufficiency in children. *Arch Ophthalmol.* 2008;126(10):1336-1349.
 51. Yurdakul NS, Ugurlu S. Analysis of risk factors for consecutive exotropia and review of the literature. *Journal of pediatric ophthalmology and strabismus.* 2013;50(5):268-273.

52. Han SY, Han J, Rhiu S, Lee JB, Han SH. Risk factors for consecutive exotropia after esotropia surgery. *Japanese journal of ophthalmology*. 2016;60(4):333-340.
53. Ganesh A, Pirouznia S, Ganguly SS, Fagerholm P, Lithander J. Consecutive exotropia after surgical treatment of childhood esotropia: a 40-year follow-up study. *Acta ophthalmologica*. 2011;89(7):691-695.
54. Hatt SR, Leske DA, Jung JH, Holmes JM. Intraoperative Findings in Consecutive Exotropia with and without Adduction Deficit. *Ophthalmology*. 2017;124(6):828-834.
55. Wikipedia. Bagolini Striated Glasses Test. 2019; https://en.wikipedia.org/wiki/Bagolini_Striated_Glasses_Test. Accessed August 19, 2019.
56. Kutschke PJ, Scott WE. Prism adaptation in visually mature patients with esotropia of childhood onset. *Ophthalmology*. 2004;111(1):177-179.
57. Orge FH. Strabismus stimulator. 2015; <https://www.aoa.org/interactive-tool/strabismus-simulator>. Accessed August 13, 2019.
58. Magrann I, Schlossman A. Strabismus in patients over the age of 60 years. *Journal of pediatric ophthalmology and strabismus*. 1991;28(1):28-31.
59. Havertape SA, Cruz OA, Chu FC. Sensory strabismus--eso or exo? *Journal of pediatric ophthalmology and strabismus*. 2001;38(6):327-330; quiz 354-325.
60. Von Noorden GK, Campos EC. Binocular vision and ocular motility : theory and management of strabismus. In: 6th ed. St. Louis, Mo.: Mosby; 2002:345-346.
61. Flanders M, Tischler A, Wise J, Williams F, Beneish R, Auger N. Injection of type A botulinum toxin into extraocular muscles for correction of strabismus. *Canadian journal of ophthalmology Journal canadien d'ophtalmologie*. 1987;22(4):212-217.
62. Helveston EM. Complications of strabismus surgery. *Transactions of the New Orleans Academy of Ophthalmology*. 1986;34:61-71.
63. Martinez-Thompson JM, Diehl NN, Holmes JM, Mohny BG. Incidence, types, and lifetime risk of adult-onset strabismus. *Ophthalmology*. 2014;121(4):877-882.
64. Rouse MW, Borsting E, Hyman L, et al. Frequency of convergence insufficiency among fifth and sixth graders. The Convergence Insufficiency and Reading Study (CIRS) group. *Optometry and vision science : official publication of the American Academy of Optometry*. 1999;76(9):643-649.
65. Storey EP, Master SR, Lockyer JE, Podolak OE, Grady MF, Master CL. Near Point of Convergence after Concussion in Children. *Optometry and vision science : official publication of the American Academy of Optometry*. 2017;94(1):96-100.
66. Kawata K, Rubin LH, Lee JH, et al. Association of Football Subconcussive Head Impacts With Ocular Near Point of Convergence. *JAMA ophthalmology*. 2016;134(7):763-769.
67. Biousse V, Skibell BC, Watts RL, Loupe DN, Drews-Botsch C, Newman NJ. Ophthalmologic features of Parkinson's disease. *Neurology*. 2004;62(2):177-180.
68. Gallaway M, Scheiman M, Mitchell GL. Vision Therapy for Post-Concussion Vision Disorders. *Optometry and vision science : official publication of the American Academy of Optometry*. 2017;94(1):68-73.
69. Holmes JM, Liebermann L, Hatt SR, Smith SJ, Leske DA. Quantifying diplopia with a questionnaire. *Ophthalmology*. 2013;120(7):1492-1496.
70. Pediatric Eye Disease Investigator G. Home-Based Therapy for Symptomatic Convergence Insufficiency in Children: A Randomized Clinical Trial. *Optometry and*

- vision science : official publication of the American Academy of Optometry.* 2016;93(12):1457-1465.
71. Scheiman M, Mitchell GL, Cotter S, et al. A randomized clinical trial of treatments for convergence insufficiency in children. *Arch Ophthalmol.* 2005;123(1):14-24.
 72. Scheiman M, Gwiazda J, Li T. Non-surgical interventions for convergence insufficiency. *The Cochrane database of systematic reviews.* 2011(3):CD006768.
 73. Teitelbaum B, Pang Y, Krall J. Effectiveness of base in prism for presbyopes with convergence insufficiency. *Optometry and vision science : official publication of the American Academy of Optometry.* 2009;86(2):153-156.
 74. Yang HK, Hwang JM. Surgical outcomes in convergence insufficiency-type exotropia. *Ophthalmology.* 2011;118(8):1512-1517.
 75. Kraft SP, Levin AV, Enzenauer RW. Unilateral surgery for exotropia with convergence weakness. *Journal of pediatric ophthalmology and strabismus.* 1995;32(3):183-187.
 76. Saunte JP, Holmes JM. Sustained improvement of reading symptoms following botulinum toxin A injection for convergence insufficiency. *Strabismus.* 2014;22(3):95-99.
 77. Farid MF, Abdelbaset EA. Surgical outcomes of three different surgical techniques for treatment of convergence insufficiency intermittent exotropia. *Eye (Lond).* 2017.
 78. Kirkeby L. Update on divergence insufficiency. *International ophthalmology clinics.* 2014;54(3):21-31.
 79. Jacobson DM. Divergence insufficiency revisited: natural history of idiopathic cases and neurologic associations. *Arch Ophthalmol.* 2000;118(9):1237-1241.
 80. Reche Sainz JA, Espinet Badia R, Puig Ganau T. Divergence insufficiency and demyelinating disorder. *European journal of ophthalmology.* 2002;12(3):238-240.
 81. Chaudhuri Z, Demer JL. Sagging eye syndrome: connective tissue involution as a cause of horizontal and vertical strabismus in older patients. *JAMA ophthalmology.* 2013;131(5):619-625.
 82. Demer JL. The Apt Lecture. Connective tissues reflect different mechanisms of strabismus over the life span. *Journal of AAPOS : the official publication of the American Association for Pediatric Ophthalmology and Strabismus.* 2014;18(4):309-315.
 83. Krzizok TH, Schroeder BU. Measurement of recti eye muscle paths by magnetic resonance imaging in highly myopic and normal subjects. *Investigative ophthalmology & visual science.* 1999;40(11):2554-2560.
 84. Aoki Y, Nishida Y, Hayashi O, et al. Magnetic resonance imaging measurements of extraocular muscle path shift and posterior eyeball prolapse from the muscle cone in acquired esotropia with high myopia. *American journal of ophthalmology.* 2003;136(3):482-489.
 85. Demer JL. Muscle paths matter in strabismus associated with axial high myopia. *American journal of ophthalmology.* 2010;149(2):184-186 e181.
 86. Tan RJ, Demer JL. Heavy eye syndrome versus sagging eye syndrome in high myopia. *Journal of AAPOS : the official publication of the American Association for Pediatric Ophthalmology and Strabismus.* 2015;19(6):500-506.
 87. Yamaguchi M, Yokoyama T, Shiraki K. Surgical procedure for correcting globe dislocation in highly myopic strabismus. *American journal of ophthalmology.* 2010;149(2):341-346 e342.

88. Chaudhuri Z, Demer JL. Long-term Surgical Outcomes in the Sagging Eye Syndrome. *Strabismus*. 2018;1-5.
89. Chaudhuri Z, Demer JL. Graded vertical rectus tenotomy for small-angle cyclovertical strabismus in sagging eye syndrome. *The British journal of ophthalmology*. 2016;100(5):648-651.
90. Nakao Y, Kimura T. Prevalence and anatomic mechanism of highly myopic strabismus among Japanese with severe myopia. *Japanese journal of ophthalmology*. 2014;58(2):218-224.
91. Rowe FJ, Noonan CP. Surgical treatment for progressive esotropia in the setting of high-axial myopia. *Journal of AAPOS : the official publication of the American Association for Pediatric Ophthalmology and Strabismus*. 2006;10(6):596-597.
92. Hayashi T, Iwashige H, Maruo T. Clinical features and surgery for acquired progressive esotropia associated with severe myopia. *Acta ophthalmologica Scandinavica*. 1999;77(1):66-71.
93. Haller T. Evaluation and Prism Management of Divergence Insufficiency Esotropia. *The American orthoptic journal*. 2015;65:40-43.
94. Daum KM. The course and effect of visual training on the vergence system. *American journal of optometry and physiological optics*. 1982;59(3):223-227.
95. Pineles SL. Divergence Insufficiency Esotropia: Surgical Treatment. *The American orthoptic journal*. 2015;65:35-39.
96. Chaudhuri Z, Demer JL. Medial rectus recession is as effective as lateral rectus resection in divergence paralysis esotropia. *Arch Ophthalmol*. 2012;130(10):1280-1284.
97. Bothun ED, Archer SM. Bilateral medial rectus muscle recession for divergence insufficiency pattern esotropia. *Journal of AAPOS : the official publication of the American Association for Pediatric Ophthalmology and Strabismus*. 2005;9(1):3-6.
98. Yadav S, Young J, Voas-Clarke C, Marsh IB, Durnian JM. Treatment of age-related distance esotropia with unilateral lateral rectus resection. *Journal of AAPOS : the official publication of the American Association for Pediatric Ophthalmology and Strabismus*. 2014;18(5):446-448.
99. Ranka MP, Steele MA. Esotropia associated with high myopia. *Current opinion in ophthalmology*. 2015;26(5):362-365.
100. Bagheri A, Adhami F, Repka MX. Bilateral recession-resection surgery for convergent strabismus fixus associated with high myopia. *Strabismus*. 2001;9(4):225-230.
101. Shenoy BH, Sachdeva V, Kekunnaya R. Silicone band loop myopexy in the treatment of myopic strabismus fixus: surgical outcome of a novel modification. *The British journal of ophthalmology*. 2015;99(1):36-40.
102. Farid MF, Elbarky AM, Saeed AM. Superior rectus and lateral rectus muscle union surgery in the treatment of myopic strabismus fixus: three sutures versus a single suture. *Journal of AAPOS : the official publication of the American Association for Pediatric Ophthalmology and Strabismus*. 2016;20(2):100-105.
103. Burch HB, Wartofsky L. Graves' ophthalmopathy: current concepts regarding pathogenesis and management. *Endocrine reviews*. 1993;14(6):747-793.
104. Bartley GB, Gorman CA. Diagnostic criteria for Graves' ophthalmopathy. *American journal of ophthalmology*. 1995;119(6):792-795.

105. Bartley GB, Fatourech V, Kadrmas EF, et al. The incidence of Graves' ophthalmopathy in Olmsted County, Minnesota. *American journal of ophthalmology*. 1995;120(4):511-517.
106. Wiersinga WM, Smit T, van der Gaag R, Mourits M, Koornneef L. Clinical presentation of Graves' ophthalmopathy. *Ophthalmic research*. 1989;21(2):73-82.
107. Dagi LR, Elliott AT, Roper-Hall G, Cruz OA. Thyroid eye disease: honing your skills to improve outcomes. *Journal of AAPOS : the official publication of the American Association for Pediatric Ophthalmology and Strabismus*. 2010;14(5):425-431.
108. Wu CY, Kahana A. Geriatric patients are predisposed to strabismus following thyroid-related orbital decompression surgery: A multivariate analysis. *Orbit*. 2017;36(2):95-101.
109. Perros P, Crombie AL, Matthews JN, Kendall-Taylor P. Age and gender influence the severity of thyroid-associated ophthalmopathy: a study of 101 patients attending a combined thyroid-eye clinic. *Clin Endocrinol (Oxf)*. 1993;38(4):367-372.
110. Stan MN, Bahn RS. Risk factors for development or deterioration of Graves' ophthalmopathy. *Thyroid : official journal of the American Thyroid Association*. 2010;20(7):777-783.
111. Bartalena L, Marcocci C, Tanda ML, et al. Cigarette smoking and treatment outcomes in Graves ophthalmopathy. *Annals of internal medicine*. 1998;129(8):632-635.
112. Del Monte MA. 2001 an ocular odyssey: lessons learned from 25 years of surgical treatment for graves eye disease. *The American orthoptic journal*. 2002;52:40-57.
113. Jang SY, Shin DY, Lee EJ, Lee SY, Yoon JS. Relevance of TSH-receptor antibody levels in predicting disease course in Graves' orbitopathy: comparison of the third-generation TBII assay and Mc4-TSI bioassay. *Eye (Lond)*. 2013;27(8):964-971.
114. Takakura A, Kirkeby K, Earle K, Silkiss RZ. Predicting the Development of Orbitopathy in Graves Thyroidopathy Patients: The Potential Role of TSI Testing. *Ophthalmic Plast Reconstr Surg*. 2015;31(5):369-372.
115. Cruz OA. Restricted motility for vertical strabismus in Graves' ophthalmopathy. *Ophthalmology*. 2001;108(2):242-243.
116. Farid M, Roch-Levecq AC, Levi L, Brody BL, Granet DB, Kikkawa DO. Psychological disturbance in graves ophthalmopathy. *Arch Ophthalmol*. 2005;123(4):491-496.
117. Barker L, Mackenzie K, Adams GG, Hancox J. Long-term Surgical Outcomes for Vertical Deviations in Thyroid Eye Disease. *Strabismus*. 2017;25(2):67-72.
118. Buckley EG. Restrictive Strabismus. In: Plager DA, ed. *Strabismus surgery: basic and advanced strategies*. Oxford: Oxford University Press; 2004:117-154.
119. Dagi LR, Zoumalan CI, Konrad H, Trokel SL, Kazim M. Correlation between extraocular muscle size and motility restriction in thyroid eye disease. *Ophthalmic Plast Reconstr Surg*. 2011;27(2):102-110.
120. Kerr NC. The role of thyroid eye disease and other factors in the overcorrection of hypotropia following unilateral adjustable suture recession of the inferior rectus (an American Ophthalmological Society thesis). *Transactions of the American Ophthalmological Society*. 2011;109:168-200.
121. Marcocci C, Kahaly GJ, Krassas GE, et al. Selenium and the course of mild Graves' orbitopathy. *The New England journal of medicine*. 2011;364(20):1920-1931.
122. Rotondo Dottore G, Leo M, Casini G, et al. Antioxidant Actions of Selenium in Orbital Fibroblasts: A Basis for the Effects of Selenium in Graves' Orbitopathy. *Thyroid : official journal of the American Thyroid Association*. 2017;27(2):271-278.

123. Leo M, Bartalena L, Rotondo Dottore G, et al. Effects of selenium on short-term control of hyperthyroidism due to Graves' disease treated with methimazole: results of a randomized clinical trial. *Journal of endocrinological investigation*. 2017;40(3):281-287.
124. Smith TJ, Kahaly GJ, Ezra DG, et al. Teprotumumab for Thyroid-Associated Ophthalmopathy. *The New England journal of medicine*. 2017;376(18):1748-1761.
125. Bartalena L, Baldeschi L, Boboridis K, et al. The 2016 European Thyroid Association/European Group on Graves' Orbitopathy Guidelines for the Management of Graves' Orbitopathy. *European thyroid journal*. 2016;5(1):9-26.
126. Nunery WR, Nunery CW, Martin RT, Truong TV, Osborn DR. The risk of diplopia following orbital floor and medial wall decompression in subtypes of ophthalmic Graves' disease. *Ophthalmic Plast Reconstr Surg*. 1997;13(3):153-160.
127. Leong SC, White PS. Outcomes following surgical decompression for dysthyroid orbitopathy (Graves' disease). *Current opinion in otolaryngology & head and neck surgery*. 2010;18(1):37-43.
128. Paridaens D, Hans K, van Buitenen S, Mourits MP. The incidence of diplopia following coronal and translid orbital decompression in Graves' orbitopathy. *Eye (Lond)*. 1998;12 (Pt 5):800-805.
129. Abramoff MD, Kalmann R, de Graaf ME, Stilma JS, Mourits MP. Rectus extraocular muscle paths and decompression surgery for Graves orbitopathy: mechanism of motility disturbances. *Investigative ophthalmology & visual science*. 2002;43(2):300-307.
130. Trokel SL, Cooper WC. Symposium: extraocular muscle problems associated with graves' disease. Orbital decompression: effect on motility and globe position. *Ophthalmology*. 1979;86(12):2064-2070.
131. Serafino M, Fogagnolo P, Trivedi RH, Saunders RA, Nucci P. Torsional diplopia after orbital decompression and strabismus surgery. *European journal of ophthalmology*. 2010;20(2):437-441.
132. Finn AP, Bleier B, Cestari DM, et al. A Retrospective Review of Orbital Decompression for Thyroid Orbitopathy with Endoscopic Preservation of the Inferomedial Orbital Bone Strut. *Ophthalmic Plast Reconstr Surg*. 2017;33(5):334-339.
133. Schotthoefler EO, Wallace DK. Strabismus associated with thyroid eye disease. *Current opinion in ophthalmology*. 2007;18(5):361-365.
134. Zloto O, Ben Simon G, Didi Fabian I, et al. Association of orbital decompression and the characteristics of subsequent strabismus surgery in thyroid eye disease. *Canadian journal of ophthalmology Journal canadien d'ophtalmologie*. 2017;52(3):264-268.
135. Mainville NP, Jordan DR. Effect of orbital decompression on diplopia in thyroid-related orbitopathy. *Ophthalmic plastic and reconstructive surgery*. 2014;30(2):137-140.
136. Scott AB. Injection treatment of endocrine orbital myopathy. *Documenta ophthalmologica Advances in ophthalmology*. 1984;58(1):141-145.
137. Dunn WJ, Arnold AC, O'Connor PS. Botulinum toxin for the treatment of dysthyroid ocular myopathy. *Ophthalmology*. 1986;93(4):470-475.
138. Lyons CJ, Vickers SF, Lee JP. Botulinum toxin therapy in dysthyroid strabismus. *Eye (Lond)*. 1990;4 (Pt 4):538-542.
139. Granet DB, Hodgson N, Godfrey KJ, et al. Chemodenervation of extraocular muscles with botulinum toxin in thyroid eye disease. *Graefe's archive for clinical and experimental ophthalmology = Albrecht von Graefes Archiv fur klinische und experimentelle Ophthalmologie*. 2016;254(5):999-1003.

140. Al Qahtani ES, Rootman J, Kersey J, Godoy F, Lyons CJ. Clinical Pearls and Management Recommendations for Strabismus due to Thyroid Orbitopathy. *Middle East African journal of ophthalmology*. 2015;22(3):307-311.
141. Coats DK, Paysse EA, Plager DA, Wallace DK. Early strabismus surgery for thyroid ophthalmopathy. *Ophthalmology*. 1999;106(2):324-329.
142. Mourits MP, Prummel MF, Wiersinga WM, Koornneef L. Clinical activity score as a guide in the management of patients with Graves' ophthalmopathy. *Clin Endocrinol (Oxf)*. 1997;47(1):9-14.
143. Politi LS, Godi C, Cammarata G, et al. Magnetic resonance imaging with diffusion-weighted imaging in the evaluation of thyroid-associated orbitopathy: getting below the tip of the iceberg. *European radiology*. 2014;24(5):1118-1126.
144. Bailey CC, Kabala J, Laitt R, et al. Magnetic resonance imaging in thyroid eye disease. *Eye (Lond)*. 1996;10 (Pt 5):617-619.
145. Yoo SH, Pineles SL, Goldberg RA, Velez FG. Rectus muscle resection in Graves' ophthalmopathy. *Journal of AAPOS : the official publication of the American Association for Pediatric Ophthalmology and Strabismus*. 2013;17(1):9-15.
146. Ellis EM, Kinori M, Robbins SL, Granet DB. Pulled-in-two syndrome: a multicenter survey of risk factors, management and outcomes. *Journal of AAPOS : the official publication of the American Association for Pediatric Ophthalmology and Strabismus*. 2016;20(5):387-391.
147. Nardi M. Squint surgery in TED -- hints and fints, or why Graves' patients are difficult patients. *Orbit*. 2009;28(4):245-250.
148. Chatzistefanou KI, Kushner BJ, Gentry LR. Magnetic resonance imaging of the arc of contact of extraocular muscles: implications regarding the incidence of slipped muscles. *Journal of AAPOS : the official publication of the American Association for Pediatric Ophthalmology and Strabismus*. 2000;4(2):84-93.
149. Hudson HL, Feldon SE. Late overcorrection of hypotropia in Graves ophthalmopathy. Predictive factors. *Ophthalmology*. 1992;99(3):356-360.
150. Kushner BJ. An evaluation of the semiadjustable suture strabismus surgical procedure. *Journal of AAPOS : the official publication of the American Association for Pediatric Ophthalmology and Strabismus*. 2004;8(5):481-487.
151. Dagi LR. Understanding and managing vertical strabismus from thyroid eye disease. *Journal of AAPOS : the official publication of the American Association for Pediatric Ophthalmology and Strabismus*. 2018.
152. Flanders M, Hastings M. Diagnosis and surgical management of strabismus associated with thyroid-related orbitopathy. *Journal of pediatric ophthalmology and strabismus*. 1997;34(6):333-340.
153. Wei Y, Kang XL, Del Monte MA. Enlargement of the superior rectus and superior oblique muscles causes intorsion in Graves' eye disease. *The British journal of ophthalmology*. 2016;100(9):1280-1284.
154. Volpe NJ, Mirza-George N, Binenbaum G. Surgical management of vertical ocular misalignment in thyroid eye disease using an adjustable suture technique. *Journal of AAPOS : the official publication of the American Association for Pediatric Ophthalmology and Strabismus*. 2012;16(6):518-522.
155. Holmes JM, Hatt SR, Bradley EA. Identifying masked superior oblique involvement in thyroid eye disease to avoid postoperative A-pattern exotropia and intorsion. *Journal of*

- AAPOS : the official publication of the American Association for Pediatric Ophthalmology and Strabismus.* 2012;16(3):280-285.
156. Gomi CF, Yang SW, Granet DB, et al. Change in proptosis following extraocular muscle surgery: effects of muscle recession in thyroid-associated orbitopathy. *Journal of AAPOS : the official publication of the American Association for Pediatric Ophthalmology and Strabismus.* 2007;11(4):377-380.
 157. Zoumalan CI, Lelli GJ, Jr., Kazim M. Tenon recession: a novel adjunct to improve outcome in the treatment of large-angle strabismus in thyroid eye disease. *Ophthalmic Plast Reconstr Surg.* 2011;27(4):287-292.
 158. Scofield-Kaplan SM, Dunbar K, Stein G, Kazim M. Improvement in Both Primary and Eccentric Ocular Alignment After Thyroid Eye Disease-Strabismus Surgery With Tenon's Recession. *Ophthalmic Plast Reconstr Surg.* 2018;34(4S Suppl 1):S85-S89.
 159. Kraus DJ, Bullock JD. Treatment of thyroid ocular myopathy with adjustable and nonadjustable suture strabismus surgery. *Transactions of the American Ophthalmological Society.* 1993;91:67-79; discussion 79-84.
 160. Peragallo JH, Velez FG, Demer JL, Pineles SL. Postoperative drift in patients with thyroid ophthalmopathy undergoing unilateral inferior rectus muscle recession. *Strabismus.* 2013;21(1):23-28.
 161. Nicholson BP, De Alba M, Perry JD, Traboulsi EI. Efficacy of the intraoperative relaxed muscle positioning technique in thyroid eye disease and analysis of cases requiring reoperation. *Journal of AAPOS : the official publication of the American Association for Pediatric Ophthalmology and Strabismus.* 2011;15(4):321-325.
 162. Ludwig IH, Brown MS. Flap tear of rectus muscles: an underlying cause of strabismus after orbital trauma. *Ophthalmic plastic and reconstructive surgery.* 2002;18(6):443-449; discussion 450.
 163. Ludwig IH, Brown MS. Strabismus due to flap tear of a rectus muscle. *Transactions of the American Ophthalmological Society.* 2001;99:53-62; discussion 62-53.
 164. Wojno TH. The incidence of extraocular muscle and cranial nerve palsy in orbital floor blow-out fractures. *Ophthalmology.* 1987;94(6):682-687.
 165. al-Qurainy IA. Convergence insufficiency and failure of accommodation following midfacial trauma. *The British journal of oral & maxillofacial surgery.* 1995;33(2):71-75.
 166. Baker RS, Epstein AD. Ocular motor abnormalities from head trauma. *Survey of ophthalmology.* 1991;35(4):245-267.
 167. al-Qurainy IA, Stassen LF, Dutton GN, Moos KF, el-Attar A. Diplopia following midfacial fractures. *The British journal of oral & maxillofacial surgery.* 1991;29(5):302-307.
 168. Putterman AM, Stevens T, Urist MJ. Nonsurgical management of blow-out fractures of the orbital floor. *American journal of ophthalmology.* 1974;77(2):232-239.
 169. Hawes MJ, Dortzbach RK. Surgery on orbital floor fractures. Influence of time of repair and fracture size. *Ophthalmology.* 1983;90(9):1066-1070.
 170. Cole HG, Smith B. Eye muscle imbalance complicating orbital floor fractures. *American journal of ophthalmology.* 1963;55:930-935.
 171. Van Eeckhoutte L, De Clippeleir L, Apers R, Van Lammeren M, Janssens H, Baekeland L. A protocol for extraocular muscle surgery after orbital floor fracture ("blow-out"). *Binocular vision & strabismus quarterly.* 1998;13(1):29-36.

172. Thacker NM, Velez FG, Demer JL, Rosenbaum AL. Strabismic complications following endoscopic sinus surgery: diagnosis and surgical management. *Journal of AAPOS : the official publication of the American Association for Pediatric Ophthalmology and Strabismus*. 2004;8(5):488-494.
173. Bhatti MT, Stankiewicz JA. Ophthalmic complications of endoscopic sinus surgery. *Survey of ophthalmology*. 2003;48(4):389-402.
174. Galli M. Diplopia following cosmetic surgery. *The American orthoptic journal*. 2012;62:19-21.
175. Wong TY, Klein BE, Klein R. The prevalence and 5-year incidence of ocular trauma. The Beaver Dam Eye Study. *Ophthalmology*. 2000;107(12):2196-2202.
176. Loon SC, Tay WT, Saw SM, Wang JJ, Wong TY. Prevalence and risk factors of ocular trauma in an urban south-east Asian population: the Singapore Malay Eye Study. *Clinical & experimental ophthalmology*. 2009;37(4):362-367.
177. Wang JD, Xu L, Wang YX, You QS, Zhang JS, Jonas JB. Prevalence and incidence of ocular trauma in North China: the Beijing Eye Study. *Acta ophthalmologica*. 2012;90(1):e61-67.
178. Henson KJ. Diagnostic tools in the evaluation of strabismus secondary to trauma. *American Orthoptic Journal*. 2004;54:2-6.
179. Mauriello JA, Jr., Antonacci R, Mostafavi R, et al. Combined paresis and restriction of the extraocular muscles after orbital fracture: a study of 16 patients. *Ophthalmic plastic and reconstructive surgery*. 1996;12(3):206-210.
180. Borumandi F, Rippel C, Gaggl A. Orbital trauma and its impact on the heart. *BMJ case reports*. 2014;2014.
181. Shin GS, Demer JL, Rosenbaum AL. High resolution, dynamic, magnetic resonance imaging in complicated strabismus. *Journal of pediatric ophthalmology and strabismus*. 1996;33(6):282-290.
182. Demer JL, Clark RA, Kono R, Wright W, Velez F, Rosenbaum AL. A 12-year, prospective study of extraocular muscle imaging in complex strabismus. *Journal of AAPOS : the official publication of the American Association for Pediatric Ophthalmology and Strabismus*. 2002;6(6):337-347.
183. Ela-Dalman N, Velez FG, Rosenbaum AL. Importance of sagittal orbital imaging in evaluating extraocular muscle trauma following endoscopic sinus surgery. *The British journal of ophthalmology*. 2006;90(6):682-685.
184. Ward TP, Thach AB, Madigan WP, Jr., Berland JE. Magnetic resonance imaging in posttraumatic strabismus. *Journal of pediatric ophthalmology and strabismus*. 1997;34(2):131-134.
185. Ortube MC, Rosenbaum AL, Goldberg RA, Demer JL. Orbital imaging demonstrates occult blow out fracture in complex strabismus. *Journal of AAPOS : the official publication of the American Association for Pediatric Ophthalmology and Strabismus*. 2004;8(3):264-273.
186. Manfredi SJ, Raji MR, Sprinkle PM, Weinstein GW, Minardi LM, Swanson TJ. Computerized tomographic scan findings in facial fractures associated with blindness. *Plastic and reconstructive surgery*. 1981;68(4):479-490.
187. Emery JM, Noorden GK, Sclernitzauer DA. Orbital floor fractures: long-term follow-up of cases with and without surgical repair. *Transactions - American Academy of*

- Ophthalmology and Otolaryngology American Academy of Ophthalmology and Otolaryngology*. 1971;75(4):802-812.
188. Burnstine MA. Clinical recommendations for repair of isolated orbital floor fractures: an evidence-based analysis. *Ophthalmology*. 2002;109(7):1207-1210; discussion 1210-1201; quiz 1212-1203.
 189. Jordan DR, Allen LH, White J, Harvey J, Pashby R, Esmaeli B. Intervention within days for some orbital floor fractures: the white-eyed blowout. *Ophthalmic plastic and reconstructive surgery*. 1998;14(6):379-390.
 190. Abrishami M, Aletaha M, Bagheri A, Salour SH, Yazdani S. Traumatic subluxation of the globe into the maxillary sinus. *Ophthalmic Plast Reconstr Surg*. 2007;23(2):156-158.
 191. Pelton RW, Rainey AM, Lee AG. Traumatic subluxation of the globe into the maxillary sinus. *AJNR American journal of neuroradiology*. 1998;19(8):1450-1451.
 192. Silverman N, Spindle J, Tang SX, et al. Orbital floor fracture with entrapment: Imaging and clinical correlations in 45 cases. *Orbit*. 2017;36(5):331-336.
 193. Biesman BS, Hornblass A, Lisman R, Kazlas M. Diplopia after surgical repair of orbital floor fractures. *Ophthalmic plastic and reconstructive surgery*. 1996;12(1):9-16; discussion 17.
 194. Clark RA. The Role of Extraocular Muscle Pulleys in Incomitant Non-Paralytic Strabismus. *Middle East African journal of ophthalmology*. 2015;22(3):279-285.
 195. Hall LS, McCann JD, Goldberg RA, Santiago AP, Rosenbaum AL. Strabismus after orbital fractures and sinus surgery. In: Rosenbaum AL, Santiago AP, eds. *Clinical strabismus management* Philadelphia: W.B. Saunders Company; 1999:309-322.
 196. Shah HA, Shipchandler T, Vernon D, et al. Extra-ocular movement restriction and diplopia following orbital fracture repair. *American journal of otolaryngology*. 2018;39(1):34-36.
 197. Kersey TL, Ng SG, Rosser P, Sloan B, Hart R. Orbital adherence with titanium mesh floor implants: a review of 10 cases. *Orbit*. 2013;32(1):8-11.
 198. Tiedemann LM, Lefebvre DR, Wan MJ, Dagi LR. Iatrogenic inferior oblique palsy: intentional disinsertion during transcaruncular approach to orbital fracture repair. *Journal of AAPOS : the official publication of the American Association for Pediatric Ophthalmology and Strabismus*. 2014;18(5):511-514.
 199. Pineles SL, Laursen J, Goldberg RA, Demer JL, Velez FG. Function of transected or avulsed rectus muscles following recovery using an anterior orbitotomy approach. *Journal of AAPOS : the official publication of the American Association for Pediatric Ophthalmology and Strabismus*. 2012;16(4):336-341.
 200. Thacker NM, Velez FG, Rosenbaum AL. Combined adjustable rectus muscle resection--recession for incomitant strabismus. *Journal of AAPOS : the official publication of the American Association for Pediatric Ophthalmology and Strabismus*. 2005;9(2):137-140.
 201. Sobol EK, Rosenberg JB. Strabismus After Ocular Surgery. *Journal of pediatric ophthalmology and strabismus*. 2017;54(5):272-281.
 202. Capo H, Guyton DL. Ipsilateral hypertropia after cataract surgery. *Ophthalmology*. 1996;103(5):721-730.
 203. Rainin EA, Carlson BM. Postoperative diplopia and ptosis. A clinical hypothesis based on the myotoxicity of local anesthetics. *Arch Ophthalmol*. 1985;103(9):1337-1339.

204. Porter JD, Edney DP, McMahon EJ, Burns LA. Extraocular myotoxicity of the retrobulbar anesthetic bupivacaine hydrochloride. *Investigative ophthalmology & visual science*. 1988;29(2):163-174.
205. Scott AB, Alexander DE, Miller JM. Bupivacaine injection of eye muscles to treat strabismus. *The British journal of ophthalmology*. 2007;91(2):146-148.
206. Debert I, Miller JM, Danh KK, Scott AB. Pharmacologic injection treatment of comitant strabismus. *Journal of AAPOS : the official publication of the American Association for Pediatric Ophthalmology and Strabismus*. 2016;20(2):106-111 e102.
207. Capo H, Roth E, Johnson T, Munoz M, Siatkowski RM. Vertical strabismus after cataract surgery. *Ophthalmology*. 1996;103(6):918-921.
208. Hunter DG, Lam GC, Guyton DL. Inferior oblique muscle injury from local anesthesia for cataract surgery. *Ophthalmology*. 1995;102(3):501-509.
209. Erie JC. Acquired Brown's syndrome after peribulbar anesthesia. *American journal of ophthalmology*. 1990;109(3):349-350.
210. Spierer A, Schwalb E. Superior oblique muscle paresis after sub-Tenon's anesthesia for cataract surgery. *J Cataract Refract Surg*. 1999;25(1):144-145.
211. Costa PG, Debert I, Passos LB, Polati M. Persistent diplopia and strabismus after cataract surgery under local anesthesia. *Binocular vision & strabismus quarterly*. 2006;21(3):155-158.
212. Hamed LM, Lingua RW. Thyroid eye disease presenting after cataract surgery. *Journal of pediatric ophthalmology and strabismus*. 1990;27(1):10-15.
213. Sun PY, Leske DA, Holmes JM, Khanna CL. Diplopia in Medically and Surgically Treated Patients with Glaucoma. *Ophthalmology*. 2017;124(2):257-262.
214. Dobler-Dixon AA, Cantor LB, Sondhi N, Ku WS, Hoop J. Prospective evaluation of extraocular motility following double-plate molteno implantation. *Arch Ophthalmol*. 1999;117(9):1155-1160.
215. Frank JW, Perkins TW, Kushner BJ. Ocular motility defects in patients with the Krupin valve implant. *Ophthalmic surgery*. 1995;26(3):228-232.
216. Coats DK, Paysse EA, Orenga-Nania S. Acquired Pseudo-Brown's syndrome immediately following Ahmed valve glaucoma implant. *Ophthalmic Surg Lasers*. 1999;30(5):396-397.
217. Dobler AA, Sondhi N, Cantor LB, Ku S. Acquired Brown's syndrome after a double-plate Molteno implant. *American journal of ophthalmology*. 1993;116(5):641-642.
218. Roizen A, Ela-Dalman N, Velez FG, Coleman AL, Rosenbaum AL. Surgical treatment of strabismus secondary to glaucoma drainage device. *Arch Ophthalmol*. 2008;126(4):480-486.
219. Munoz M, Rosenbaum AL. Long-term strabismus complications following retinal detachment surgery. *Journal of pediatric ophthalmology and strabismus*. 1987;24(6):309-314.
220. Hwang JM, Wright KW. Combined study on the causes of strabismus after the retinal surgery. *Korean journal of ophthalmology : KJO*. 1994;8(2):83-91.
221. Macleod JD, Morris RJ. Detached superior rectus following scleral buckling: anatomy and surgical management. *Eye (Lond)*. 1997;11 (Pt 1):30-32.
222. Chang MY, Yulek F, Pineles SL, Velez FG. Surgery for superior oblique tendon anteriorization and entrapment following scleral buckle. *Journal of AAPOS : the official*

- publication of the American Association for Pediatric Ophthalmology and Strabismus.* 2016;20(2):165 e161-162.
223. Wright LA, Cleary M, Barrie T, Hammer HM. Motility and binocularity outcomes in vitrectomy versus scleral buckling in retinal detachment surgery. *Graefe's archive for clinical and experimental ophthalmology = Albrecht von Graefes Archiv fur klinische und experimentelle Ophthalmologie.* 1999;237(12):1028-1032.
 224. Raab EL, Metz HS, Ellis FD. Medial rectus injury after pterygium excision. *Arch Ophthalmol.* 1989;107(10):1428.
 225. Ela-Dalman N, Velez FG, Rosenbaum AL. Incomitant esotropia following pterygium excision surgery. *Arch Ophthalmol.* 2007;125(3):369-373.
 226. Laria C, Shokida F, Tatarchuck P, Pinero DP, Gonzalez X. New diplopic restrictive strabismus as a sequela after conjunctival surgery for conjunctival lesions: a series of 3 cases, management and outcome. *Binocular vision & strabology quarterly, Simms-Romano's.* 2012;27(2):113-121.
 227. Ugrin MC, Molinari A. Disinsertion of the medial rectus following pterygium surgery: signs and management. *Strabismus.* 1999;7(3):147-152.
 228. Neely KA, Ernest JT, Mottier M. Combined superior oblique paresis and Brown's syndrome after blepharoplasty. *American journal of ophthalmology.* 1990;109(3):347-349.
 229. Syniuta LA, Goldberg RA, Thacker NM, Rosenbaum AL. Acquired strabismus following cosmetic blepharoplasty. *Plastic and reconstructive surgery.* 2003;111(6):2053-2059.
 230. Pirouzian A, Goldberg RA, Demer JL. Inferior rectus pulley hindrance: a mechanism of restrictive hypertropia following lower lid surgery. *Journal of AAPOS : the official publication of the American Association for Pediatric Ophthalmology and Strabismus.* 2004;8(4):338-344.
 231. Jameson NA, Good WV, Hoyt CS. Fat adherence simulating inferior oblique palsy following blepharoplasty. *Arch Ophthalmol.* 1992;110(10):1369.
 232. Johnson DA. Persistent vertical binocular diplopia after cataract surgery. *American journal of ophthalmology.* 2001;132(6):831-835.
 233. Brown SM, Brooks SE, Mazow ML, et al. Cluster of diplopia cases after periocular anesthesia without hyaluronidase. *J Cataract Refract Surg.* 1999;25(9):1245-1249.
 234. Hamada S, Devys JM, Xuan TH, et al. Role of hyaluronidase in diplopia after peribulbar anesthesia for cataract surgery. *Ophthalmology.* 2005;112(5):879-882.
 235. Rauscher FM, Gedde SJ, Schiffman JC, et al. Motility disturbances in the tube versus trabeculectomy study during the first year of follow-up. *American journal of ophthalmology.* 2009;147(3):458-466.
 236. Abdelaziz A, Capo H, Banitt MR, et al. Diplopia after glaucoma drainage device implantation. *Journal of AAPOS : the official publication of the American Association for Pediatric Ophthalmology and Strabismus.* 2013;17(2):192-196.
 237. Berk AT, Saatci AO, Kir E, Durak I, Kaynak S. Extraocular muscle imbalance after scleral buckling. *Strabismus.* 1996;4(2):69-75.
 238. Smiddy WE, Loupe D, Michels RG, Enger C, Glaser BM, deBustros S. Extraocular muscle imbalance after scleral buckling surgery. *Ophthalmology.* 1989;96(10):1485-1489; discussion 1489-1490.

239. Goezinne F, Berendschot TT, van Daal EW, et al. Diplopia was not predictable and not associated with buckle position after scleral buckling surgery for retinal detachment. *Retina*. 2012;32(8):1514-1524.
240. Hayworth RS, Lisman RD, Muchnick RS, Smith B. Diplopia following blepharoplasty. *Annals of ophthalmology*. 1984;16(5):448-451.
241. Munoz M, Parrish RK, 2nd. Strabismus following implantation of Baerveldt drainage devices. *Arch Ophthalmol*. 1993;111(8):1096-1099.
242. Wu TE, Rosenbaum AL, Demer JL. Severe strabismus after scleral buckling: multiple mechanisms revealed by high-resolution magnetic resonance imaging. *Ophthalmology*. 2005;112(2):327-336.
243. Wong V, Kasbekar S, Young J, Stappler T, Marsh IB, Durnian JM. The effect of scleral exoplant removal on strabismus following retinal detachment repair. *Journal of AAPOS : the official publication of the American Association for Pediatric Ophthalmology and Strabismus*. 2011;15(4):331-333.
244. Rabinowitz R, Velez FG, Pineles SL. Risk factors influencing the outcome of strabismus surgery following retinal detachment surgery with scleral buckle. *Journal of AAPOS : the official publication of the American Association for Pediatric Ophthalmology and Strabismus*. 2013;17(6):594-597.
245. Chen CJ, Kosek K, Benvenuti E. Outcomes and complications of hydrogel scleral explant removal. *Ophthalmic surgery, lasers & imaging : the official journal of the International Society for Imaging in the Eye*. 2012;43(5):383-387.
246. Petitto VB, Buckley EG. Use of botulinum toxin in strabismus after retinal detachment surgery. *Ophthalmology*. 1991;98(4):509-512; discussion 512-503.
247. Dosunmu EO, Hatt SR, Leske DA, Hodge DO, Holmes JM. Incidence and Etiology of Presumed Fourth Cranial Nerve Palsy: A Population-based Study. *American journal of ophthalmology*. 2018;185:110-114.
248. Akbari MR, Khorrami Nejad M, Askarizadeh F, Pour FF, Ranjbar Pazooki M, Moeinitabar MR. Facial asymmetry in ocular torticollis. *Journal of current ophthalmology*. 2015;27(1-2):4-11.
249. Rucker CW. Paralysis of the third, fourth and sixth cranial nerves. *American journal of ophthalmology*. 1958;46(6):787-794.
250. Rucker CW. The causes of paralysis of the third, fourth and sixth cranial nerves. *American journal of ophthalmology*. 1966;61(5 Pt 2):1293-1298.
251. Rush JA, Younge BR. Paralysis of cranial nerves III, IV, and VI. Cause and prognosis in 1,000 cases. *Arch Ophthalmol*. 1981;99(1):76-79.
252. Brodsky MC, Donahue SP, Vaphiades M, Brandt T. Skew deviation revisited. *Survey of ophthalmology*. 2006;51(2):105-128.
253. Mollan SP, Edwards JH, Price A, Abbott J, Burdon MA. Aetiology and outcomes of adult superior oblique palsies: a modern series. *Eye (Lond)*. 2009;23(3):640-644.
254. Chen VM, Dagi LR. Ocular misalignment in Graves disease may mimic that of superior oblique palsy. *Journal of neuro-ophthalmology : the official journal of the North American Neuro-Ophthalmology Society*. 2008;28(4):302-304.
255. Plager DA. Tendon laxity in superior oblique palsy. *Ophthalmology*. 1992;99(7):1032-1038.
256. Archer SM. Management of paretic vertical deviations. *The American orthoptic journal*. 2011;61:6-12.

257. Bata BM, Leske DA, Holmes JM. Adjustable Bilateral Superior Oblique Tendon Advancement for Bilateral Fourth Nerve Palsy. *American journal of ophthalmology*. 2017;178:115-121.
258. Fells P. Management of paralytic strabismus. *The British journal of ophthalmology*. 1974;58(3):255-265.
259. Nejad M, Thacker N, Velez FG, Rosenbaum AL, Pineles SL. Surgical results of patients with unilateral superior oblique palsy presenting with large hypertropias. *Journal of pediatric ophthalmology and strabismus*. 2013;50(1):44-52.
260. Aseff AJ, Munoz M. Outcome of surgery for superior oblique palsy with contracture of ipsilateral superior rectus treated by superior rectus recession. *Binocular vision & strabismus quarterly*. 1998;13(3):177-180.
261. Dieterich M, Brandt T. Ocular torsion and tilt of subjective visual vertical are sensitive brainstem signs. *Annals of neurology*. 1993;33(3):292-299.
262. Tilikete C, Vighetto A. Internuclear ophthalmoplegia with skew deviation. Two cases with an isolated circumscribed lesion of the medial longitudinal fasciculus. *European neurology*. 2000;44(4):258-259.
263. Zwergal A, Cnyrim C, Arbusow V, et al. Unilateral INO is associated with ocular tilt reaction in pontomesencephalic lesions: INO plus. *Neurology*. 2008;71(8):590-593.
264. Brandt T, Dieterich M. Pathological eye-head coordination in roll: tonic ocular tilt reaction in mesencephalic and medullary lesions. *Brain : a journal of neurology*. 1987;110 (Pt 3):649-666.
265. Dieterich M, Brandt T. Thalamic infarctions: differential effects on vestibular function in the roll plane (35 patients). *Neurology*. 1993;43(9):1732-1740.
266. Rabinovitch HE, Sharpe JA, Sylvester TO. The ocular tilt reaction. A paroxysmal dyskinesia associated with elliptical nystagmus. *Arch Ophthalmol*. 1977;95(8):1395-1398.
267. Brandt T, Dieterich M. Skew deviation with ocular torsion: a vestibular brainstem sign of topographic diagnostic value. *Annals of neurology*. 1993;33(5):528-534.
268. Lemos J, Subei A, Sousa M, et al. Differentiating Acute and Subacute Vertical Strabismus Using Different Head Positions During the Upright-Supine Test. *JAMA ophthalmology*. 2018;136(4):322-328.
269. Buckley SA, Elston JS. Surgical treatment of supranuclear and internuclear ocular motility disorders. *Eye (Lond)*. 1997;11 (Pt 3):377-380.
270. Lee J. Management of selected forms of neurogenic strabismus. In: Rosenbaum AL, Santiago AP, eds. *Clinical Strabismus Management. Principles and Surgical Techniques*. Philadelphia: W. B. Saunders Company; 1999:389-391.
271. Brodsky MC, Holmes JM. Torsional augmentation for the treatment of lateropulsion and torticollis in partial ocular tilt reaction. *Journal of AAPOS : the official publication of the American Association for Pediatric Ophthalmology and Strabismus*. 2012;16(2):141-144.
272. Zadro I, Barun B, Habek M, Brinar VV. Isolated cranial nerve palsies in multiple sclerosis. *Clinical neurology and neurosurgery*. 2008;110(9):886-888.
273. Patel SV, Mutyala S, Leske DA, Hodge DO, Holmes JM. Incidence, associations, and evaluation of sixth nerve palsy using a population-based method. *Ophthalmology*. 2004;111(2):369-375.
274. King AJ, Stacey E, Stephenson G, Trimble RB. Spontaneous recovery rates for unilateral sixth nerve palsies. *Eye (Lond)*. 1995;9 (Pt 4):476-478.

275. Durkin SR, Tennekoon S, Kleinschmidt A, Casson RJ, Selva D, Crompton JL. Bilateral sixth nerve palsy. *Ophthalmology*. 2006;113(11):2108-2109.
276. Holmes JM, Droste PJ, Beck RW. The natural history of acute traumatic sixth nerve palsy or paresis. *Journal of AAPOS : the official publication of the American Association for Pediatric Ophthalmology and Strabismus*. 1998;2(5):265-268.
277. Rassi MS, Hulou MM, Almefty K, et al. Pediatric Clival Chordoma: A Curable Disease that Conforms to Collins' Law. *Neurosurgery*. 2017.
278. Santiago AP, Rosenbaum AL. Sixth cranial nerve palsy. In: Rosenbaum AL, Santiago AP, eds. *Clinical strabismus management : principles and surgical techniques*. Philadelphia: Saunders; 1999:259-271.
279. Li C, Tang Y, Ge H, et al. Sectional anatomy of the abducens nerve: according to 3D-SPACE magnetic resonance sequences correlated with cryosectional specimens. *Surgical and radiologic anatomy : SRA*. 2015;37(8):921-929.
280. Linskey ME, Sekhar LN, Hirsch W, Jr., Yonas H, Horton JA. Aneurysms of the intracavernous carotid artery: clinical presentation, radiographic features, and pathogenesis. *Neurosurgery*. 1990;26(1):71-79.
281. Morard M, Tcherekayev V, de Tribolet N. The superior orbital fissure: a microanatomical study. *Neurosurgery*. 1994;35(6):1087-1093.
282. Elder C, Hainline C, Galetta SL, Balcer LJ, Rucker JC. Isolated Abducens Nerve Palsy: Update on Evaluation and Diagnosis. *Current neurology and neuroscience reports*. 2016;16(8):69.
283. Holmes JM, Leske DA, Christiansen SP. Initial treatment outcomes in chronic sixth nerve palsy. *Journal of AAPOS : the official publication of the American Association for Pediatric Ophthalmology and Strabismus*. 2001;5(6):370-376.
284. Scott AB, Kraft SP. Botulinum toxin injection in the management of lateral rectus paresis. *Ophthalmology*. 1985;92(5):676-683.
285. Biglan AW, Burnstine RA, Rogers GL, Saunders RA. Management of strabismus with botulinum A toxin. *Ophthalmology*. 1989;96(7):935-943.
286. Mehendale RA, Dagi LR, Wu C, Ledoux D, Johnston S, Hunter DG. Superior rectus transposition and medial rectus recession for Duane syndrome and sixth nerve palsy. *Arch Ophthalmol*. 2012;130(2):195-201.
287. Rosenbaum AL. Costenbader Lecture. The efficacy of rectus muscle transposition surgery in esotropic Duane syndrome and VI nerve palsy. *Journal of AAPOS : the official publication of the American Association for Pediatric Ophthalmology and Strabismus*. 2004;8(5):409-419.
288. Foster RS. Vertical muscle transposition augmented with lateral fixation. *Journal of AAPOS : the official publication of the American Association for Pediatric Ophthalmology and Strabismus*. 1997;1(1):20-30.
289. Gunton KB. Vertical rectus transpositions in sixth nerve palsies. *Current opinion in ophthalmology*. 2015;26(5):366-370.
290. Britt MT, Velez FG, Thacker N, Alcorn D, Foster RS, Rosenbaum AL. Partial rectus muscle-augmented transpositions in abduction deficiency. *Journal of AAPOS : the official publication of the American Association for Pediatric Ophthalmology and Strabismus*. 2003;7(5):325-332.

291. Holmes JM, Leske DA. Long-term outcomes after surgical management of chronic sixth nerve palsy. *Journal of AAPOS : the official publication of the American Association for Pediatric Ophthalmology and Strabismus*. 2002;6(5):283-288.
292. Richards BW, Jones FR, Jr., Younge BR. Causes and prognosis in 4,278 cases of paralysis of the oculomotor, trochlear, and abducens cranial nerves. *American journal of ophthalmology*. 1992;113(5):489-496.
293. Fang C, Leavitt JA, Hodge DO, Holmes JM, Mohnney BG, Chen JJ. Incidence and Etiologies of Acquired Third Nerve Palsy Using a Population-Based Method. *JAMA ophthalmology*. 2017;135(1):23-28.
294. Fujiwara S, Fujii K, Nishio S, Matsushima T, Fukui M. Oculomotor nerve palsy in patients with cerebral aneurysms. *Neurosurgical review*. 1989;12(2):123-132.
295. Park HK, Rha HK, Lee KJ, Chough CK, Joo W. Microsurgical Anatomy of the Oculomotor Nerve. *Clinical anatomy*. 2017;30(1):21-31.
296. Derakhshan I, Sabouri-Deylami M, Kaufman B. Bilateral Nothnagel syndrome. Clinical and roentgenological observations. *Stroke*. 1980;11(2):177-179.
297. Duncan GW, Weindling SM. Posterior cerebral artery stenosis with midbrain infarction. *Stroke*. 1995;26(5):900-902.
298. Elmalem VI, Hudgins PA, Bruce BB, Newman NJ, Biousse V. Underdiagnosis of posterior communicating artery aneurysm in noninvasive brain vascular studies. *Journal of neuro-ophthalmology : the official journal of the North American Neuro-Ophthalmology Society*. 2011;31(2):103-109.
299. Chakeres DW, Kapila A. Radiology of the ambient cistern. Part I: Normal. *Neuroradiology*. 1985;27(5):383-389.
300. Yasuda A, Campero A, Martins C, Rhoton AL, Jr., de Oliveira E, Ribas GC. Microsurgical anatomy and approaches to the cavernous sinus. *Neurosurgery*. 2005;56(1 Suppl):4-27; discussion 24-27.
301. Metz HS. Forced duction, active force generation, and saccadic velocity tests. *International ophthalmology clinics*. 1976;16(3):47-73.
302. Tantiwongkosi B, Hesselink JR. Imaging of Ocular Motor Pathway. *Neuroimaging clinics of North America*. 2015;25(3):425-438.
303. Talebnejad MR, Sharifi M, Nowroozzadeh MH. The role of Botulinum toxin in management of acute traumatic third-nerve palsy. *Journal of AAPOS : the official publication of the American Association for Pediatric Ophthalmology and Strabismus*. 2008;12(5):510-513.
304. Cabrejas L, Hurtado-Cena FJ, Tejedor J. Predictive factors of surgical outcome in oculomotor nerve palsy. *Journal of AAPOS : the official publication of the American Association for Pediatric Ophthalmology and Strabismus*. 2009;13(5):481-484.
305. Mazow ML. Third cranial nerve palsy: Diagnosis and management strategies. In: Rosenbaum AL, Santiago AP, eds. *Clinical strabismus management : principles and surgical techniques*. Philadelphia: Saunders; 1999:251-258.
306. Yanovitch T, Buckley E. Diagnosis and management of third nerve palsy. *Current opinion in ophthalmology*. 2007;18(5):373-378.
307. Deutsch JA, Greenwald MJ, Lingua RW, Nelson LB. Surgical Approaches to Strabismus After Third Nerve Palsy. *Journal of pediatric ophthalmology and strabismus*. 2015;52(6):326-330.

308. Velez FG, Thacker N, Britt MT, Alcorn D, Foster RS, Rosenbaum AL. Rectus muscle orbital wall fixation: a reversible profound weakening procedure. *Journal of AAPOS : the official publication of the American Association for Pediatric Ophthalmology and Strabismus*. 2004;8(5):473-480.
309. Singh A, Pandey PK, Mittal SK, Agrawal A, Bahuguna C, Kumar P. Impact of Superior Oblique Transposition on Primary Position Deviation, a Pattern and Intorsion in Third Nerve Palsy. *Strabismus*. 2016;24(4):173-177.
310. Eraslan M, Cerman E, Onal S, Ogut MS. Superior Oblique Anterior Transposition with Horizontal Recti Recession-Resection for Total Third-Nerve Palsy. *Journal of ophthalmology*. 2015;2015:780139.
311. Shah AS, Prabhu SP, Sadiq MA, Mantagos IS, Hunter DG, Dagi LR. Adjustable nasal transposition of split lateral rectus muscle for third nerve palsy. *JAMA ophthalmology*. 2014;132(8):963-969.
312. Gilhus NE, Verschuuren JJ. Myasthenia gravis: subgroup classification and therapeutic strategies. *The Lancet Neurology*. 2015;14(10):1023-1036.
313. Pal J, Rozsa C, Komoly S, Illes Z. Clinical and biological heterogeneity of autoimmune myasthenia gravis. *Journal of neuroimmunology*. 2011;231(1-2):43-54.
314. O'Brien MD. The miracle at St Alfege's: seventy years on. *Journal of the Royal Society of Medicine*. 2007;100(6):257.
315. Chen YL, Yeh JH, Chiu HC. Clinical features of myasthenia gravis patients with autoimmune thyroid disease in Taiwan. *Acta neurologica Scandinavica*. 2013;127(3):170-174.
316. Antonio-Santos AA, Eggenberger ER. Medical treatment options for ocular myasthenia gravis. *Current opinion in ophthalmology*. 2008;19(6):468-478.
317. Grob D, Arsura EL, Brunner NG, Namba T. The course of myasthenia gravis and therapies affecting outcome. *Annals of the New York Academy of Sciences*. 1987;505:472-499.
318. Chen CS, Lee AW, Miller NR, Lee AG. Double vision in a patient with thyroid disease: what's the big deal? *Survey of ophthalmology*. 2007;52(4):434-439.
319. Lepore FE, Sanborn GE, Slevin JT. Pupillary dysfunction in myasthenia gravis. *Annals of neurology*. 1979;6(1):29-33.
320. Yamazaki A, Ishikawa S. Abnormal pupillary responses in myasthenia gravis. A pupillographic study. *The British journal of ophthalmology*. 1976;60(8):575-580.
321. Kubis KC, Danesh-Meyer HV, Savino PJ, Sergott RC. The ice test versus the rest test in myasthenia gravis. *Ophthalmology*. 2000;107(11):1995-1998.
322. Chatzistefanou KI, Kouris T, Iliakis E, et al. The ice pack test in the differential diagnosis of myasthenic diplopia. *Ophthalmology*. 2009;116(11):2236-2243.
323. Odel JG, Winterkorn JM, Behrens MM. The sleep test for myasthenia gravis. A safe alternative to Tensilon. *Journal of clinical neuro-ophthalmology*. 1991;11(4):288-292.
324. Phillips LH, 2nd, Melnick PA. Diagnosis of myasthenia gravis in the 1990s. *Seminars in neurology*. 1990;10(1):62-69.
325. Barton JJ, Fouladvand M. Ocular aspects of myasthenia gravis. *Seminars in neurology*. 2000;20(1):7-20.
326. Padua L, Stalberg E, LoMonaco M, Evoli A, Batocchi A, Tonali P. SFEMG in ocular myasthenia gravis diagnosis. *Clinical neurophysiology : official journal of the International Federation of Clinical Neurophysiology*. 2000;111(7):1203-1207.

327. Kupersmith MJ, Moster M, Bhuiyan S, Warren F, Weinberg H. Beneficial effects of corticosteroids on ocular myasthenia gravis. *Archives of neurology*. 1996;53(8):802-804.
328. Oosterhuis HJ. The natural course of myasthenia gravis: a long term follow up study. *Journal of neurology, neurosurgery, and psychiatry*. 1989;52(10):1121-1127.
329. Acheson JF, Elston JS, Lee JP, Fells P. Extraocular muscle surgery in myasthenia gravis. *The British journal of ophthalmology*. 1991;75(4):232-235.
330. Davidson JL, Rosenbaum AL, McCall LC. Strabismus surgery in patients with myasthenia. *Journal of pediatric ophthalmology and strabismus*. 1993;30(5):292-295.
331. Bentley CR, Dawson E, Lee JP. Active management in patients with ocular manifestations of myasthenia gravis. *Eye (Lond)*. 2001;15(Pt 1):18-22.
332. Ohtsuki H, Hasebe S, Okano M, Furuse T. Strabismus surgery in ocular myasthenia gravis. *Ophthalmologica Journal internationale d'ophtalmologie International journal of ophthalmology Zeitschrift fur Augenheilkunde*. 1996;210(2):95-100.
333. Morris OC, O'Day J. Strabismus surgery in the management of diplopia caused by myasthenia gravis. *The British journal of ophthalmology*. 2004;88(6):832.
334. Peragallo JH, Velez FG, Demer JL, Pineles SL. Long-term follow-up of strabismus surgery for patients with ocular myasthenia gravis. *Journal of neuro-ophthalmology : the official journal of the North American Neuro-Ophthalmology Society*. 2013;33(1):40-44.
335. Hamed LM. Strabismus after adult cataract surgery. In: Rosenbaum AL, Santiago, A.P., eds. *Clinical Strabismus Management*. Philadelphia: W.B. Saunders Company; 1999:371-379.
336. Kushner BJ. Fixation switch diplopia. *Arch Ophthalmol*. 1995;113(7):896-899.
337. Arnoldi K. Case corner: complicated fixation switch diplopia. *The American orthoptic journal*. 2009;59:111-115.
338. Scott MH, Noble AG, Raymond WRt, Parks MM. Prevalence of primary monofixation syndrome in parents of children with congenital esotropia. *Journal of pediatric ophthalmology and strabismus*. 1994;31(5):298-301; discussion 302.
339. Kushner BJ, Kowal L. Diplopia after refractive surgery: occurrence and prevention. *Arch Ophthalmol*. 2003;121(3):315-321.
340. Bixenman WW, Joffe L. Binocular diplopia associated with retinal wrinkling. *Journal of pediatric ophthalmology and strabismus*. 1984;21(6):215-219.
341. Benegas NM, Egbert J, Engel WK, Kushner BJ. Diplopia secondary to aniseikonia associated with macular disease. *Arch Ophthalmol*. 1999;117(7):896-899.
342. Burgess D, Roper-Hall G, Burde RM. Binocular diplopia associated with subretinal neovascular membranes. *Arch Ophthalmol*. 1980;98(2):311-317.
343. De Pool ME, Campbell JP, Broome SO, Guyton DL. The dragged-fovea diplopia syndrome: clinical characteristics, diagnosis, and treatment. *Ophthalmology*. 2005;112(8):1455-1462.
344. Ting FS, Kwok AK. Treatment of epiretinal membrane: an update. *Hong Kong medical journal = Xianggang yi xue za zhi*. 2005;11(6):496-502.
345. Pournaras CJ, Donati G, Brazitikos PD, Kapetanios AD, Derekliis DL, Stangos NT. Macular epiretinal membranes. *Seminars in ophthalmology*. 2000;15(2):100-107.
346. Veverka KK, Hatt SR, Leske DA, et al. Prevalence and Associations of Central-Peripheral Rivalry-Type Diplopia in Patients With Epiretinal Membrane. *JAMA ophthalmology*. 2017;135(12):1303-1309.

347. Veverka KK, Hatt SR, Leske DA, Brown WL, Iezzi R, Jr., Holmes JM. Causes of Diplopia in Patients With Epiretinal Membranes. *American journal of ophthalmology*. 2017;179:39-45.
348. Hatt SR, Leske DA, Klaehn LD, Kramer AM, Iezzi R, Jr., Holmes JM. Treatment for central-peripheral rivalry-type diplopia ("dragged-fovea diplopia syndrome"). *American journal of ophthalmology*. 2019.
349. Silverberg M, Schuler E, Veronneau-Troutman S, Wald K, Schlossman A, Medow N. Nonsurgical management of binocular diplopia induced by macular pathology. *Arch Ophthalmol*. 1999;117(7):900-903.
350. Iacobucci IL, Furr BA, Archer SM. Management of binocular diplopia due to maculopathy with combined bangerter filter and fresnel prism. *The American orthoptic journal*. 2009;59:93-97.
351. De Pool ME, Iezzi R, Jr., Hatt SR, Leske DA, Holmes JM. The Double-edged Sword of Epiretinal Membrane Surgery: Improving versus Inducing Diplopia. *IOVS*. 2018;59.
352. Wan MJ, Hunter DG. Complications of strabismus surgery: incidence and risk factors. *Seminars in ophthalmology*. 2014;29(5-6):421-428.
353. Bradbury JA, Taylor RH. Severe complications of strabismus surgery. *Journal of AAPOS : the official publication of the American Association for Pediatric Ophthalmology and Strabismus*. 2013;17(1):59-63.
354. Escardo-Paton JA, Harrad RA. Duration of conjunctival redness following adult strabismus surgery. *Journal of AAPOS : the official publication of the American Association for Pediatric Ophthalmology and Strabismus*. 2009;13(6):583-586.
355. Tessler HH, Urist MJ. Corneal dellen in the limbal approach to rectus muscle surgery. *The British journal of ophthalmology*. 1975;59(7):377-379.
356. Fresina M, Campos EC. Corneal 'dellen' as a complication of strabismus surgery. *Eye (Lond)*. 2009;23(1):161-163.
357. Espinoza GM, Lueder GT. Conjunctival pyogenic granulomas after strabismus surgery. *Ophthalmology*. 2005;112(7):1283-1286.
358. Guadilla AM, de Liano PG, Merino P, Franco G. Conjunctival cysts as a complication after strabismus surgery. *Journal of pediatric ophthalmology and strabismus*. 2011;48(5):298-300.
359. Simon JW, Lininger LL, Scheraga JL. Recognized scleral perforation during eye muscle surgery: incidence and sequelae. *J Pediatr Ophthalmol Strabismus*. 1992;29(5):273-275.
360. Dang Y, Racu C, Isenberg SJ. Scleral penetrations and perforations in strabismus surgery and associated risk factors. *Journal of AAPOS : the official publication of the American Association for Pediatric Ophthalmology and Strabismus*. 2004;8(4):325-331.
361. Noel LP, Bloom JN, Clarke WN, Bawazeer A. Retinal perforation in strabismus surgery. *Journal of pediatric ophthalmology and strabismus*. 1997;34(2):115-117.
362. Morris RJ, Rosen PH, Fells P. Incidence of inadvertent globe perforation during strabismus surgery. *The British journal of ophthalmology*. 1990;74(8):490-493.
363. Apt L, Isenberg S, Gaffney WL. The oculocardiac reflex in strabismus surgery. *American journal of ophthalmology*. 1973;76(4):533-536.
364. Min SW, Hwang JM. The incidence of asystole in patients undergoing strabismus surgery. *Eye (Lond)*. 2009;23(4):864-866.
365. Ing MR. Infection following strabismus surgery. *Ophthalmic surgery*. 1991;22(1):41-43.

366. Kivlin JD, Wilson ME, Jr. Periocular infection after strabismus surgery. The Periocular Infection Study Group. *Journal of pediatric ophthalmology and strabismus*. 1995;32(1):42-49.
367. Mittelman D, Bakos IM. The role of retinal cryopexy in the management of experimental perforation of the eye during strabismus surgery. *Journal of pediatric ophthalmology and strabismus*. 1984;21(5):186-189.
368. Parks MM. The weakening surgical procedures for eliminating overaction of the inferior oblique muscle. *American journal of ophthalmology*. 1972;73(1):107-122.
369. Todd B, Sullivan TJ, Gole GA. Delayed orbital hemorrhage after routine strabismus surgery. *American journal of ophthalmology*. 2001;131(6):818-819.
370. Ares C, Superstein R. Retrobulbar hemorrhage following strabismus surgery. *Journal of AAPOS : the official publication of the American Association for Pediatric Ophthalmology and Strabismus*. 2006;10(6):594-595.
371. Shen E, Porco T, Rutar T. Errors in strabismus surgery. *JAMA ophthalmology*. 2013;131(1):75-79.
372. Eke T. Preoperative Preparation and Anesthesia for Trabeculectomy. *Journal of current glaucoma practice*. 2016;10(1):21-35.
373. Kemp PS, Larson SA, Drack AV. Strabismus surgery in patients receiving warfarin anticoagulation. *Journal of AAPOS : the official publication of the American Association for Pediatric Ophthalmology and Strabismus*. 2014;18(1):84-86.
374. Nihalani BR, Hunter DG. Adjustable suture strabismus surgery. *Eye (Lond)*. 2011;25(10):1262-1276.
375. Saxena R, Singh D, Chandra A, Sharma P. Adjustable anterior and nasal transposition of inferior oblique muscle in case of torsional diplopia in superior oblique palsy. *Indian Journal of Clinical and Experimental Ophthalmology*. 2015;1(2):104-106.
376. Yim HB, Biglan AW, Cronin TH. Graded partial tenotomy of vertical rectus muscles for treatment of hypertropia. *Transactions of the American Ophthalmological Society*. 2004;102:169-175; discussion 175-166.
377. Singh J, Choi CS, Bahl R, Archer SM. Partial tendon recession for small-angle vertical strabismus. *Journal of AAPOS : the official publication of the American Association for Pediatric Ophthalmology and Strabismus*. 2016;20(5):392-395.
378. Rowe FJ, Noonan CP. Botulinum toxin for the treatment of strabismus. *The Cochrane database of systematic reviews*. 2017;3:CD006499.
379. Simon JW. Complications of strabismus surgery. *Current opinion in ophthalmology*. 2010;21(5):361-366.
380. Al-Haddad C, Abdul Fattah M. Slipped extraocular muscles: characteristics and surgical outcomes. *Canadian journal of ophthalmology Journal canadien d'ophtalmologie*. 2017;52(1):42-47.
381. Parks MM, Bloom JN. The "slipped" muscle. *Ophthalmology*. 1979;86(8):1389-1396.
382. Olitsky SE, Juneja RG. Orbital hemorrhage after the administration of sub-Tenon's infusion anesthesia. *Ophthalmic Surg Lasers*. 1997;28(2):145-146.