

Clinical Practice Guideline: Evaluation of the Neck Mass in Adults

Otolaryngology—
 Head and Neck Surgery
 2017, Vol. 157(2S) S1–S30
 © American Academy of
 Otolaryngology—Head and Neck
 Surgery Foundation 2017
 Reprints and permission:
sagepub.com/journalsPermissions.nav
 DOI: 10.1177/0194599817722550
<http://otojournal.org>



Melissa A. Pynnonen, MD, MSc¹, M. Boyd Gillespie, MD, MSc², Benjamin Roman, MD, MSHP³, Richard M. Rosenfeld, MD, MPH⁴, David E. Tunkel, MD⁵, Laura Bontempo, MD, MEd⁶, Itzhak Brook, MD, MSc⁷, Davoren Ann Chick, MD¹, Maria Colandrea, DNP^{8,9}, Sandra A. Finestone, PsyD¹⁰, Jason C. Fowler, PA-C¹¹, Christopher C. Griffith, MD, PhD¹², Zeb Henson, MD¹³, Corinna Levine, MD, MPH¹⁴, Vikas Mehta, MD, MPH¹⁵, Andrew Salama, DDS, MD¹⁶, Joseph Scharpf, MD¹⁷, Deborah R. Shatzkes, MD¹⁸, Wendy B. Stern, MD¹⁹, Jay S. Youngerman, MD²⁰, and Maureen D. Corrigan²¹

Sponsorships or competing interests that may be relevant to content are disclosed at the end of this article.

Abstract

Objective. Neck masses are common in adults, but often the underlying etiology is not easily identifiable. While infections cause most of the neck masses in children, most persistent neck masses in adults are neoplasms. Malignant neoplasms far exceed any other etiology of adult neck mass. Importantly, an asymptomatic neck mass may be the initial or only clinically apparent manifestation of head and neck cancer, such as squamous cell carcinoma (HNSCC), lymphoma, thyroid, or salivary gland cancer. Evidence suggests that a neck mass in the adult patient should be considered malignant until proven otherwise. Timely diagnosis of a neck mass due to metastatic HNSCC is paramount because delayed diagnosis directly affects tumor stage and worsens prognosis. Unfortunately, despite substantial advances in testing modalities over the last few decades, diagnostic delays are common. Currently, there is only 1 evidence-based clinical practice guideline to assist clinicians in evaluating an adult with a neck mass. Additionally, much of the available information is fragmented, disorganized, or focused on specific etiologies. In addition, although there is literature related to the diagnostic accuracy of individual tests, there is little guidance about rational sequencing of tests in the course of clinical care. This guideline strives to bring a coherent, evidence-based, multidisciplinary perspective to the evaluation of the neck mass with the intention to facilitate prompt diagnosis and enhance patient outcomes.

Purpose. The primary purpose of this guideline is to promote the efficient, effective, and accurate diagnostic workup of neck masses to ensure that adults with potentially malignant disease receive prompt diagnosis and intervention to optimize outcomes. Specific goals include reducing delays in diagnosis of HNSCC; promoting appropriate testing, including imaging, pathologic evaluation, and empiric medical therapies; reduc-

ing inappropriate testing; and promoting appropriate physical examination when cancer is suspected. The target patient for this guideline is anyone ≥ 18 years old with a neck mass. The target clinician for this guideline is anyone who may be the first clinician whom a patient with a neck mass encounters. This includes clinicians in primary care, dentistry, and emergency medicine, as well as pathologists and radiologists who have a role in diagnosing neck masses. This guideline does not apply to children. This guideline addresses the initial broad differential diagnosis of a neck mass in an adult. However, the intention is only to assist the clinician with a basic understanding of the broad array of possible entities. The intention is not to direct management of a neck mass known to originate from thyroid, salivary gland, mandibular, or dental pathology as management recommendations for these etiologies already exist. This guideline also does not address the subsequent management of specific pathologic entities, as treatment recommendations for benign and malignant neck masses can be found elsewhere. Instead, this guideline is restricted to addressing the appropriate work-up of an adult patient with a neck mass that may be malignant in order to expedite diagnosis and referral to a head and neck cancer specialist. The Guideline Development Group sought to craft a set of actionable statements relevant to diagnostic decisions made by a clinician in the workup of an adult patient with a neck mass. Furthermore, where possible, the Guideline Development Group incorporated evidence to promote high-quality and cost-effective care.

Action Statements. The development group made a *strong recommendation* that clinicians should order a neck computed tomography (or magnetic resonance imaging) with contrast for patients with a neck mass deemed at increased risk for malignancy.

The development group made the following *recommendations*: (1) Clinicians should identify patients with a neck mass who are at increased risk for malignancy because the patient lacks a history of infectious etiology and the mass has been present

for ≥ 2 weeks without significant fluctuation or the mass is of uncertain duration. (2) Clinicians should identify patients with a neck mass who are at increased risk for malignancy based on ≥ 1 of these physical examination characteristics: fixation to adjacent tissues, firm consistency, size > 1.5 cm, or ulceration of overlying skin. (3) Clinicians should conduct an initial history and physical examination for patients with a neck mass to identify those with other suspicious findings that represent an increased risk for malignancy. (4) For patients with a neck mass who are not at increased risk for malignancy, clinicians or their designees should advise patients of criteria that would trigger the need for additional evaluation. Clinicians or their designees should also document a plan for follow-up to assess resolution or final diagnosis. (5) For patients with a neck mass who are deemed at increased risk for malignancy, clinicians or their designees should explain to the patient the significance of being at increased risk and explain any recommended diagnostic tests. (6) Clinicians should perform, or refer the patient to a clinician who can perform, a targeted physical examination (including visualizing the mucosa of the larynx, base of tongue, and pharynx) for patients with a neck mass deemed at increased risk for malignancy. (7) Clinicians should perform fine-needle aspiration (FNA) instead of open biopsy, or refer the patient to someone who can perform FNA, for patients with a neck mass deemed at increased risk for malignancy when the diagnosis of the neck mass remains uncertain. (8) For patients with a neck mass deemed at increased risk for malignancy, clinicians should continue evaluation of patients with a cystic neck mass, as determined by FNA or imaging studies, until a diagnosis is obtained and should not assume that the mass is benign. (9) Clinicians should obtain additional ancillary tests based on the patient's history and physical examination when a patient with a neck mass is deemed at increased risk for malignancy who does not have a diagnosis after FNA and imaging. (10) Clinicians should recommend evaluation of the upper aerodigestive tract under anesthesia, before open biopsy, for patients with a neck mass deemed at increased risk for malignancy and without a diagnosis or primary site identified with FNA, imaging, and/or ancillary tests.

The development group *recommended against* clinicians routinely prescribing antibiotic therapy for patients with a neck mass unless there are signs and symptoms of bacterial infection.

Keywords

neck mass, squamous cell carcinoma, neck cancer, clinical practice guideline

Received April 19, 2017; revised June 13, 2017; accepted July 5, 2017.

Neck masses are common in adults, but often the underlying etiology is not easily identifiable. While infections cause most of the neck masses in children, most persistent neck masses in adults are neoplasms. Malignant neoplasms far exceed any other etiology of adult neck mass.¹⁻³

As used in this guideline, a neck mass is defined as an abnormal lesion (congenital or acquired) that is visible, palpable, or seen on an imaging study. The Guideline Development Group (GDG) further qualified neck masses as any mass below the mandible, above the clavicle, and deep to the skin, although it may involve the overlying skin secondarily. Neck masses may develop from infectious, inflammatory, congenital, traumatic, benign, or malignant neoplastic processes. Importantly, an asymptomatic neck mass may be the initial or only clinically apparent manifestation of head and neck cancer, such as squamous cell carcinoma (HNSCC), lymphoma, thyroid, or salivary gland cancer. Evidence suggests that a neck mass in the adult patient should be considered malignant until proven otherwise.¹⁻⁸

Timely diagnosis of a neck mass due to metastatic HNSCC is paramount because delayed diagnosis directly affects tumor stage and worsens prognosis.⁹⁻¹¹ Unfortunately, despite substantial advances in testing modalities over the last few decades, diagnostic delays are common. Forty years ago, patients with a neck mass experienced an average of a 5- to 6-month delay from the time of initial presentation to the diagnosis of malignancy.¹² Today, studies continue to report delays as long as 3 to 6 months.¹³⁻¹⁵

The epidemiology and clinical presentation of mucosal HNSCC have changed recently. Coupled with the substantial morbidity and mortality of this disease, metastatic mucosal HNSCC is the focus of this guideline. However, a malignant neck mass can result from other disease entities, including lymphoma, skin, thyroid, and salivary gland cancer. The workup outlined in the action statements of this guideline may be applied to any cancer that has metastasized to the neck without an obvious primary.

Mucosal HNSCC may originate in the oral cavity, oropharynx, hypopharynx, nasopharynx, or larynx. Occult metastatic spread from the primary cancer to the regional lymph nodes and continued tumor growth within the lymph nodes result in a neck mass. In 2016, an estimated 62,000 people will be diagnosed with HNSCC.¹⁶ The incidence of HNSCC of the oropharynx in

¹University of Michigan, Ann Arbor, Michigan, USA; ²University of Tennessee Health Science Center, Memphis, Tennessee, USA; ³Memorial Sloan Kettering Cancer Center, New York, New York, USA; ⁴SUNY Downstate Medical Center, Long Island College Hospital, New York, New York, USA; ⁵Johns Hopkins Medicine, Baltimore, Maryland, USA; ⁶University of Maryland School of Medicine, Baltimore, Maryland, USA; ⁷Georgetown University, Washington DC, USA; ⁸Veterans Affairs Medical Center, Durham, North Carolina, USA; ⁹Duke University School of Nursing, Durham, North Carolina, USA; ¹⁰Consumers United for Evidence-Based Healthcare, Baltimore, Maryland, USA; ¹¹Gannon University, Erie, Pennsylvania, USA; ¹²Emory University, Atlanta, Georgia, USA; ¹³University of Mississippi Medical Center, Jackson, Mississippi, USA; ¹⁴University of Miami, Miami, Florida, USA; ¹⁵Louisiana State University, Shreveport, Louisiana, USA; ¹⁶Boston University, Boston, Massachusetts, USA; ¹⁷Cleveland Clinic, Cleveland, Ohio, USA; ¹⁸Hofstra Northwell School of Medicine, Lenox Hill Hospital, New York, New York, USA; ¹⁹Southcoast Hospital, North Dartmouth, Massachusetts, USA; ²⁰Long Island ENT Associates PC, New York, New York, USA; ²¹American Academy of Otolaryngology—Head and Neck Surgery Foundation, Alexandria, Virginia, USA.

Corresponding Author:

Melissa A. Pynnonen, MD, MSc, University of Michigan, 1904 Taubman Center, 1500 E Medical Center Drive, Ann Arbor, MI 48109-5312, USA.
Email: pynnonen@umich.edu

particular is on the rise—in part as a consequence of infection with the human papilloma virus (HPV). For these reasons, expediting the diagnosis of HNSCC is the principal quality improvement opportunity of this guideline.

The incidence of HPV-positive HNSCC of the oropharynx has more than doubled, whereas the incidence of HPV-negative cancers has decreased by half.¹⁷ The rate of HPV-positive HNSCC of the oropharynx (tonsil and base of tongue) is rising so rapidly that by 2020 the incidence of HPV-positive oropharyngeal cancer is estimated to exceed that of HPV-positive uterine cervical cancer.^{18,19} Patients affected with HPV-positive oropharyngeal HNSCC often present with neck metastasis without an obvious primary malignancy. Two features of HPV-positive HNSCC may contribute to delayed diagnosis. First, as compared with patients with traditional HNSCC that is HPV-negative, patients with HPV-positive tumors are younger and often lack tobacco and alcohol exposure, the 2 most common classic risk factors. Second, because cervical metastases from HPV-positive HNSCC may be cystic, they are often mistaken for branchial cleft cysts, further contributing to delay in diagnosis.^{20,21}

Currently, there is only 1 evidence-based clinical practice guideline to assist clinicians in evaluating an adult with a neck mass.⁸ Additionally, much of the available information is fragmented, disorganized, or focused on specific etiologies. In addition, although there is literature related to the diagnostic accuracy of individual tests, there is little guidance about rational sequencing of tests in the course of clinical care. This guideline strives to bring a coherent, evidence-based, multi-disciplinary perspective to the evaluation of the neck mass with the intention to facilitate prompt diagnosis and enhance patient outcomes.

Guideline Purpose

The primary purpose of this guideline is to promote the efficient, effective, and accurate diagnostic workup of neck masses to ensure that adults with potentially malignant disease receive prompt diagnosis and intervention to optimize outcomes. Specific goals include reducing delays in diagnosis of HNSCC; promoting appropriate testing, including imaging, pathologic evaluation, and empiric medical therapies; reducing inappropriate testing; and promoting appropriate physical examination when cancer is suspected.

The target patient for this guideline is anyone ≥ 18 years old with a neck mass. The target clinician for this guideline is anyone who may be the first clinician whom a patient with a neck mass encounters. This includes clinicians in primary care, dentistry, and emergency medicine, as well as pathologists and radiologists who have a role in diagnosing neck masses. This guideline does not apply to children.

This guideline addresses the initial broad differential diagnosis of a neck mass in an adult. However, the intention is only to assist the clinician with a basic understanding of the broad array of possible entities. The intention is not to direct management of a neck mass known to originate from thyroid, salivary gland, mandibular, or dental pathology, as management recommendations for these etiologies already exist.^{22,23} This guideline also does not address the subsequent management of specific

pathologic entities, as treatment recommendations for benign and malignant neck masses can be found elsewhere.^{23,24} Instead, this guideline is restricted to addressing the appropriate workup of an adult patient with a neck mass that may be malignant, to expedite diagnosis and referral to a head and neck cancer specialist.

The GDG sought to craft a set of actionable statements relevant to diagnostic decisions made by a clinician in the workup of an adult patient with a neck mass. Furthermore, where possible, the GDG incorporated evidence to promote high-quality and cost-effective care.

Health Care Burden

Epidemiology

Many adults develop an inflammatory neck mass associated with viral or bacterial respiratory infections. However, inflammatory cervical lymphadenopathy is most often self-limited, resolving within weeks, and as such, patients with inflammatory cervical lymphadenopathy typically do not present for evaluation. For this reason, we lack data on the overall incidence of adult neck mass.

We also lack specific data on the incidence of persistent neck mass—a mass that lasts longer than expected for a self-limited problem.²⁵ We can crudely estimate the incidence from 2 statistics. First, about half of the 62,000 cases of head and neck cancer diagnosed in 2016 will present with a neck mass, suggesting that 30,000 patients will present with a malignant neck mass (www.cancer.org). Second, the fact that about half of all adult neck masses are malignant suggests that an additional 30,000 patients will present with a persistent neck mass of benign etiology.^{4,26} Although a malignant neck mass in an adult is most often due to HNSCC, it may also be due to lymphoma, thyroid cancer, salivary gland malignancy, skin cancer, or metastasis from distant sites.

Human Papillomavirus

HNSCC has a worldwide annual incidence of 550,000 cases, representing 5% of all newly diagnosed cancers.²⁷ In recent decades, people in developed countries have reduced their tobacco consumption, resulting in a lower incidence of HNSCC of the oral cavity, larynx, and hypopharynx.²⁸ Unfortunately, these gains have been offset by a precipitous increase in HNSCC of the oropharynx (tonsil and base of tongue). The rise in oropharyngeal HNSCC is attributed to increasing prevalence of high-risk HPV infection, specifically HPV subtype 16, which is estimated to be present in the oropharynx of 1% of sexually active adults at any given time.¹⁹ From 1988 to 2004, the US population experienced a 225% increase in HPV-positive oropharyngeal HNSCC.¹⁷ Compared with HPV-negative HNSCC, HPV-positive HNSCC is associated with younger age, male sex, more oral and vaginal sexual partners, better dentition, less or no tobacco exposure, less alcohol consumption, greater marijuana use, higher education level, and higher socioeconomic status.²⁹ Over 70% of new cases of oropharyngeal HNSCC are attributable to HPV subtype 16. If current trends continue, the incidence of HPV-positive oropharyngeal HNSCC will surpass that of HPV-positive cancer of the uterine cervix by 2020 and constitute 50% of all HNSCC by

2030.¹⁷ As a result, many experts believe that there is an epidemic of HPV-positive oropharyngeal HNSCC.³⁰

Patients with HPV-positive HNSCC commonly present with a neck mass as the only symptom of concern.^{31,32} Unfortunately, clinicians may consider these patients at low risk for cancer due to their younger age or lack of significant tobacco and alcohol exposure, resulting in delayed cancer diagnosis.³³

Diagnostic Delay

An adult patient with a neck mass who experiences delayed diagnosis of metastatic cancer may suffer progression of disease with increased mortality and poorer functional outcome.¹⁰ Occult tumor spread from a primary mucosal malignancy to the regional lymph nodes indicates progression of disease, which requires timely management to prevent a more advanced cancer stage.

Among patients with HNSCC who present with neck mass, diagnostic delay is common. Delays in diagnosis of 3 to 6 months have been reported,¹²⁻¹⁵ which is particularly disappointing knowing that delays as short as 2 months are associated with worse functional outcomes,³⁴⁻³⁶ lower quality of life,³⁷⁻⁴² cancer recurrence, and death.⁴³⁻⁴⁵

Delay in diagnosis may result from patient delay or professional delay. Patient delay is defined as delay from the onset of initial symptoms until clinical evaluation. Factors contributing to patient delay include illiteracy, rural location, and low socioeconomic status.^{46,47} Professional delay is defined as delay from the initial evaluation until definitive diagnosis. A recent study found that most patients with a neck mass due to metastatic HNSCC experienced professional delays, including delayed referral by the primary clinician, delayed scheduling by the consulting physician, and lengthy waits for diagnostic tests.⁴⁸ In addition to scheduling delays, delay for inappropriate antibiotic therapy is common, affecting 20% to 70% of patients.^{48,49} Guidance about the appropriate use of antibiotics for the neck mass and the avoidance of unnecessary antibiotics in the setting of a neck mass are additional quality improvement opportunities of this guideline.

Biopsy

Fine-needle aspiration (FNA), rather than open biopsy, is the preferred method for cancer diagnosis in a neck mass. Open biopsy is suboptimal because it risks tumor seeding and local and regional tumor recurrence.^{7,50,51} Although we lack data on the frequency of open biopsy, comprehensive cancer centers report that patients are regularly referred for cancer care following inappropriate open neck biopsy.^{52,53} Two large academic tertiary referral head and neck cancer centers reported 45 patients evaluated over a 14-year period and 94 patients evaluated for >13 consecutive years with HNSCC who had undergone open neck biopsy.^{52,53} Most of the open biopsies, 100% and 87%, respectively, occurred in patients with HPV-positive HNSCC. Presumably this occurs because cervical metastases from HPV-positive HNSCC often have a cystic appearance on imaging and are thus mistaken for a benign cyst or abscess.^{54,55}

HNSCC patients with a neck mass violated by inappropriate open biopsy often require more aggressive surgery and/or chemotherapy and radiation to achieve levels of disease control comparable to those of historical or concurrent controls.^{52,53} One study found that 7% of patients who had undergone open biopsy had tumor deposits in the dermal scars at the time of subsequent neck dissection.⁵² Greater recognition that HPV-positive HNSCC often has a cystic appearance on imaging, coupled with appreciation of the role of FNA in cystic masses, may reduce diagnostic delays, complications, and cost of inappropriate open biopsy of the adult neck mass.

Methods

General Methods

This guideline was developed with an explicit and transparent a priori protocol for creating actionable statements based on supporting evidence and the associated balance of benefit and harm as outlined in the third edition of the American Academy of Otolaryngology—Head and Neck Surgery Foundation (AAO-HNSF) guideline development manual.⁵⁶ The GDG consisted of 21 panel members representing experts in advanced practice nursing, clinical pathology, consumer advocacy, emergency medicine, general practice medicine, general surgery, head and neck surgery and oncology, otolaryngology, oral and maxillofacial surgery, physician assistants, and radiology.

Literature Search

The recommendations in this clinical practice guideline are based on systematic reviews identified by a professional information specialist using an explicit search strategy. Additional background evidence included randomized controlled trials and observational studies, as needed, to supplement the systematic reviews or to fill gaps when a review was not available. An information specialist conducted 2 systematic literature searches from December 2015 through February 2016 using a validated filter strategy to identify clinical practice guidelines, systematic reviews, randomized controlled trials, and comparative studies. The following search terms were used:

("Neck"[mh] AND "Cysts"[mh]) OR ("neck mass"[tiab] OR "neck masses"[tiab] OR "neck lesion"[tiab] OR "neck lesions"[tiab] OR "neck cyst"[tiab] OR "neck cysts"[tiab] OR "neck lump"[tiab] OR "neck lumps"[tiab] OR "neck swelling"[tiab] OR "cystic neck"[tiab] OR "lateral adenopathy"[tiab] OR "cervical lymphadenopathy"[tiab] OR "salivary gland lesion"[tiab] OR "salivary gland lesions"[tiab] OR "neck growth"[tiab] OR "neck growths"[tiab] OR "neck abscess"[tiab] OR "neck abscesses"[tiab]) AND ("Diagnostic Imaging"[mh] OR "Diagnosis, differential"[mh] OR "differential diagnosis"[tiab] OR "diagnosis"[Subheading] OR "Biopsy"[mh] OR "fine needle"[tiab] OR FNAB[tiab] OR imaging[tiab] OR measurement[tiab] OR examination[tiab] OR assessment[tiab] OR evaluation[tiab] OR diagnosis[tiab] OR "Delayed Diagnosis"[mh] OR "delayed

diagnosis"[tiab] OR "diagnostic delay"[tiab] OR misdiagnosis[tiab] OR misdiagnosed[tiab] OR "missed diagnosis"[tiab] OR workup[tiab] OR "work-up"[tiab] OR "Referral and Consultation"[mh] OR referral[tiab] OR referrals[tiab] OR identification[tiab]) AND ("1980/01/01"[PDAT] : "2016/12/31"[PDAT]) NOT ("child"[mh] OR child[tiab] OR childhood[tiab] OR children[tiab] OR "pediatrics"[Mh] OR pediatric[tiab] OR paediatric[tiab] OR "infant"[Mh] OR infant[tiab] OR infants[tiab] OR infantile[tiab] OR prenatal[tiab] OR perinatal[tiab] OR fetal[tiab]) AND ("Practice Guideline"[ptyp] AND systematic[sb] AND (Randomized Controlled Trial[ptyp] OR randomized[tiab] OR randomised[tiab]); ("Head and Neck Neoplasms/epidemiology"[Mesh] OR "Head and Neck Neoplasms/etiology"[mh] OR "Head and Neck Neoplasms/diagnosis"[mh]) AND ("Papillomaviridae"[Mesh] OR "human papillomavirus"[tiab] OR hpv[tiab] OR "HPV-mediated"[tiab] OR "HPV-associated"[tiab] OR "HPV-related"[tiab]) AND ("1980/01/01"[PDAT] : "2016/12/31"[PDAT]) NOT ("child"[mh] OR child[tiab] OR childhood[tiab] OR children[tiab] OR "pediatrics"[Mh] OR pediatric[tiab] OR paediatric[tiab] OR "infant"[Mh] OR infant[tiab] OR infants[tiab] OR infantile[tiab] OR prenatal[tiab] OR perinatal[tiab] OR fetal[tiab]) AND "Practice Guideline"[ptyp] AND systematic[sb] (Randomized Controlled Trial[ptyp] OR randomized[tiab] OR randomised[tiab]) AND (Comparative Study[ptyp] OR comparative[tiab])

The English-language searches were performed in multiple databases, including PubMed (MEDLINE), EMBASE, CINAHL, Cochrane Library, National Guideline Clearinghouse, NICE UK, and CMA Infobase (Canada). In certain instances, targeted searches for lower-level evidence were performed to address gaps from the systematic searches identified in writing the guideline from April 2016 through November 2016.

1. The initial search for clinical practice guidelines identified 11 guidelines. After removal of duplicates and irrelevant references, the total was 6 guidelines. Quality criteria for including guidelines were (a) an explicit scope and purpose, (b) multidisciplinary stakeholder involvement, (c) systematic literature review, (d) explicit system for ranking evidence, and (e) explicit system for linking evidence to recommendations. The final data set retained 3 guidelines that met inclusion criteria.
2. The initial search for systematic reviews identified 103 systematic reviews or meta-analyses. After removal of duplicates and irrelevant references, the total was 27 articles. Quality criteria for including reviews were (a) relevance to the guideline topic, (b) clear objective and methodology, (c) explicit search strategy, and (d) valid data extraction methods. The final data set retained was 10 systematic reviews or meta-analyses that met inclusion criteria.
3. The initial search for randomized controlled trials identified 20 trials. After removal of duplicates and irrelevant references, the total was 14 articles. Quality criteria for including randomized controlled trials were (a) relevance to the guideline topic, (b) publication in a peer-reviewed journal, and (c) clear methodology with randomized allocation to treatment groups. The total final data set retained 6 randomized controlled trials that met inclusion criteria.
4. The initial search for comparative studies identified 143 studies. After removal of duplicates and irrelevant references, the total was 140 articles. The quality criterion for including comparative studies was relevance to the guideline topic. The total final data set retained 51 comparative studies that met inclusion criteria.

In a series of conference calls, the GDG defined the scope and objectives of the proposed guideline. During the 12 months devoted to guideline development ending in August 2016, the GDG met twice, with in-person meetings following the format previously described,⁵⁶ with use of decision support software (BRIDGE-Wiz; Yale Center for Medical Informatics, New Haven, Connecticut) to facilitate the creation of actionable recommendations and evidence profiles.⁵⁷ Internal electronic review and feedback on each guideline draft were used to ensure accuracy of content and consistency with standardized criteria for reporting CPGs.⁵⁸

AAO-HNSF staff used the Guideline Implementability Appraisal and Extractor to appraise adherence of the draft guideline to methodological standards, to improve clarity of recommendations, and to predict potential obstacles to implementation.⁵⁹ Guideline panel members received summary appraisals in September 2016 and modified an advanced draft of the guideline.

The final guideline draft underwent extensive external peer review, including a period for open public comment. All comments received were compiled and reviewed by the panel's chair, and a modified version of the guideline was distributed and approved by the GDG. The recommendations contained in the guideline are based on the best available data published through April 2016. Where data were lacking, a combination of clinical experience and expert consensus was used. A scheduled review process will occur at 5 years from publication or sooner if new compelling evidence warrants earlier consideration.

Classification of Evidence-Based Statements

Guidelines are intended to reduce inappropriate variations in clinical care, produce optimal health outcomes for patients, and minimize harm. The evidence-based approach to guideline development requires that the evidence supporting a policy be identified, appraised, and summarized and that an explicit link between evidence and statements be defined. Evidence-based statements reflect both the *quality of evidence* and the *balance of benefit and harm* that is anticipated when

Table 1. Strength of Action Terms in Guideline Statements and Implied Levels of Obligation.

| Strength | Definition | Implied Obligation |
|-----------------------|--|---|
| Strong recommendation | A strong recommendation means that the benefits of the recommended approach clearly exceed the harms (or, in the case of a strong negative recommendation, that the harms clearly exceed the benefits) and that the quality of the supporting evidence is high (grade A or B). ^a In some clearly identified circumstances, strong recommendations may be made based on lesser evidence when high-quality evidence is impossible to obtain and the anticipated benefits strongly outweigh the harms. | Clinicians should follow a strong recommendation unless a clear and compelling rationale for an alternative approach is present. |
| Recommendation | A recommendation means that the benefits exceed the harms (or, in the case of a negative recommendation, that the harms exceed the benefits), but the quality of evidence is not as high (grade B or C). ^a In some clearly identified circumstances, recommendations may be made based on lesser evidence when high-quality evidence is impossible to obtain and the anticipated benefits outweigh the harms. | Clinicians should also generally follow a recommendation but should remain alert to new information and sensitive to patient preferences. |
| Option | An option means that either the quality of evidence is suspect (grade D) ^a or well-done studies (grade A, B, or C) ^a show little clear advantage to one approach versus another. | Clinicians should be flexible in their decision making regarding appropriate practice, although they may set bounds on alternatives; patient preference should have a substantial influencing role. |

^aSee Table 3 for definitions of evidence grades.

the statement is followed. The definitions for evidence-based statements are listed in **Tables 1** and **2**.

Guidelines are never intended to supersede professional judgment; rather, they may be viewed as a relative constraint on individual clinician discretion in a particular clinical circumstance. Less frequent practice variation is expected for a strong recommendation than what might be expected with a recommendation. Options offer the most opportunity for practice variability.⁶⁰ Clinicians should always act and decide in a way that they believe will best serve their patients' interests and needs, regardless of guideline recommendations. Guidelines represent the best judgment of a team of experienced clinicians and methodologists addressing the scientific evidence for a particular topic.⁶¹

Making recommendations about health practices involves value judgments on the desirability of various outcomes associated with management options. Values applied by the GDG sought to minimize harm and diminish unnecessary and inappropriate therapy. A major goal of the panel was to be transparent and explicit about how values were applied and to document the process.

Financial Disclosure and Conflicts of Interest

The cost of developing this guideline, including travel expenses of all panel members, was covered in full by the AAO-HNSF. Potential conflicts of interest for all panel members in the past 5 years were compiled and distributed before the first conference call and were updated at each subsequent call and in-person meeting. After review and discussion of these disclosures,⁶² the panel concluded that individuals with potential conflicts could remain on the panel if they (1) reminded the panel of potential conflicts before any related

discussion, (2) recused themselves from a related discussion if asked by the panel, and (3) agreed not to discuss any aspect of the guideline with industry before publication. Last, panelists were reminded that conflicts of interest extend beyond financial relationships and may include personal experiences, how a participant earns a living, and the participant's previously established "stake" in an issue.⁶³

Guideline Key Action Statements

Each evidence-based statement is organized in a similar fashion: a key action statement (KAS) in bold, followed by the strength of the recommendation in italics. Each KAS is followed by an "action statement profile" that explicitly states the quality improvement opportunity, aggregate evidence quality, level of confidence in evidence (high, medium, low), benefit, harms, risks, costs, and a benefits-harm assessment. Additionally, there are statements of any value judgments, the role of patient preferences, clarification of any intentional vagueness by the panel, exceptions to the statement, any differences of opinion, and a repeat statement of the strength of the recommendation. Several paragraphs subsequently discuss the evidence base supporting the statement. An overview of each evidence-based statement in this guideline can be found in **Table 3**, and the relationship among the statements is depicted in **Figure 1**.

The role of patient preferences in making decisions deserves further clarification. The role for patient preference depends on the clinical evidence behind each statement. Statements with clinical evidence that clearly demonstrates a benefit have less of a role for patient preference when compared with statements with a less convincing evidence base. Although some statements may have little room for patient

Table 2. Aggregate Grades of Evidence by Question Type.^a

| Grade | CEBM Level | Treatment | Harm | Diagnosis | Prognosis |
|-------|------------|---|--|---|---|
| A | 1 | Systematic review ^b of randomized trials | Systematic review ^b of randomized trials, nested case-control studies, or observational studies with dramatic effect ^b | Systematic review ^b of cross-sectional studies with consistently applied reference standard and blinding | Systematic review ^b of inception cohort studies ^c |
| B | 2 | Randomized trials or observational studies with dramatic effects or highly consistent evidence | Randomized trials or observational studies with dramatic effects or highly consistent evidence | Cross-sectional studies with consistently applied reference standard and blinding | Inception cohort studies ^c |
| C | 3-4 | Nonrandomized or historically controlled studies, including case-control and observational studies | Nonrandomized controlled cohort or follow-up study (postmarketing surveillance) with sufficient numbers to rule out a common harm; case-series, case-control, or historically controlled studies | Nonconsecutive studies, case-control studies, or studies with poor, nonindependent, or inconsistently applied reference standards | Cohort study, control arm of a randomized trial, case series, or case-control studies; poor quality prognostic cohort study |
| D | 5 | Case reports, mechanism-based reasoning, or reasoning from first principles | | | |
| X | n/a | Exceptional situations where validating studies cannot be performed and there is a clear preponderance of benefit over harm | | | |

Abbreviation: CEBM, Oxford Centre for Evidence-Based Medicine.

^aAdapted from Howick and coworkers (2011).¹¹⁷

^bA systematic review may be downgraded to level B because of study limitations, heterogeneity, or imprecision.

^cA group of individuals identified for subsequent study at an early, uniform point in the course of the specified health condition or before the condition develops.

preference, clinicians should provide patients with clear and comprehensible information to explain their recommendation to facilitate patient understanding and informed decision making. In cases where evidence is weak or benefits unclear, shared decision making—where the management decision is made by a collaborative effort between the clinician and an informed patient—is extremely useful. Factors related to patient preference include, but are not limited to, absolute benefits (number needed to treat), adverse effects (number needed to harm), quality of life, cost of drugs or procedures, and frequency and duration of treatment. Certain less tangible factors, such as religious and/or cultural beliefs and patients' social situations, should be considered.

STATEMENT 1. AVOIDANCE OF ANTIBIOTIC THERAPY: Clinicians should not routinely prescribe antibiotic therapy for patients with a neck mass unless there are signs and symptoms of bacterial infection. *Recommendation based on observational studies with a preponderance of benefits over harm.*

Action Statement Profile

- Quality improvement opportunity: Avoid routine treatment with antibiotics, which may be inappropriate or ineffective treatment for a neck mass, thus leading to

delayed diagnosis of malignancy or other serious illness. (National Quality Strategy domains: safety, promoting effective treatment, affordable quality care)

- Aggregate evidence quality: Grade C, based on observational studies
- Level of confidence in evidence: Medium
- Benefits: Avoid delay in diagnosis of malignancy, promote judicious antibiotic therapy, limit bacterial resistance, reduce antibiotic adverse effects, reduced cost
- Risks, harms, costs: Under treatment of a missed bacterial infection
- Benefit-harm assessment: Preponderance of benefit over harm
- Value judgments: Perception by GDG that antibiotics are common for noninfectious neck masses, delaying diagnosis and/or referral. Further perception that physical examination is the primary determinant of an infectious cause of a neck mass, and history is a secondary determinant.
- Intentional vagueness: None
- Role of patient preferences: None
- Exceptions: None
- Policy level: Recommendation
- Differences of opinion: None

Table 3. Guideline Key Action Statements.

| Statement | Action | Strength |
|--|--|-----------------------|
| 1. Avoidance of antibiotic therapy | Clinicians should not routinely prescribe antibiotic therapy for patients with a neck mass unless there are signs and symptoms of bacterial infection. | Recommendation |
| 2a. Stand-alone suspicious history | Clinicians should identify patients with a neck mass who are at increased risk for malignancy because the patient lacks a history of infectious etiology and the mass has been present for ≥ 2 weeks without significant fluctuation or the mass is of uncertain duration. | Recommendation |
| 2b. Stand-alone suspicious physical examination | Clinicians should identify patients with a neck mass who are at increased risk for malignancy based on ≥ 1 of these physical examination characteristics: fixation to adjacent tissues, firm consistency, size > 1.5 cm, and/or ulceration of overlying skin. | Recommendation |
| 2c. Additional suspicious signs and symptoms | Clinicians should conduct an initial history and physical examination for adults with a neck mass to identify those patients with other suspicious findings that represent an increased risk for malignancy. | Recommendation |
| 3. Follow-up of the patient not at increased risk | For patients with a neck mass who are not at increased risk for malignancy, clinicians or their designees should advise patients of criteria that would trigger the need for additional evaluation. Clinicians or their designees should also document a plan for follow-up to assess resolution or final diagnosis. | Recommendation |
| 4. Patient education | For patients with a neck mass who are deemed at increased risk for malignancy, clinicians or their designees should explain to the patient the significance of being at increased risk and explain any recommended diagnostic tests. | Recommendation |
| 5. Targeted physical examination | Clinicians should perform, or refer the patient to a clinician who can perform, a targeted physical examination (including visualizing the mucosa of the larynx, base of tongue, and pharynx) for patients with a neck mass deemed at increased risk for malignancy. | Recommendation |
| 6. Imaging | Clinicians should order a neck computed tomography (or magnetic resonance imaging) with contrast for patients with a neck mass deemed at increased risk for malignancy. | Strong recommendation |
| 7. Fine-needle aspiration (FNA) | Clinicians should perform FNA instead of open biopsy, or refer the patient to someone who can perform FNA, for patients with a neck mass deemed at increased risk for malignancy when the diagnosis of the neck mass remains uncertain. | Strong recommendation |
| 8. Cystic masses | For patients with a neck mass deemed at increased risk for malignancy, clinicians should continue evaluation of patients with a cystic neck mass, as determined by FNA or imaging studies, until a diagnosis is obtained and should not assume that the mass is benign. | Recommendation |
| 9. Ancillary tests | Clinicians should obtain additional ancillary tests based on the patient's history and physical examination when a patient with a neck mass is at increased risk for malignancy and/or does not have a diagnosis after FNA and imaging. | Recommendation |
| 10. Examination under anesthesia of the upper aerodigestive tract before open biopsy | Clinicians should recommend examination of the upper aerodigestive tract under anesthesia, before open biopsy, for patients with a neck mass who are at increased risk for malignancy and without a diagnosis or primary site identified with FNA, imaging, and/or ancillary tests. | Recommendation |

Supporting Text

Antibiotics should be used to treat a neck mass only if there is evidence of a bacterial infection. Judicious use of antibiotics will minimize the unintended consequences of their misuse, including side effects, development of bacterial resistance, unnecessary health care costs, and delayed diagnosis of a malignancy.¹² Most neck masses in adults are not infectious; instead, most of these masses are neoplastic. An appreciation

of the relative infrequency of infectious etiologies of adult neck masses should direct the clinician to carefully consider the differential diagnosis of an adult neck mass, search for signs or symptoms consistent with an infectious process, and recognize the high likelihood of a malignancy before prescribing an antibiotic.

Local signs and symptoms of infection include warmth, erythema of the overlying skin, localized swelling, and tenderness to palpation.^{1,64} Systemic signs of infection include fever,

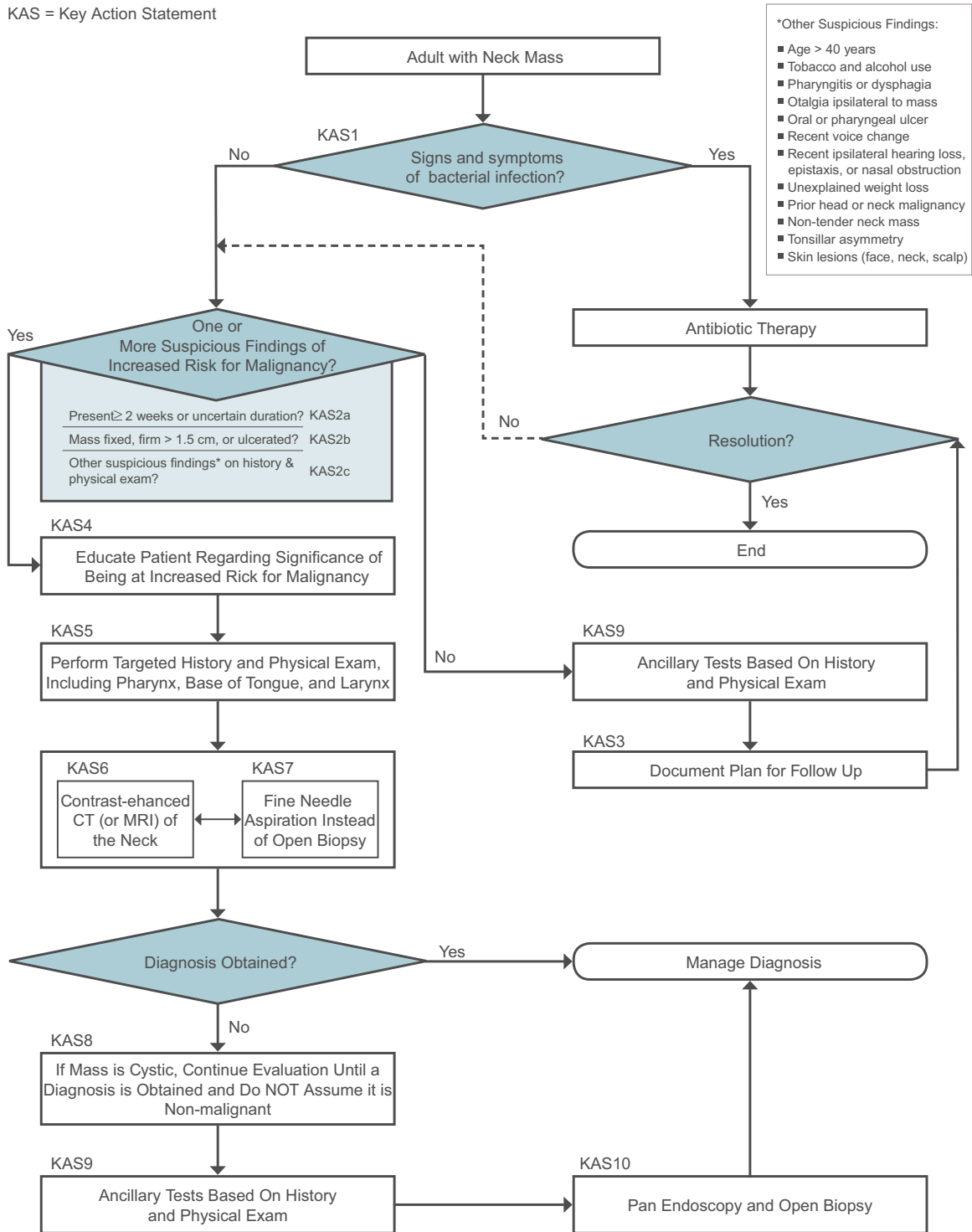


Figure 1. Algorithm depicting the relationship among the key action statements (KASs). CT, computed tomography; MRI, magnetic resonance imaging.

tachycardia, and other symptoms specific to head and neck infections (eg, rhinorrhea, odynophagia, otalgia, odontalgia).^{1,5,7} Even in the absence of these findings, one may suspect infection if the mass developed within a few days or weeks of an upper respiratory infection, dental problem, trauma (including insect bites), travel, or exposure to certain animals.^{2,5,64-67}

Reactive cervical lymphadenopathy commonly occurs with respiratory infection. Such lymphadenopathy, at least in children, typically resolves with the infectious symptoms or within a few days of completing treatment.⁶⁷⁻⁶⁹ Comparatively less literature exists about the natural course of resolution of inflammatory lymphadenopathy in adults, but we have

no reason to think that it is substantially different. While the literature on lymphadenopathy in adults is generally consistent with the idea that inflammatory nodes resolve commensurate with the infection, the literature is inconsistent about how long it may be reasonable to follow a neck mass attributed to inflammation. While some sources acknowledge that resolution of inflammatory lymphadenopathy may take 6 to 12 weeks,¹ most sources recommend a period of observation limited to 2 weeks^{7,65,69} and do not advise delaying further evaluation for malignancy beyond the initial 2-week period.

It is reasonable to prescribe a single course of a broad-spectrum antibiotic to treat a neck mass that appears to be infectious, provided that the patient is followed to allow additional evaluation if the neck mass does not resolve.^{7,65,66} A patient with neck mass who is treated with antibiotics should be reassessed within 2 weeks.^{1,7,65} If the mass has not completely resolved, further workup for possible malignancy is recommended, as outlined elsewhere in this guideline. Partial resolution may represent infection in an underlying malignancy and so requires additional evaluation.^{1,5,65,66,69} If infectious lymphadenopathy resolves as expected, the patient should be reassessed once more in 2 to 4 weeks to monitor for possible recurrence, which would prompt definitive workup for possible malignancy.⁶⁵ In the absence of signs and symptoms suggesting infection, empiric treatment with antibiotics should be avoided, and the mass should undergo further workup.

STATEMENT 2a. STAND-ALONE SUSPICIOUS HISTORY: Clinicians should identify patients with a neck mass who are at increased risk for malignancy when the patient lacks a history of infectious etiology and the mass has been present for ≥ 2 weeks without significant fluctuation or the mass is of uncertain duration. *Recommendation based on observational studies with a preponderance of benefits over harm.*

Action Statement Profile

- **Quality improvement opportunity:** To use simple questions to identify patients at increased risk for malignancy based on specific historical features. (National Quality Strategy domains: safety, promoting effective prevention/treatment)
- **Aggregate evidence quality:** Grade C, based on observational studies
- **Level of confidence in evidence:** Medium
- **Benefits:** Improve outcomes through earlier diagnosis, identify patients with an earlier stage of disease, prioritize testing for high-risk patients, potentially reduce risk of distant metastases through earlier cancer identification, provide psychological benefit through timely evaluation, facilitate further care
- **Risks, harms, costs:** False-positive clinical diagnosis resulting in subsequent tests and anxiety in patients with nonmalignant disease
- **Benefit-harm assessment:** Preponderance of benefit over harm
- **Value judgments:** The risk of missing or delaying diagnosis of a malignancy in a patient who is at

increased risk is more important than false-positive clinical diagnosis in a patient with nonmalignant disease. Assumption by the GDG that early identification of patients at increased risk with focused questions can improve outcomes, despite any direct clinical evidence to substantiate this assumption.

- **Intentional vagueness:** None
- **Role of patient preferences:** None
- **Exceptions:** None
- **Policy level:** Recommendation
- **Differences of opinion:** None

Supporting Text

The purpose of this statement is to use simple historical questions to identify patients with neck mass who are at increased risk for malignancy. Prompt identification of such patients will contribute to expeditious diagnosis of HNSCC, which is the principal quality improvement opportunity of this guideline.

A compelling history that may suggest an infectious etiology is a mass that develops within a few days or weeks of an upper respiratory infection, dental infection, trauma (including insect bites), travel, or exposure to certain animals.^{2,5,64-67} Signs of infection may be present, as outlined in KAS 1. Also, as previously outlined, a neck mass attributed to infection must be followed to resolution. An infectious mass that does not resolve is suspicious for malignancy. Likewise, in the absence of a compelling history of infection, the mass is suspicious for malignancy.

In the setting of a neck mass without recent infection, the clinician should establish the duration of the mass. The GDG felt that a noninfectious neck mass present ≥ 2 weeks without signs of improvement is concerning for malignancy. If the duration is unknown or if the patient was previously unaware of the mass, this also should be considered a persistent mass at increased risk for malignancy (**Table 4**). Thyroid cancer, salivary cancer, and HPV-associated oropharynx cancer usually occur in the absence of any known risk factors. Thus, the mere presence of a neck mass present ≥ 2 weeks without signs of improvement is suspicious for malignancy even in the absence of any other risk factors.

Some persistent neck masses are benign and can be identified as such based on their clinical features. However, that clinical determination is based on additional criteria and substantial clinical expertise that cannot be encompassed in this guideline. In keeping with the purpose of this guideline, which is to expedite diagnosis of occult malignancy, the GDG chose to limit this action statement to simple criteria to identify patients who may be at increased risk of malignancy.

STATEMENT 2b. STAND-ALONE SUSPICIOUS PHYSICAL EXAMINATION: Clinicians should identify patients with a neck mass who are at increased risk for malignancy based on ≥ 1 of these physical examination characteristics: fixation to adjacent tissues, firm consistency, size > 1.5 cm, and/or ulceration of overlying skin. *Recommendation based on observational studies with a preponderance of benefits over harm.*

Table 4. Characteristics Suspicious for Malignancy in the Presence of a Neck Mass.

| Characteristic | Rationale |
|---|---|
| Standalone characteristics suspicious for malignancy | |
| 1. Absence of infectious etiology | Absence of recent infection makes infection an unlikely etiology for the neck mass. |
| 2. Mass present ≥ 2 weeks or of uncertain duration | A persistent mass is more likely to be malignant. |
| 3. Reduced mobility of neck mass | Metastatic cancer may violate the lymph node capsule and directly invade adjacent structures. |
| 4. Firm texture of mass | A malignant lymph node is often firm due to the absence of tissue edema. A neck mass may be soft due to its fluid content, and while this sometimes is due to a benign cystic mass, fluid-filled cystic masses may also be malignant. An infectious lymph node may be soft due to tissue edema. |
| 5. Neck mass size > 1.5 cm | Lymph node metastases results in nodal enlargement. |
| 6. Ulceration of skin overlying the neck mass | Metastatic cancer may break through the capsule of the lymph node and directly invade and necrose the skin. Alternatively, the ulceration overlying a neck mass may indicate a cutaneous malignancy with direct extension into the neck. |
| Additional characteristics of history and physical examination suspicious for malignancy | |
| 1. Age > 40 years | Older age is associated with greater risk of HNSCC—particularly in patients with non-HPV related disease. |
| 2. Tobacco and alcohol use | Tobacco and alcohol are synergistic risk factors for HNSCC. |
| 3. Pharyngitis | “Sore throat” or throat pain may indicate mucosal ulceration or mass |
| 4. Dysphagia | Difficult swallowing may indicate ulceration, mass, or dysfunction of the aerodigestive system. |
| 5. Otalgia ipsilateral to the neck mass | Otalgia, with normal ear examination, may represent referred pain from the pharynx. Unilateral serous otitis media may result from eustachian tube obstruction by a nasopharyngeal malignancy. |
| 6. Oral cavity or oropharyngeal ulcer | Visible ulceration of mass, tenderness to palpation, or decreased tongue mobility may indicate a malignancy. |
| 7. Recent voice change | May indicate a malignancy of the laryngeal or pharyngeal structures. |
| 8. Recent hearing loss ipsilateral to the neck mass | May indicate a nasopharyngeal malignancy with unilateral middle ear effusion. |
| 9. Nasal obstruction and epistaxis ipsilateral to the neck mass | May indicate an ulcerated malignancy in the nose or nasopharynx. |
| 10. Unexplained weight loss | Cachexia is common in cancer patients. Head and neck cancer in particular may cause difficulty swallowing and cause wasting simply from inadequate nutrition. |
| 11. History of treatment for head and neck malignancy, including skin, salivary gland, or aerodigestive sites | Prior head and neck malignancy places a patient at risk for local or regional (nodal) recurrence or a second malignancy. Patients with prior radiation treatment are at risk for a secondary neoplasm decades later. |
| 12. Nontender neck mass | An infectious or inflammatory neck mass may be painful or tender. A nontender mass is less likely infection or inflammation and more likely neoplastic. |
| 13. Tonsil asymmetry | May indicate a malignancy within the larger tonsil. |
| 14. Skin lesions (face, neck, scalp included) | Cutaneous malignancy can metastasize to the cervical lymph nodes. |

Abbreviations: HNSCC, head and neck cancer squamous cell carcinoma; HPV, human papilloma virus.

Action Statement Profile

- **Quality improvement opportunity:** To identify patients at increased risk for malignancy because of specific features on physical examination. (National Quality Strategy domains: safety, promoting effective prevention/treatment)
- **Aggregate evidence quality:** Grade C, based on observational studies
- **Level of confidence in evidence:** Medium
- **Benefits:** Improve outcomes through earlier diagnosis, identify patients with earlier stage of disease, prioritize testing for patients at increased risk, potentially reduce risk of distant metastases through earlier cancer identification, psychological benefit of timely evaluation, facilitate further care
- **Risks, harms, costs:** False-positive clinical diagnosis resulting in subsequent tests and anxiety in patients with nonmalignant disease
- **Benefit-harm assessment:** Preponderance of benefit over harm
- **Value judgments:** The risk of missed or delayed diagnosis of malignancy is more important than the risk of a false-positive clinical diagnosis. Despite any direct clinical evidence, the GDG assumed that early identification of patients at increased risk of malignancy may improve outcomes.
- **Intentional vagueness:** None

- Role of patient preferences: None
- Exceptions: None
- Policy level: Recommendation
- Differences of opinion: GDG debated whether firm consistency of the mass is a predictor of malignancy (majority opinion: 14 of 18 felt that firmness is predictive of malignancy); GDG also debated whether absolute size of the mass, regardless of neck location, is a predictor of malignancy.

Supporting Text

The purpose of this statement is to identify patients with a neck mass that exhibits particular characteristics suggesting malignancy. The size, texture, mobility, location, laterality, and tenderness of a neck mass are characteristics that can aid the clinician in assessing the risk of malignancy. Malignant neck masses are likely to be >1.5 cm in diameter⁷⁰⁻⁷² and firm to palpation.^{67,73} Malignant neck masses may demonstrate reduced mobility in both longitudinal and transverse planes^{6,71} or may ulcerate the overlying skin either due to direct extension of the mass or because the mass is a primary skin cancer of the neck (**Table 4**). Additional findings that suggest malignancy are the presence of multiple, grouped, matted lymph nodes⁷¹ and continued increase in size of the neck mass.^{1,7,73}

Assessing the firmness of a neck mass is subjective. For this reason, firmness as a sole clinical feature may be less specific for malignancy than other physical findings. With HPV-positive HNSCC, soft, cystic masses may be malignant. Lymph node size as a sole feature is also not very specific for malignancy. Determination of the size of a lymph node based on physical examination varies across examiners. Studies have shown that caliper measurement is accurate and reproducible but is not widely utilized.⁷⁴ The GDG also recognizes that the size of a healthy lymph node varies according to location in the neck. A healthy jugulodigastric lymph node is typically the largest of all cervical lymph nodes, with 1.5 cm being the upper limit of normal. For this reason, the GDG decided that a size >1.5 cm was a reasonable indicator of possible malignancy in any cervical location.

STATEMENT 2c. ADDITIONAL SUSPICIOUS SIGNS AND SYMPTOMS: Clinicians should conduct an initial history and physical examination for all adults with a neck mass to identify those patients with an increased risk for malignancy. *Recommendation based on observational studies with a preponderance of benefits over harm.*

Action Statement Profile

- Quality improvement opportunity: This statement moves beyond the previously noted stand-alone suspicious findings (lack of infectious etiology, ≥ 2 -week duration of the mass, reduced mobility, firm texture, size >1.5 cm, ulceration) by using the initial history and examination to identify patients who have signs and symptoms that place them at increased risk of malignancy. (National Quality Strategy domains: safety, promoting effective prevention/treatments)

- Aggregate evidence quality: Grade C, based on case series
- Level of confidence in evidence: Medium
- Benefits: Improve outcomes through earlier diagnosis, identify patients with earlier stage of disease, prioritize testing for increased-risk patients, potentially reduce risk of distant metastases through earlier cancer identification, psychological benefit of timely evaluation, facilitate further care
- Risks, harms, costs: False-positive clinical diagnosis resulting in subsequent tests and anxiety in patients with nonmalignant disease
- Benefit-harm assessment: Preponderance of benefit over harm
- Value judgments: The risk of missing or delaying diagnosis of malignancy in an increased-risk patient is more important than potentially misclassifying patients with nonmalignant disease. Assumption by the GDG that early identification of at-risk status with the initial history and physical examination can improve outcomes. Assumption by the GDG that the listed signs and symptoms can predict risk of cancer above and beyond lack of infectious etiology, ≥ 2 weeks' duration of mass, reduced mobility, firm texture, size >1.5 cm, ulceration.
- Intentional vagueness: None
- Role of patient preferences: None
- Exceptions: None
- Policy level: Recommendation
- Differences of opinion: None

Supporting Text

The purpose of this statement is to use the history and physical examination to identify additional suspicious factors that may indicate an increased risk for malignancy. This statement builds on the aforementioned features (lack of infectious etiology, ≥ 2 weeks' duration, reduced mobility, firm texture, size >1.5 cm, ulceration). A clinician may quickly assess a patient's symptoms and social risk factors, as well as perform an initial physical examination. This initial evaluation may raise concern for HNSCC or may point to alternative etiology of the neck mass. Importantly, the GDG strongly believes that clinicians do not require specialty training or special equipment to perform the aspects of the head and neck examination described within this statement. The initial evaluation may identify a primary malignancy or another etiology for the neck mass. This information should be obtained during the initial patient encounter, as it will direct subsequent management.

History

Historical factors that increase the suspicion for HNSCC include patient age >40 years,^{6,7,55} tobacco use, alcohol abuse, or immunocompromised status.^{17,19,30,75} In the HPV era of HNSCC, these risk factors may be absent. Increased number of sexual partners and oral sex increase the risk of HPV-related oropharynx cancer.²⁹ Symptoms that increase suspicion include hoarseness^{25,73,76} otalgia,⁷⁷ hearing loss,⁷³ lip or

intraoral swelling/ulceration,^{25,75} new numbness in the oral cavity or cheek, dyspnea, odynophagia,^{75,76} dysphagia,^{73,75,76} weight loss,⁷⁶ hemoptysis or blood in the saliva, nasal congestion, and unilateral epistaxis.^{2,73} Nonspecific findings that raise suspicion for lymphoma include fever, night sweats, weight loss, lymphadenopathy distant from the head and neck region, or immunosuppressive or immunomodulating medications. Thyroid cancer is common in women age <40 years. A patient with a history of prior head and neck malignancy, including skin cancer of the scalp, face, or neck, is also at increased risk of a malignant neck mass (**Table 4**).

Physical Examination

The initial physical examination may alter the clinician's pretest probability of malignancy. This examination should include inspection of the face for swelling, edema, ulcerations, or pigmented lesions^{73,77} and scalp inspection for ulcerations or pigmented lesions.⁷³ A change in the appearance of a skin lesion's symmetry, border, color, or diameter or the presence of ulceration may suggest melanoma or other cutaneous malignancy.⁶⁷ Limited tongue mobility may indicate muscle or nerve invasion from tumor. A gauze can be used to grasp the tongue to facilitate inspection of its lateral aspects. Examination of the oral cavity requires removal of dentures for inspection of all surfaces and palpation of the floor of the mouth to identify ulcers or masses (**Table 4**).^{70,73,77} Examination of the oropharynx requires a bright light and tongue depressor. The examiner should ask the patient to open the mouth but not to protrude the tongue. Protruding the tongue obscures the oropharynx and causes the tongue to resist inferior depression with the tongue depressor, further limiting visualization of the palate, tonsil region, and posterior wall of the oropharynx. Suspicious signs include tonsil asymmetry or mass or ulcer in any location. Palpation of the oral tongue, base of tongue, and tonsils can help confirm suspicion of a mass, especially if a patient relates symptoms in these areas. The oropharynx may be difficult to examine completely due to anatomic constraints, and the base of tongue cannot be examined without flexible laryngoscopy or indirect (mirror) laryngoscopy. In the setting of an incomplete examination, the clinician should refer the patient to a specialist. The clinician should palpate the neck and thyroid gland for masses.^{70,71,73} In general, a nontender neck mass is more suspicious for malignancy than a tender neck mass (**Table 4, Figure 2**). The clinician should also be aware of normal anatomic structures that are often mistaken for a pathologic neck mass, including the submandibular glands, the hyoid bone, the transverse process of C2, and the carotid bulb.^{1,2,66} For a patient with a neck mass and otalgia, an unremarkable examination of the pinna, external auditory canal, and tympanic membrane suggests possible referred pain from a pharyngeal malignancy.

Physical examination is admittedly an imperfect test for identifying malignancy in a cervical node, and studies have demonstrated the limitation of neck examination among surgeons.^{74,78} Nonetheless, given the low cost and potential

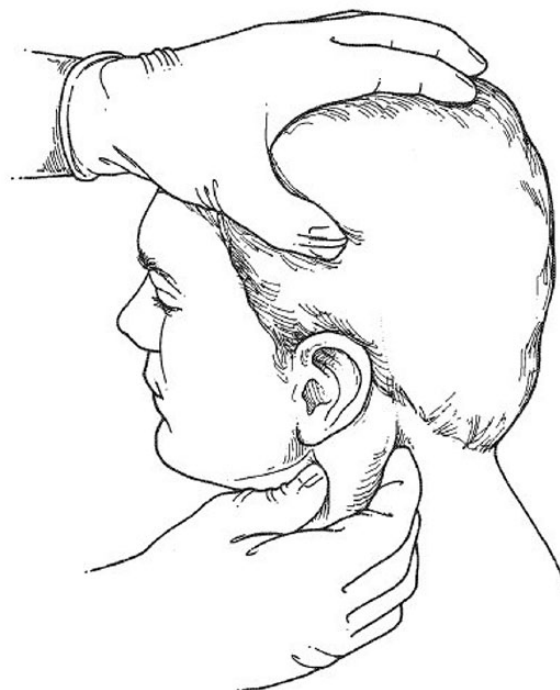


Figure 2. Neck examination: palpation of the sternocleidomastoid muscle evaluating for lymphadenopathy. With permission from Beenken SW, Maddox WA, Urist MM. Workup of a patient with a mass in the neck. *Adv Surg.* 1995;28:371-383.²

information to be gained, the initial physical examination is valuable if it can expedite diagnosis of a neck mass. If the patient or the mass exhibit stand-alone suspicious characteristics (KASs 2a and 2b) or the initial history and physical examination identify additional suspicious characteristics (KAS 2c), the patient is at increased risk of malignancy and should receive education (KAS 4) and undergo a targeted history and physical examination (KAS 5).

STATEMENT 3. FOLLOW-UP OF THE PATIENT NOT AT INCREASED RISK: For patients with a neck mass who are not at increased risk for malignancy, clinicians or their designees should advise patients of criteria that would trigger the need for additional evaluation. Clinicians or their designees should also document a plan for follow-up to assess resolution or final diagnosis. *Recommendation based on observational studies with a preponderance of benefits over harm.*

Action Statement Profile

- **Quality improvement opportunity:** Promote follow-up and engage patients in their care for better outcomes. (National Quality Strategy domains: engaging patients, effective prevention/treatment)
- **Aggregate evidence quality:** Grade C
- **Level of confidence in evidence:** Medium
- **Benefits:** Avoid false-negative diagnosis based on initial assessment, promote follow-up to ensure

Table 5. Patient Handout: Neck Mass Follow-up.**What do I need to know about my neck mass?**

A neck mass is an abnormal lump in the neck. A neck mass may be caused by infection, benign tumor, or a cancerous tumor. A neck mass from infection should go away completely when the infection goes away. If it does not, your health care provider will help you to choose tests to determine the cause of your neck mass.

What should I do?

- If you were given antibiotics, take them as prescribed.
- Once each week, check the size of the neck mass using your fingertips.
- Follow up with your provider to be sure that the neck mass decreases in size over time
- Be sure to follow through with any tests your provider ordered.

How do I check the size of my neck mass?

Once each week, use your fingertips to check the size of the mass. How wide is the mass? One fingertip wide? Two fingertips wide? How does that compare to the size last time you checked? The mass should get smaller over time. A mass due to infection should go away completely or return to a much smaller size, typically in 2 or 3 weeks.

Contact your provider if

- The mass gets larger
- The mass does not go away completely
- The mass goes away but then comes back

What else should I look for?

Notify your provider if you have

- Difficulty or pain with swallowing
- Neck pain or throat pain
- Mouth sores or tooth pain
- Ear pain or hearing loss on the same side as the lump in your neck
- Change in voice
- Unexplained weight loss
- Fever >101°F

How should I follow up with my provider?

You and your provider may stay in contact by phone, through electronic messages, by mail, or in person at the provider's office. You may need to go back to your provider's office for a repeat examination.

No matter how you follow up with your provider, be sure that the mass has gone away. If the mass does not go away, your provider will help you decide what to do next.

resolution of benign lesions and detect malignant masses, promote more timely diagnosis if the mass fails to resolve as expected, educate and empower patients, and promote shared decision making.

- **Risks, harms, costs:** Administrative burden for the clinician, health care cost of follow-up assessments
- **Benefit-harm assessment:** Preponderance of benefit over harm
- **Value judgments:** Perception by the GDG that patients with neck masses receive inconsistent follow-up, despite its importance
- **Intentional vagueness:** The timing and method of follow-up are not specified
- **Role of patient preferences:** Moderate regarding the method of follow-up
- **Exceptions:** None
- **Policy level:** Recommendation
- **Differences of opinion:** None

Supporting Text

The purpose of this statement is to decrease the risk associated with delayed or missed diagnosis of a malignant neck mass in a patient who is felt not to be at increased risk for malignancy because he or she does not meet the increased risk criteria (**Figure 1, Table 4**).

Follow-up is necessary because some neck masses initially attributed to benign pathology are later found to be malignant. Examples include patients with clinically diagnosed branchial cleft cysts but with subsequent pathologic diagnosis of metastatic HNSCC^{21,51,55} or patients who develop infection in a necrotic metastatic lymph node.^{79,80} Presumptive diagnosis of a benign etiology may give the patient a false sense of security and dissuade the patient from seeking additional evaluation when needed.

Clinicians should inform patients of the expected response to treatment. Printed educational material may supplement the discussion, and the GDG has developed a patient handout (**Table 5**). If antibiotics are provided, the clinician should

inform the patient about the expected time until response of the neck mass (ie, return of the lymph node to normal size, <1.5 cm) as well as the need for clinical follow-up if the mass persists. The patient and clinician are jointly responsible to ensure that the neck mass decreases in size or that a final diagnosis is made. The nature of follow-up is at the discretion of the patient and the clinician. Follow-up may entail a revisit or telephone call with the clinician, referral to a specialist, or additional testing.⁴⁸

STATEMENT 4. PATIENT EDUCATION: For patients with a neck mass who are deemed at increased risk for malignancy, clinicians or their designees should explain to the patient the significance of being at increased risk and explain any recommended diagnostic tests. *Recommendation based on observational studies with preponderance of benefits over harms.*

Action Statement Profile

- **Quality improvement opportunity:** (National Quality Strategy domains: safety, effective treatment)
- **Aggregate evidence quality:** Grade C, observational studies of the utility of diagnostic tests and imaging studies to assist with diagnosis of neck mass
- **Level of confidence in evidence:** Medium
- **Benefits:** Improve understanding of the risk of malignancy in a neck mass, as well as understanding of the need for targeted examination and tests/imaging, engage patients, establish expectations
- **Risks, harms, costs:** None
- **Benefit-harm assessment:** Preponderance of benefit over harm
- **Value judgments:** None
- **Intentional vagueness:** None
- **Role of patient preferences:** None
- **Exceptions:** None
- **Policy level:** Recommendation
- **Differences of opinion:** None

Supporting Text

The purpose of this statement is to highlight the importance of patient education, counseling, and shared decision making when caring for a patient with a neck mass. The scientific literature indicates that open communication and education empower patients to make informed decisions, improve treatment adherence, and promote greater satisfaction and better outcomes.⁸¹⁻⁸³

The clinician should ensure that the patient understands the clinical significance of a neck mass deemed to be at increased risk for malignancy. The clinician or designee should counsel the patient about risk factors for malignancy, including tobacco use, excessive alcohol consumption, increased numbers of sexual partners, oral sex, and prior history of HNSCC. When possible, the clinician should encourage the patient to reduce modifiable risk factors. The clinician may choose to discuss HPV vaccine, recognizing that most patients will

exceed the age limit and that the possible preventions of HNSCC are unproven. However, discussion of this, just as discussion of tobacco avoidance, is an important point of primary prevention. The clinician should also inform the patient that a lack of any of these risk factors does NOT mean that the mass is not cancer.

The clinician should explain to the patient relevant aspects of the evaluation, including diagnostic testing and specialty consultation. The clinician should discuss possible diagnoses, including carcinoma, and help the patient understand the importance of further evaluation and diagnostic testing to obtain a final diagnosis. The clinician should discuss that if a neck mass is a malignancy, it will often have started in the nasopharynx, oropharynx, or larynx (the “primary site”) and that symptoms related to the primary site may develop later.

Clinicians may improve patients’ adherence to the evaluation process with effective communication and education. The clinician may encourage the patient to bring a family member or friend to appointments. The patient should be allowed time for questions and discussion. Cultural diversity, language difficulties, and educational backgrounds should be considered during these discussions. Written information can be an important supplement to patient understanding and may increase patient involvement and encourage shared decision making (Table 6).^{82,83}

Diagnostic Procedures

The patient should have a clear understanding of necessary diagnostic examinations, including the process, urgency, risks, and benefits of each, as well as the expected time frame of test results and follow-up. It should be made clear to the patient that this is a shared decision process. The clinician will order and interpret the diagnostic procedures and give his or her opinion regarding what surgical intervention is needed. The clinician and the patient will share in the decision on what procedure will follow.⁸⁴ A detailed follow-up plan should be reviewed with the patient to include diagnostic testing and to ensure that those results are communicated in a timely fashion.

Referrals

When referred to a specialist, the patient should understand the roles of the referring clinician and the specialist. The patient should also understand the expected time frame to accomplish the specialist consultation. If the appointment is urgent, the clinician should reach out to the specialist to communicate the urgent need and obtain guidance for the diagnostic evaluation.^{48,84}

STATEMENT 5. TARGETED PHYSICAL EXAMINATION: Clinicians should perform, or refer the patient to a clinician who can perform, a targeted physical examination (including visualizing the mucosa of the larynx, base of tongue, and pharynx), for patients with a neck mass deemed at increased risk for malignancy. *Recommendation based on grade C aggregate evidence (observational studies) with a preponderance of benefit over harm.*

Table 6. Patient Handout: Frequently Asked Questions.**What does it mean that I have a neck mass at increased risk for malignancy?**

The mass in your neck may indicate a serious medical problem. It does not mean you have cancer, but it does mean you need more evaluation to make a diagnosis. Common symptoms in patients with a neck mass at increased risk for malignancy include

- The mass lasts longer than 2-3 weeks
- Voice change
- Trouble or pain with swallowing
- Trouble hearing or ear pain on the same side as the neck mass
- Sore throat
- Unexplained weight loss
- Fever >101°F

What do I do next?

Your provider will ask about medical history and examine your head and neck. Your provider may order tests or refer you to a specialist.

How urgently should I be evaluated?

Your provider will want to make sure you have a thorough evaluation, testing, and follow-up within a short period of time. It is important that you discuss this timeline with your provider and make sure there is a plan for follow-up after testing. It is important for you to follow this neck mass until it goes away or until you have a diagnosis.

What questions may my doctor ask?

- When did you first notice the lump? Has it grown?
- Have you had a recent illness?
- Do you have any trouble with eating, talking, swallowing, or hearing?
- Any sore spots in your mouth or throat?
- Do you have any sore or growing spots on your scalp, neck, or face?
- Have you lost weight?
- Are citrus fruits or tomatoes painful to eat?
- Do you have ear pain or sore throats that don't go away?
- Has your voice been hoarse?
- Have you coughed up any blood?
- Do you currently smoke, or do you have a smoking history? How much? How long?
- Do you drink alcohol, or do you have a history of drinking alcohol? How much? How long?
- Do you have a history of head and neck cancer?
- Any radiation exposure to your head or neck?
- Do you have any family history of head and neck cancer?

How will the provider examine my mouth and throat?

The provider will look in your mouth and throat with a bright light. If you wear dentures, you will need to remove them. The provider may use gauze to hold your tongue and feel the surfaces of the mouth, tongue, tonsils, or the back of your tongue.

The provider may use a small mirror in your mouth to see the voice box. If a “scope” is needed, the provider may first numb the nose and throat. The provider will then place a small tube in your nose and use a camera to examine your throat. You may have mild discomfort.

What is a computerized tomography (CT) scan?

A CT scan is a series of x-rays that give more detail than regular x-rays. CT scan pictures show soft tissue and bones. The CT machine looks like a large donut that your head, neck, and chest will go through. Patients without an allergy to contrast will need an IV—that is, a needle inserted into a vein—for contrast to enhance the pictures.

Risks include

1. Contrast allergy
2. Discomfort with IV placement
3. Patients with claustrophobia have minimal anxiety during this brief scan (3-5 minutes).
4. A CT scan uses radiation—about as much as 150 chest x-rays.

What is a magnetic resonance imaging (MRI) scan?

An MRI scan creates pictures of the soft tissue but not the bones. An MRI does not use radiation; it uses very strong magnets. The MRI machine looks like a narrow tube that your head, neck, and chest will go inside. You will need an IV for contrast to enhance the pictures. If you have any metal or implants in your body, you may not be able to have an MRI. You must discuss this with your provider.

Risks include

1. IV contrast allergy
2. Discomfort with IV placement
3. Patients with claustrophobia may be very anxious with this lengthy scan (45-60 minutes). Your provider may provide a sedative pill.

What is a fine-needle aspiration (FNA)?

An FNA uses a small needle stuck into the mass to get a tissue sample.

Risks include

1. Discomfort from needle stick
2. Infection
3. Bruising
4. Bleeding
5. Not enough tissue for a diagnosis—repeat procedure

Table 7. Essential Components of a Targeted Physical Examination in a Patient at Increased Risk for Head and Neck Malignancy.

| Anatomic Site | Examination Details |
|-----------------|--|
| Skin and scalp | May reveal a cutaneous malignancy |
| Otoscopy | Unilateral serous otitis media may suggest a nasopharyngeal malignancy |
| Cranial nerves | Itemized assessment of ocular motility, facial sensation and movement, hearing, palate elevation, presence of gag reflex, vocal fold movement, tongue mobility, and shoulder elevation |
| Oral cavity | Visual and digital examination of ventral and lateral surfaces of oral tongue and floor of mouth |
| Oropharynx | Visual examination of soft palate, tonsillar fossae, and posterior wall. Palpation of the tongue base and tonsillar fossae |
| Nasal cavity | Visual examination of the septum, floor, and turbinates |
| Nasopharynx | Visual examination of the eustachian tube orifices and superior and posterior walls |
| Hypopharynx | Visual examination of pyriform sinuses and posterior pharyngeal wall |
| Larynx | Visual examination of the epiglottis, vocal folds, and subglottis |
| Neck | Assessment of the neck mass firmness, size, fixation, location, and presence of additional lymphadenopathy. Bimanual palpation of the floor of mouth and entire neck |
| Salivary glands | Palpation of parotid and submandibular glands to assess for mass |
| Thyroid gland | Palpation to assess for mass |

Action Statement Profile

- **Quality improvement opportunity:** To encourage the use of a complete examination of the neck and the mucosal surfaces of the aerodigestive tract. (National Quality Strategy domains: safety, effective treatment)
- **Aggregate evidence quality:** Grade C observational studies
- **Level of confidence in evidence:** High
- **Benefits:** Identification of a primary source of neck mass or malignancy, focus and prioritize subsequent diagnostic tests, ensure that the patient has a full examination of mucosal surfaces by someone with the necessary diagnostic skills and/or equipment
- **Risks, harms, costs:** Cost of visit, cost and risks of diagnostic tests, detection of incidental lesions, false-positive diagnosis, discomfort (eg, laryngoscopy)
- **Benefit-harm assessment:** Preponderance of benefit over harm
- **Value judgments:** Consensus by the GDG that imaging is not a substitute for the additional information obtained by an examination that includes complete examination of the mucosal surfaces
- **Intentional vagueness:** The method (mirror or endoscope) of examination is at the discretion of the clinician, as is the decision to refer the patient to another clinician if one is unable to visualize the pharynx, base of tongue, and larynx.
- **Role of patient preferences:** Small to none; patient may decline examination
- **Exceptions:** None
- **Policy level:** Recommendation
- **Differences of opinion:** None

Supporting Text

The purpose of this statement is to increase the likelihood of identifying a primary malignancy on physical examination in

a patient with a neck mass at increased risk for malignancy. A targeted examination of the skin, thyroid, and salivary glands as well as the upper aerodigestive tract will often identify a primary HNSCC malignancy in a patient with regional metastasis.⁸⁵ Health care clinicians without training, expertise, or familiarity with performing such an examination should refer the patient to a specialist.

A targeted physical examination relevant for a patient with a neck mass at increased risk for malignancy includes all elements listed in **Table 7**. Some of the least accessible anatomic sites may be the most important for careful examination. For example, in patients who are otherwise deemed to have an “unknown primary,” the sites most likely to harbor malignancy are the nasopharynx, base of tongue, hypopharynx, and supraglottic larynx.⁸⁵ The approach to examination of these sites may differ depending on the experience of the specialist and compliance of the patient. For example, in a compliant patient, manual palpation should be used to assess for tumor in the base of tongue and tonsil fossae (**Figures 3, 4**). Bimanual palpation should be used to examine the tonsils and floor of mouth (**Figure 5**). Fiberoptic examination is commonly utilized to aid this detailed examination (**Figure 6**).^{86,87} Imaging also may be an important adjunct, but it is not a substitute for physical examination.⁸⁵

Neck Mass Location

Based on expected patterns of lymphatic drainage, the location of the neck mass may suggest the site of a primary malignancy. Lip and oral cavity primaries usually metastasize to lymph nodes in levels I to III; oropharyngeal, hypopharyngeal, and laryngeal primaries commonly metastasize to levels II to IV; and nasopharyngeal and thyroid primaries as well as lymphoma can spread to level V (**Figure 7**).⁸⁸ While the majority of malignant neck masses arise from supraclavicular primary malignancies, 50% of masses in level IV and the supraclavicular fossa arise from primary malignancies below the clavicle, including the chest and gastrointestinal tract.⁸⁹

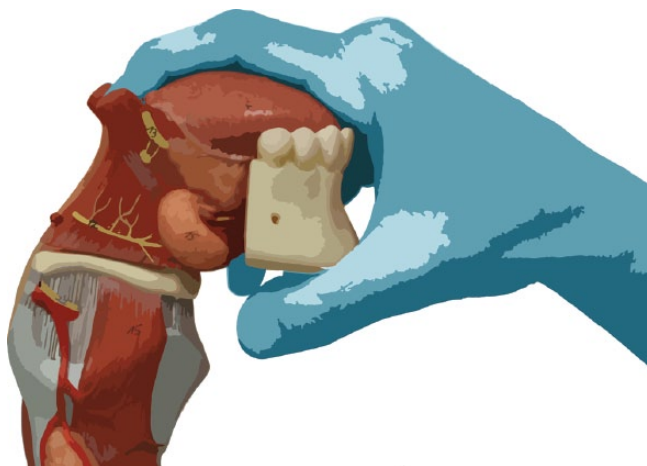


Figure 3. Palpation of the tongue base (lateral view).

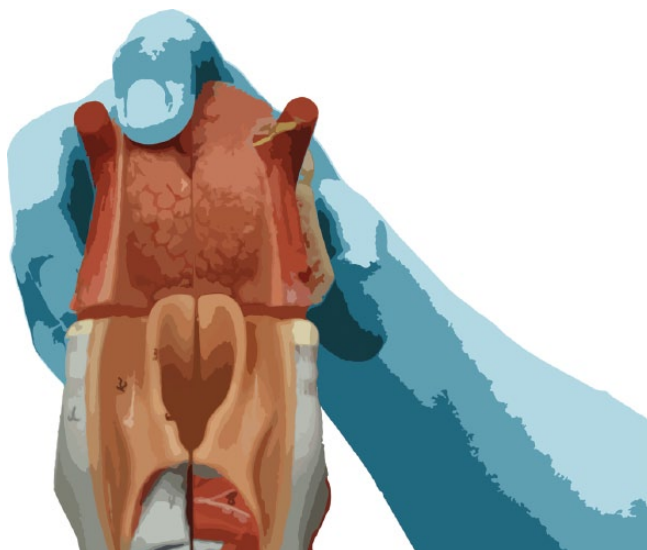


Figure 4. Palpation of the tongue base (posterior view).

Skin cancers can metastasize to levels I to V as well as the external jugular, postauricular, suboccipital, and parotid regions.⁸⁸ Nasopharyngeal, tongue base, and midline oral cavity (tongue) cancers may result in bilateral cervical metastases,⁸⁹ and patients with distant lymphadenopathy may have a malignancy outside the head and neck, including lymphoma, lung, breast, or gastrointestinal tract, and should undergo thorough evaluation of those possible sources.⁹⁰ Midline neck masses warrant special consideration given the diversity of the differential diagnosis, including thyroglossal duct cyst, thyroglossal duct carcinoma, thyroid malignancy, or metastatic spread from laryngeal malignancy (Delphian node). The GDG acknowledges that experienced clinicians may be able to distinguish a midline neoplasm that is separate and distinct from a mass suggestive of metastasis from upper aerodigestive tract tumors. Clinicians are not obliged to follow the CPG if they are reasonably certain that clinical findings are not consistent with the CPG paradigm.

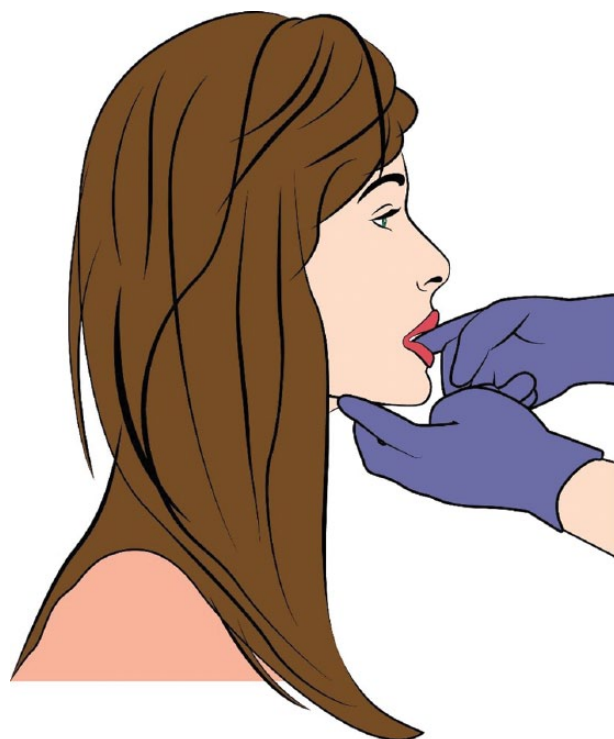

Figure 5. Bimanual palpation of floor of mouth.

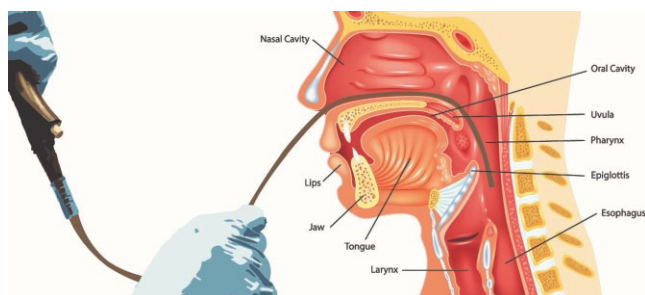


Figure 6. Scope examination.

STATEMENT 6. IMAGING: Clinicians should order a neck computed tomography (CT; or magnetic resonance imaging [MRI]) with contrast for patients with a neck mass deemed at increased risk for malignancy. *Strong recommendation based on randomized controlled trials.*

Action Statement Profile

- **Quality improvement opportunity:** To promote timely and effective imaging assessment of a neck mass in patients deemed at risk for malignancy
- **Aggregate evidence quality:** Grade B, randomized controlled trials, consistent evidence from observational studies
- **Level of confidence in evidence:** High
- **Benefits:** Ensure that when imaging is ordered, the right test is selected and contrast is given, distinguish malignant from benign masses, plan for FNA

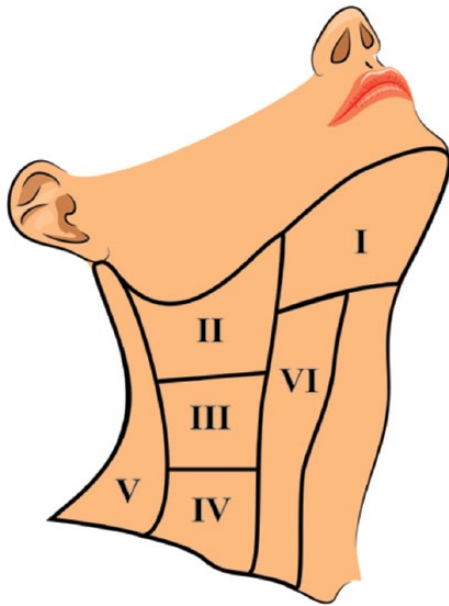


Figure 7. Lymph node levels of neck.

or biopsy, define extent of disease to facilitate staging, detect occult disease, guide treatment decisions, further testing and referral

- **Risks, harms, costs:** Radiation (CT), contrast adverse reactions, anxiety, claustrophobia, cost, incidental findings, false positives, false negatives
- **Benefit-harm assessment:** Preponderance of benefit over harm
- **Value judgments:** None
- **Intentional vagueness:** The clinician may choose whether to order CT or MRI based on the specific clinical situation.
- **Role of patient preferences:** Small role. Claustrophobic patients may prefer CT over MRI. MRI may be preferable if radiation exposure is a concern.
- **Exceptions:** Imaging recommendations may be altered in pregnancy. The protocol for contrast administration may be altered in the setting of contrast allergy or renal insufficiency.
- **Policy level:** Strong recommendation
- **Differences of opinion:** None

Supporting Text

The purpose of this statement is to emphasize the importance of obtaining neck imaging in those patients who are deemed to be at increased risk of malignancy and to provide guidance in study selection. Contrast-enhanced CT or MRI examinations obtained in patients with a neck mass of uncertain etiology will help localize and characterize the mass, assess for additional nonpalpable masses, and screen visualized organs (most notably the upper aerodigestive tract) that are potential sites of primary malignancy. Furthermore, this imaging may provide useful ancillary information, such as evidence of

dental disease, granulomas of the lung apices, and salivary calculi that could suggest alternative diagnoses. The standard neck CT or MRI is protocolled to extend from the skull base to the thoracic inlet to adequately capture all structures for evaluation.

Both CT and MRI are effective tools in the assessment of neck masses, although CT has several benefits that support its utilization as a primary imaging modality.⁹¹ CT is more readily available, costs considerably less, and is generally more easily tolerated by patients because of shorter scanning time (<5 minutes) and larger scanner bore. While CT utilizes ionizing radiation, the average dose of 3 mSv (equivalent to approximately 150 chest x-rays) is considered acceptable in the adult population.⁹² MRI offers improved tissue contrast and can help detect subclinical tumors not evident with nasal endoscopy.⁹³ MRI is preferred when a primary tumor of the nasopharynx is suspected or when there is cranial nerve abnormality on physical examination because of its improved sensitivity to abnormalities of the skull base and in the detection of perineural spread. This benefit, however, is often offset by motion artifact related to breathing and by the inability of the patient to remain motionless for scan times that typically exceed 30 minutes. The presence of some implantable medical devices, such as pacemakers and neurostimulators, precludes MRI scanning. If dental artifact obscures visualization of the tonsillar fossa and base of tongue and if an abnormality in this area is suspected, MRI or referral to a specialist for examination should be considered.

Intravenous Contrast

Regardless of whether CT or MRI is performed, intravenous contrast should always be used, unless there is a contraindication, such as contrast allergy, renal insufficiency, or prior diagnosis that excludes the use of contrast.⁹¹ Contrast improves characterization of the mass, particularly with regard to distinguishing cystic from solid lesions; it helps map lesion borders; and it improves identification of potentially small primary sites in the upper aerodigestive tract. KAS 8 offers additional information regarding cystic neck masses that should not be assumed to be benign cysts or abscesses. There is rarely added benefit to performing a noncontrast CT scan prior to contrast administration, and ordering a CT with and without contrast should be avoided because of the doubled radiation dose. Renal insufficiency may preclude contrast administration in both CT and MRI examinations. The MRI contrast agent gadolinium is responsible for nephrogenic systemic fibrosis, a rare but highly morbid condition associated with fibrosis of the skin, joints, eyes, and organs.⁹⁴ In the setting of severe renal insufficiency, a noncontrast MRI offers a small benefit over noncontrast CT because of its inherent superior soft tissue characterization.⁹¹

Other Cross-sectional Imaging Techniques

Other cross-sectional imaging techniques, such as CT or magnetic resonance angiography, may provide useful information in the setting of pulsatile lesions but are not part of routine screening neck imaging protocols. A role for routine

performance of chest x-ray in the setting of a neck mass has not been established. However, if the patient is deemed at risk for a primary lung cancer on the basis of history, symptomatology, or physical examination, then the results of a chest x-ray can guide further testing and management. PET/CT (positron emission tomography with CT) is ideally reserved for those patients in whom malignancy was already diagnosed, and it is generally utilized as part of the staging process.

Ultrasound

Ultrasound can be used to characterize a neck mass, to guide percutaneous tissue sampling, and to search for additional masses.⁹⁵ It is both noninvasive and inexpensive, and it is increasingly advocated by many imagers, particularly outside the United States. Ultrasound is, however, best suited for evaluation of superficial tissue and will not adequately visualize most portions of the upper aerodigestive tract, where many primary tumors will arise.⁶⁷ Ultrasound is also operator dependent, and quality may vary considerably per the experience of the ultrasonographer. Ultrasound may be considered a first option in clinical situations excluded by this review (thyroid, salivary masses), in situations where there will be a delay in obtaining CT or MRI, if the use of contrast medium is contraindicated, or as an adjunct to expedite FNA biopsy (KAS 7).

STATEMENT 7. FINE-NEEDLE ASPIRATION: Clinicians should perform FNA instead of open biopsy, or refer the patient to someone who can perform FNA, for patients with a neck mass deemed at increased risk for malignancy when the diagnosis of the neck mass remains uncertain. *Strong recommendation based on systematic reviews with a consistent reference standard.*

Action Statement Profile

- **Quality improvement opportunity:** Avoid unnecessary open biopsy with its associated complications and promote timely FNA as the initial pathologic test for a patient with a neck mass at increased risk of malignancy (National Quality Strategy domains: safety, effective treatment)
- **Aggregate evidence quality:** Grade A, systematic reviews with a consistent reference standard
- **Level of confidence in evidence:** High
- **Benefits:** Rapid, cost-effective test with high sensitivity and specificity for diagnosis, minimal discomfort, low risk of seeding malignancy, does not affect imaging results, can prioritize further imaging or workup
- **Risks, harms, costs:** Discomfort, direct cost, risk of nondiagnostic or indeterminate test results
- **Benefit-harm assessment:** Preponderance of benefit over harm
- **Value judgments:** Perception by the GDG that some patients undergo inappropriate open biopsy prior to attempted FNA. The GDG also noted that some patients experience unwarranted delay prior to tissue biopsy

- **Intentional vagueness:** There are a variety of techniques, operators, and settings in which neck mass FNA may be performed; these choices are left to the discretion of the clinician and patient.
- **Role of patient preferences:** None
- **Exceptions:** None
- **Policy level:** Strong recommendation
- **Differences of opinion:** None

Supporting Text

The purpose of this statement is to promote FNA as the initial diagnostic test for a patient at increased risk for a malignant neck mass and to limit the use of open biopsy. Open biopsy should be avoided whenever possible, as it has been shown to result in nonhealing wounds, regional recurrence, and distant metastasis when not performed as part of definitive treatment in the neck.⁹⁶ Issues surrounding the sampling process, the potential use of core biopsy, the collection of material for ancillary testing, and appropriate follow-up for nondiagnostic, indeterminate, and negative FNA samples are also addressed. FNA can be performed at the time of initial consultation prior to additional imaging by experienced physicians who are familiar with the technique.

FNA is an accurate, safe, and cost-effective method in the diagnosis of a neck mass and is useful for the diagnosis of malignancy in cases of metastatic squamous cell carcinoma, thyroid carcinoma, and lymphoma. A meta-analysis found an overall accuracy of 93.1% (range, 73.3%-98.0%) for FNA in the evaluation of all neck masses regardless of anatomic site (lymph node, thyroid, salivary gland) and final histologic diagnosis. The overall sensitivity was 89.6%; specificity, 96.5%; positive predictive value, 96.2%; and negative predictive value, 90.3%.⁹⁷ When analyzed by specific anatomic site, all sites had high specificity and accuracy, while thyroid and salivary gland FNA had somewhat lower sensitivities (81.1% and 82.5%, respectively) and lymph node FNA had a higher sensitivity (92.5%).

Aspiration of head and neck lesions is safe with only rare major complications reported in the literature, often in the form of single case reports. The theoretical risk of tumor seeding the needle tract was addressed in a systematic review that estimated an exceedingly low crude risk of seeding after FNA (0.00012%).⁹⁸ Given the low risk of FNA, there are no absolute contraindications to FNA of a neck mass. Vascular lesions and carotid body tumors are sometimes listed as contraindications to neck aspiration, but reports exist describing uncomplicated aspiration of such lesions⁹⁹; however, imaging is recommended prior to FNA for any suspected vascular lesion (eg, pulsatile or thrill on palpation; bruit on auscultation). Use of anticoagulation therapy does not result in increased risk of bleeding after neck FNA and therefore is also not considered an absolute contraindication to FNA.¹⁰⁰

FNA is a procedure by which a small sample of a lesion is obtained through a small-caliber needle. While negative pressure from a syringe is frequently employed, this is not necessary, and acquisition of the sample through capillary action can also be very successful (so called “French” or “Zajdela”

technique or “fine-needle nonaspiration”). There are a variety of techniques, operators, and settings in which neck mass FNA may be performed; however, it is not the intention of this guideline to recommend one over the other but rather to leave this to the discretion of the clinician and patient to allow for the timeliest diagnosis. In contrast to FNA, a core needle biopsy uses a larger-gauge needle with the intention of obtaining an intact cylindrical portion of tissue. Open biopsy, which is more invasive than both FNA and core biopsy, may entail incisional or excisional biopsy.

Ancillary Tests

In many instances, an accurate diagnosis depends on the ability to perform ancillary tests on the collected specimen. Consultation with a cytopathologist can be useful to determine the best method for collection (eg, smear preparation, collection media to use) depending on the clinical differential diagnosis and laboratory preference. Determination of HPV status is increasingly important in the setting of metastatic HNSCC and can be accomplished in several different ways. At a minimum, a portion of FNA material should be submitted in formalin or other suitable fixative for cell block to allow HPV in situ hybridization/polymerase chain reaction and/or p16 immunohistochemistry in the setting of metastatic HNSCC.¹⁰¹ Nasopharyngeal carcinoma presents as a carcinoma of unknown primary in the neck much less commonly than HPV-positive oropharyngeal carcinoma,⁸⁵ but collection of material for cell block will also allow for Epstein-Barr virus in situ hybridization in select circumstances. Increasingly, laboratories are able to test for HPV through molecular methods from liquid-based cytology media, and if this option is available, it should be coordinated with the pathology laboratory.¹⁰² The collection of material for cell block is also useful in the setting of other metastatic lesions, as it allows characterization of the tumor immunophenotype and can guide the search for a primary lesion. In the setting of a possible lymphoma, collection of material in a tissue culture media such as Roswell Park Memorial Institute medium is important to allow for immunophenotypic analysis by flow cytometry. When infection is considered in the differential diagnosis, submission of some material for culture is also recommended.

FNA Results

The reporting and appropriate follow-up of FNA results are essential to clinical care. An important distinction must be made between an inadequate specimen and an adequate but indeterminate specimen. An inadequate specimen indicates an insufficient amount of well-preserved lesional material available for confident diagnosis by the pathologist. In contrast, an adequate but indeterminate sample (eg, atypical, keratin debris, or “neoplasm of uncertain malignant potential”) indicates the presence of sufficient lesional material, but often due to the inherent nature of the process, definite conclusions about the precise diagnosis cannot be made. While FNA of neck masses is highly accurate, with only small numbers of false-negative diagnoses, some patients could have a delay in diagnosis/treatment as a result of such a false-negative result. An adequate and negative FNA, while

reassuring in many cases, should not preclude additional diagnostic procedures for a patient with worrisome signs and symptoms, for this reason.

Following an FNA with either inadequate results or a diagnosis of benign pathology, repeat FNA may be valuable as it may diagnose a malignancy. Therefore, for a patient with worrisome signs and symptoms for whom open biopsy is contemplated, repeat FNA should be attempted prior to resorting to an open biopsy.¹⁰³ Some cases of indeterminate cytology may also benefit from repeat aspiration. Discussion with the cytopathologist may be useful in guiding the decision to repeat an FNA after an indeterminate initial result. When repeat FNA is performed, additional steps should be taken to optimize the possibility of an adequate sample and accurate diagnosis. The addition of ultrasound-guided FNA has been shown to increase specimen adequacy: it can be useful when initial palpation-guided FNA is of limited diagnostic utility,^{95,104} and it can improve the diagnostic yield with cystic or necrotic masses by facilitating directed biopsy of the solid component of the cyst.⁹⁵ Finally, on-site evaluation by a cytopathologist, when available, can reduce the inadequacy rate of FNA.¹⁰⁵

Core Biopsy

Core biopsy is an option after an initial inadequate or indeterminate FNA. In a meta-analysis, ultrasound-guided core biopsy was shown to have a high rate of adequacy (95%) and high accuracy (94% and 96% in detection of neoplasia and malignancy, respectively) as well as a low rate of complications (1%).¹⁰⁶ If history and physical examination findings strongly suggest lymphoma, then a core needle biopsy or similar tissue sampling may be considered as the first-line tissue sampling technique. In this setting, core needle biopsy has a higher sensitivity than FNA (92% vs 74%).¹⁰⁶ Rapid on-site evaluation by a cytopathologist can also be useful in these settings to triage tissue and direct the need for a core biopsy if preliminary cytologic findings are concerning for lymphoma. To facilitate patient education, the GDG has developed a patient handout explaining neck mass biopsy (**Table 8**).

STATEMENT 8. CYSTIC MASSES: For patients with a neck mass deemed at increased risk for malignancy, clinicians should continue evaluation of patients with a cystic neck mass, as determined by FNA or imaging studies, until a diagnosis is obtained and should not assume that the mass is benign. *Recommendation based on observational studies with a preponderance of benefit over harm.*

Action Statement Profile

- **Quality improvement opportunity:** Avoid misdiagnosis of malignant lesions with potentially decreased survival (National Quality Strategy domains: safety, effective treatment)
- **Aggregate evidence quality:** Grade C
- **Level of confidence in evidence:** High
- **Benefits:** Avoid misdiagnosis of malignant lesions, avoid inappropriate care (eg, excision, open biopsy), avoid delays in diagnosis, reduce false sense of security

Table 8. Patient Handout: Neck Mass Biopsy.

| Neck Mass Biopsy—What Should the Patient Expect? | |
|---|--|
| What is a biopsy? | A biopsy involves taking a sample of tissue from the neck mass. This sample of tissue is looked at under the microscope by a pathologist (a specialized doctor) to make a diagnosis. A biopsy is a common test to check for cancer. There are different types of biopsies that can be done. The type of biopsy performed is based on your history and the location of your mass. |
| What are the different types of biopsies? | |
| 1. Fine-needle aspiration (FNA) | An FNA is the best initial test to diagnose a neck mass. A small needle is put into the mass, and tissue is pulled out. An FNA is often done in your doctor's office. It is well tolerated by most patients. Risks include <ul style="list-style-type: none"> • Discomfort • Bruising • Infection • Not getting enough tissue for a diagnosis |
| 2. Core biopsy | A core biopsy is another way to diagnose a neck mass. A core biopsy may be done instead of or after an FNA. A core biopsy uses a slightly larger needle and gets a larger piece of tissue. It is well tolerated and has a low risk of complications. Risks include <ul style="list-style-type: none"> • Bleeding • Bruising • Discomfort • Infection • Not getting enough tissue for diagnosis |
| 3. Open biopsy | An open biopsy is another way to diagnose a neck mass. It is a more invasive procedure. Open biopsy is done by a surgeon in the operating room, and you will need anesthesia. An open biopsy may remove only a portion of the mass or the whole mass. Because open biopsies are more invasive, there is a higher risk for complications. Risks include <ul style="list-style-type: none"> • Complications of anesthesia • Infection • Bleeding • Discomfort • Scarring • Nerve injury (numbness; paralysis) |
| What should I do to prepare for a biopsy? | If you need an open biopsy, your provider will tell you how to prepare. For any biopsy, let your provider know if you take blood thinners or have bleeding problems. |
| When should I get my results? | Your medical provider should call you or set up a follow-up appointment within 1 week of your biopsy. If you do not get your results after 1 week, you should call your medical provider. |

- Risks, harms, costs: Cost of additional diagnostic tests
- Benefit-harm assessment: Preponderance of benefit over harm
- Value judgments: Concern by the GDG that some patients receive false reassurance that a cystic mass is not of concern despite studies showing a high rate of malignancy and false-negative biopsies in such masses
- Intentional vagueness: None
- Role of patient preferences: None

- Exceptions: None
- Policy level: Recommendation
- Differences of opinion: None

Supporting Text

The purpose of this statement is to avoid delayed diagnosis or misdiagnosis of cystic neck masses that are malignant in adult patients. Traditionally, the most common cause of a lateral cystic neck mass has been thought to be a branchial cleft anomaly.^{54,55,107} However, a single cervical cystic lymph node metastasis can mimic a branchial cleft cyst clinically,

radiologically, and even histologically if not examined thoroughly.²⁰ This is especially true in papillary thyroid carcinoma, lymphoma, and oropharyngeal carcinoma. Benign and malignant salivary gland neoplasms may also be cystic. Imaging characteristics suggestive of malignant processes (large size, central necrosis with rim enhancement after contrast, multiple enlarged lymph nodes, extracapsular spread, asymmetric thickness of the wall, areas of nodularity, and nonconforming nature of the cystic wall) should be assessed when a cystic neck mass is observed.⁷² Up to 62% of neck metastases from Waldeyer ring sites (tonsils, nasopharynx, and base of tongue) are cystic, and 10% of malignant cystic neck masses present without an obvious primary tumor.⁵⁴ Although the overall incidence of malignancy in a given cystic neck mass is only 4% to 24%,^{54,103,108,109} the incidence of cancer in a cystic neck mass increases to 80% in patients >40 years old.¹⁰⁹ As the incidence of HPV-positive oropharyngeal HNSCC continues to increase, the proportion of cystic neck masses that are malignant will continue to rise as well.

Malignant cystic neck lesions in the adult are often difficult to differentiate from benign cysts (eg, branchial cleft cysts) on the basis of imaging due to similar appearance or on FNA due to the paucity of diagnostic cellular material. Depending on the clinical scenario, FNA may need to be repeated, possibly with image guidance to direct the needle into any solid components or the cyst wall.⁹⁵ While the sensitivity of FNA is lower in cystic cervical metastases (73%)¹⁰³ versus solid masses (90%),⁹⁷ FNA should be used as the first-line modality for histologic assessment for any adult with a cystic neck mass. In the absence of a potential primary malignancy site in the oral cavity, pharynx, or larynx amenable to biopsy, if malignancy is suspected in the neck mass and repeated FNA or image-guided FNA are inadequate or benign, an expedient open excisional biopsy is recommended to establish a definitive diagnosis. Excisional biopsy is preferred, especially with regard to cystic masses, to reduce the risk of tumor spillage into the wound.

STATEMENT 9. ANCILLARY TESTS: Clinicians should obtain additional ancillary tests based on the patient's history and physical examination when a patient with a neck mass is at increased risk for malignancy and/or does not have a diagnosis after FNA and imaging. *Recommendation based on nonconsecutive studies, observational studies, case series, and panel consensus with preponderance of benefit over harm.*

Action Statement Profile

- Quality improvement opportunity: To identify laboratory or other test that can aid in neck mass diagnosis (National Quality Strategy domains: promoting effective prevention/treatment)
- Aggregate evidence quality: Grade C, nonconsecutive studies, case-control studies, observational studies, case series
- Level of confidence in evidence: Medium
- Benefits: Diagnose neck mass and avoid invasive procedures/anesthesia

- Risks, harms, costs: Direct costs of ancillary tests, false-positive tests, incidental findings, risk of failure to diagnose concurrent malignancy based on these test results
- Benefit-harm assessment: Preponderance of benefit over harm
- Value judgments: None
- Intentional vagueness: The specific tests and timing are at the discretion of the clinician
- Role of patient preferences: None
- Exceptions: None
- Policy level: Recommendation
- Differences of opinion: None

Supporting Text

The purpose of this statement is to help the clinician resolve uncertainty about the etiology of a neck mass in those patients for whom the diagnosis was not made with imaging and FNA or to assist the clinician in confirming a suspected nonmalignant diagnosis. These ancillary tests are rarely able to make the diagnosis alone,¹ but when combined with history, examination, imaging, and FNA, targeted testing provides supplementary information that may aid the clinician in finding an accurate diagnosis.⁸

The decision to obtain any of these tests should be based on the clinician's clinical suspicion for a particular disease. It is not recommended that these tests be obtained in patients for whom there is no clinical suspicion of the associated disease. Ancillary testing may be appropriate for patients regardless of risk status and may be performed at any time during the workup of a neck mass. Importantly, however, for patients who are at increased risk, ancillary testing should be performed simultaneously with the malignancy workup to avoid delayed cancer diagnosis.

Table 9 provides an overview of some of the more common ancillary tests useful in the evaluation of neck mass of unknown etiology. The outlined tests may be high yield when the physical examination or history indicates elevated clinical concern for 1 of the suspected diseases. Additionally, Appendix 1 (available at in the online version of the article) provides a more comprehensive differential diagnosis for causes of a neck mass, categorized according to duration of the mass, location, and patient history and physical examination findings expected with the diagnosis.

STATEMENT 10. EXAMINATION UNDER ANESTHESIA OF THE UPPER AERODIGESTIVE TRACT BEFORE OPEN BIOPSY: Clinicians should recommend examination of the upper aerodigestive tract under anesthesia, before open biopsy, for patients with a neck mass who are at increased risk for malignancy and without a diagnosis or primary site identified with FNA, imaging, and/or ancillary tests. *Recommendation based observational studies with a preponderance of benefit over harm.*

Action Statement Profile

- Quality improvement opportunity: To improve understanding that a neck mass may be a metastatic lesion from a primary aerodigestive site and that identification of these lesions improves treatment outcomes (National Quality Strategy domains: safety, effective treatment)

Table 9. Common Ancillary Tests for Evaluation of an Adult Neck Mass.^a

| Ancillary Test | Suspected Disease |
|---|--|
| Complete blood count (CBC) with differential | WBC elevation: bacterial infection, lymphoma WBC depression: immunosuppression |
| Antineutrophil antibody (ANA); anti-Ro/SSA, anti-La/SSB | Autoimmune diseases such as Sjogren's syndrome or systemic lupus erythematosus (SLE) |
| Estimated sedimentation rate (ESR) | Autoimmune diseases as mentioned above; nonspecific marker for systemic inflammation |
| Thyroid-stimulating hormone (TSH) | Elevated: toxic multinodular goiter Decreased: Hashimoto's thyroiditis, Graves' disease |
| Parathyroid hormone (PTH) | Parathyroid adenoma/hyperplasia or carcinoma |
| HIV enzyme-linked assay | HIV infection |
| Epstein-Barr virus (EBV) antibody titers | EBV infection |
| CMV IgM titer | CMV infection |
| Mantoux tuberculin test (PPD) | Mycobacterium tuberculosis infection |
| Bartonella titer | Bartonella infection (cat-scratch disease) |
| Thyroid ultrasound | Thyroid nodule, thyroid goiter Parathyroid adenoma |
| CT chest with contrast | Mycobacterium tuberculosis, nontuberculosis atypical mycobacterium, sarcoidosis, lung malignancy |
| Thyroglobulin FNA—needle wash assay | Thyroid cancer |

Abbreviations: CMV, cytomegalovirus; CT, computed tomography; FNA, fine-needle aspiration; PPD, purified protein derivative; WBC, white blood cell.

^aTests from this list should be chosen selectively, based on clinical suspicion. Ancillary testing should not delay workup of a possible malignancy.

- **Aggregate evidence quality:** Grade C, observational studies
- **Level of confidence in evidence:** High
- **Benefits:** Potentially identify a primary site of cancer or rule out malignancy, obtain tissue for diagnosis
- **Risks, harms, costs:** Direct costs of procedures, adverse effects of anesthesia, dental injury, cranial nerve injury, rare complications of endoscopy (bleeding, infection, perforation, airway obstruction)
- **Benefit-harm assessment:** Preponderance of benefit over harm
- **Value judgments:** Perception that some clinicians may be performing open biopsy of the neck before or without endoscopy during the same trip to the operating room and that endoscopy should preferably be performed prior to open biopsy
- **Intentional vagueness:** The decision to perform open biopsy is at the discretion of the clinician (after FNA has been performed and is not diagnostic) but is usually performed after the endoscopy if the endoscopy does not reveal a primary site and if a high suspicion for malignancy remains
- **Role of patient preferences:** Small. May decline intervention.
- **Exceptions:** Patients who are at increased risk of procedure (anesthesia)
- **Policy level:** Recommendation
- **Differences of opinion:** Within the GDG, there were differences of opinion about whether the surgeon should be prepared to do a neck dissection at the same time as an open biopsy and frozen section

Supporting Text

The purpose of this statement is to promote thorough evaluation of the upper aerodigestive tract and to reduce the incidence of open biopsy of neck masses prior to such evaluation. The panel recognizes that there is variability in this approach by clinicians and has focused the discussion on the broad concepts and strategies that have been advocated in the literature to identify a primary tumor.

In the setting of a persistent neck mass that has evaded diagnosis with repeated FNA, imaging, ancillary tests, and comprehensive physical examination, endoscopy under anesthesia with biopsies, if indicated, should be performed prior to open neck biopsy. Thorough evaluation of the upper aerodigestive tract under anesthesia may reveal a primary tumor site as the source of metastatic spread to the regional lymph node and thus obviate the need for and potential complications of an open neck biopsy. The reasons for attempting to avoid open neck biopsy, if possible, aside from known operative risks of bleeding, infection, and nerve injury, include the potential for higher rates of tumor seeding, wound sepsis and necrosis, local recurrence, and distant metastasis^{96,110} in patients undergoing open biopsy for malignancy. Patients with HPV-positive oropharyngeal HNSCC may not have the same poor outcomes because of the improved responsiveness of these tumors to modern therapy,^{52,53} but tumor seeding of the skin and neck compartments has been demonstrated with open biopsy of HPV-positive HNSCC.⁵²

Examination under anesthesia includes several techniques for identifying the primary tumor in the upper aerodigestive tract. First and foremost is deep palpation of sites that may be inaccessible in the office setting, including the base of tongue, tonsil

fossa, and posterior pharyngeal wall. This is complemented with visualization of all mucosal surfaces through operative laryngoscopy with the addition of nasopharyngoscopy, esophagoscopy, and bronchoscopy based on clinical judgement. Abnormal lesions can be biopsied with immediate frozen section tissue analysis, while directed biopsies of normal-appearing tissue may also be performed if there is a high level of suspicion of an upper aerodigestive tract primary. A recommendation for intensifying the primary tumor search in such manner prior to a confirmed malignancy diagnosis is beyond the scope of this document.

Open Biopsy

If all efforts—including repeated FNA, imaging, and examination of the upper aerodigestive tract under anesthesia—have failed to yield a diagnosis, an open biopsy may be required. This could be performed in the same setting as the examination under anesthesia, provided appropriate consent and patient engagement in the decision process. Some have advised that open biopsy be undertaken only after discussion with the patient about the possibility of proceeding to completion neck dissection during the same setting if the frozen section analysis indicated HNSCC. Regardless, for most masses, the incision for open biopsy should be planned so that it could be extended to a larger incision if a neck dissection might ever be performed.^{50,52,53,88,111,112} Excisional biopsy is preferable to prevent tumor spillage, especially with regard to cystic masses, but may not be feasible in cases of large, solid, or matted masses adherent to vital structures, where excisional techniques may increase the risk of bleeding and/or nerve injury.^{113,114}

Preoperative Patient Education

To support the patient physically and emotionally, the surgeon or his or her designee should provide patient-friendly information. This should include explanation of the rationale, risks, and benefits of surgery as well as discussion of the patient's expectations regarding management of postoperative pain. Patients should be encouraged to ask questions and to promptly inform the surgeon of unexpected symptoms that arise postoperatively. In a systematic review of preoperative education for cancer patients undergoing surgery, patients receiving preoperative education overall had increased satisfaction, increased knowledge, and, in some studies, reduced anxiety.¹¹⁵ Another systematic review that evaluated preoperative education in patients receiving orthopedic surgery reported reduced postoperative pain medication and increased self-efficacy.¹¹⁶ To facilitate patient education, the GDG has developed patient handouts explaining neck biopsy (**Table 8**) and examination of the upper aerodigestive tract under anesthesia (**Table 10**).

The patient should be encouraged to bring written questions as well as a support person to consultation appointments. The consultant may be proactive by providing patients and their caregivers answers to frequently asked questions. All test results should be explained simply and clearly. If cancer or other ominous diagnosis is made, the clinician should be aware that the patient may not be able to integrate all the information at one time, and the clinician should be receptive to multiple inquiries from the patient regarding his or her condition.

Research Needs

During the process of guideline development, several important gaps in knowledge were identified regarding the epidemiology and appropriate management of adult neck masses. The guideline recommendations would be strengthened with research seeking to clarify this information.

Several questions arose regarding the etiology and epidemiology of neck masses:

- What is the overall incidence of neck masses as a presenting symptom, for all diagnoses (including inflammatory masses)?
- What is the incidence of persistent neck masses (non-inflammatory)?
- How is the incidence of persistent neck masses expected to change as a result of increased incidence of HPV-positive HNSCC?
- What is the overall cost burden of evaluation and diagnosis of neck masses?
- What is the current length of delay in diagnosis of HNSCC presenting as a neck mass, and what is the impact of delay on outcomes?

Other questions arose regarding management issues:

- How long is too long in terms of the duration of a neck mass before workup is indicated? (The GDG, citing other literature, states that the period should be 2 weeks.)
- Does an FNA performed before CT scan interfere with appropriate radiology read of the neck mass?
- For cystic masses, are there any radiologic findings that can be identified that would lead to a higher suspicion for malignancy?
- What is the incidence of open biopsy, and what is the long-term impact on outcomes?

Implementation Considerations

The clinical practice guideline is published as a supplement to *Otolaryngology–Head and Neck Surgery*, which will facilitate reference and distribution. A full-text version of the guideline will be accessible, free of charge, at <http://www.entnet.org>. The guideline will be presented to AAO-HNSF members as a miniseminar at the 2017 AAO-HNSF Annual Meeting & OTO Experience. Existing brochures and publication by the AAO-HNSF will be updated to reflect the guideline's recommendations. As a supplement to clinicians, an algorithm of the guideline's action statements has been provided (**Figure 1**). The algorithm allows for a more rapid understanding of the guideline's logic and the sequence of the action statements. The GDG hopes that the algorithm can be adopted as a quick reference guide to support the implementation of the guideline's recommendations.

Disclaimer

The clinical practice guideline is provided for information and educational purposes only. It is not intended as a sole source of guidance in evaluating neck masses. Rather, it is designed

Table 10. Patient Handout: Examination under Anesthesia—What Should the Patient Expect.**What is examination (endoscopy) under anesthesia?**

Examination under anesthesia is performed by a surgeon to evaluate the back of your throat, voice box, the back of your nose, upper trachea (breathing tube), and upper esophagus (swallowing tube).

Why do I need an examination under anesthesia?

This test allows a complete evaluation of the back of your nose and throat, your voice box, the windpipe, and esophagus (swallowing tube). If your doctor sees an area of concern, he or she will take a small piece of tissue for evaluation (biopsy).

How is this examination performed?

Examination under anesthesia is performed in the operating room. You will be asleep with general anesthesia. A scope with attached camera is inserted through your mouth and into your throat, voice box, windpipe, and esophagus.

How will I feel after the procedure?

After general anesthesia, you may feel sleepy for a day. You will be able to eat and drink as you did before the procedure. You will receive medication for pain.

You may have the following symptoms:

- A sore throat lasting 1-2 days
- Hoarse voice
- Coughing or spitting up small amount of blood for 1-3 days

What are the risks of examination under anesthesia?

A risk is a problem that you might have.

Some risks include

- Reaction to anesthesia
- Bleeding that may recur where the tissue samples were taken
- Damage to teeth
- Swelling where tissue samples were taken may cause difficulty breathing
- Damage to the back of the throat or esophagus (swallowing tube)

When will I receive my results?

After the examination under anesthesia, your doctor will be able to tell you what he or she saw and if biopsies were taken. Biopsy results will take at least a few days, sometimes longer. Your doctor will call you or schedule a follow-up visit to review the biopsy results.

Call your doctor if you experience

- Severe bleeding or any bleeding >3 days
- Fever >101°F
- Inability to swallow
- Vomiting
- Difficulty breathing

to assist clinicians by providing an evidence-based framework for decision-making strategies. The guideline is not intended to replace clinical judgment or establish a protocol for all individuals with this condition and may not provide the only appropriate approach to diagnosing and managing this program of care. As medical knowledge expands and technology advances, clinical indicators and guidelines are promoted as conditional and provisional proposals of what is recommended under specific conditions but are not absolute. Guidelines are not mandates; these do not and should not purport to be a legal standard of care. The responsible clinician, in light of all circumstances presented by the individual patient, must determine the appropriate treatment. Adherence to these guidelines will not ensure successful patient outcomes in every situation. The AAO-HNSF emphasizes that

these clinical guidelines should not be deemed to include all proper treatment decisions or methods of care, or to exclude other treatment decisions or methods of care reasonably directed to obtaining the same results.

Acknowledgments

We gratefully acknowledge the support of Jean C. Blackwell, MLS, for conducting the literature searches, as well as graphic designer Jackie Cole for her work in creating some of the images within the guideline.

Author Contributions

Melissa A. Pynnonen, writer, chair; **M. Boyd Gillespie**, writer, assistant chair; **Benjamin Roman**, writer, assistant chair; **Richard M. Rosenfeld**, writer, methodologist; **David E. Tunkel**, writer,

methodologist in training; **Laura Bontempo**, writer, panel member; **Itzhak Brook**, writer, panel member; **Davoren Ann Chick**, writer, panel member; **Maria Colandrea**, writer, panel member; **Sandra A. Finestone**, writer, panel member; **Jason C. Fowler**, writer, panel member; **Christopher C. Griffith**, writer, panel member; **Zeb Henson**, writer, panel member; **Corinna Levine**, writer, panel member; **Vikas Mehta**, writer, panel member; **Andrew Salama**, writer, panel member; **Joseph Scharpf**, writer, panel member; **Deborah R. Shatzkes**, writer, panel member; **Wendy B. Stern**, writer, panel member; **Jay S. Youngerman**, writer, panel member; **Maureen D. Corrigan**, writer, AAO-HNSF staff liaison.

Disclosures

Competing interests: M. Boyd Gillespie—research funding from ImThera, Inspire, and Olympus; consultant and new device development for Medtronic and Omniguide; Maureen D. Corrigan—salaried employee of American Academy of Otolaryngology—Head and Neck Surgery Foundation.

Sponsorships: American Academy of Otolaryngology—Head and Neck Surgery Foundation.

Funding source: American Academy of Otolaryngology—Head and Neck Surgery Foundation.

Supplemental Material

Additional supporting information is available in the online version of the article.

References

- Olsen KD. Evaluation of masses in the neck. *Prim Care*. 1990;17:415-435.
- Beenken SW, Maddox WA, Urist MM. Workup of a patient with a mass in the neck. *Adv Surg*. 1995;28:371-383.
- Gray SW, Skandalakis JE, Androulakis JA. Non-thyroid tumors of the neck. *Contemp Surg*. 1985;26:13-24.
- Lefebvre JL, Coche-Dequeant B, Van JT, et al. Cervical lymph nodes from an unknown primary tumor in 190 patients. *Am J Surg*. 1990;160:443-446.
- Rosenberg TL, Brown JJ, Jefferson GD. Evaluating the adult patient with a neck mass. *Med Clin North Am*. 2010;94:1017-1029.
- Bhattacharyya N. Predictive factors for neoplasia and malignancy in a neck mass. *Arch Otolaryngol Head Neck Surg*. 1999;125:303-307.
- McGuirt WF. The neck mass. *Med Clin North Am*. 1999;83:219-234.
- Haynes J, Arnold KR, Aquirre-Osins D, Chandra S. Evaluation of neck masses in adults. *Am Fam Physician*. 2015;9:698-706.
- Urjeet AP, Brennan TE. Disparities in head and neck cancer: assessing delay in treatment initiation. *Laryngoscope*. 2012;122:1756-1760.
- Seoane J, Alvarez-Novoa P, Gomez I, et al. Early oral cancer diagnosis: the Aarhus statement perspective. A systematic review and meta-analysis. *Head Neck*. 2016;38(suppl 1):E2182-E2189.
- Seoane J, Taccouche B, Varela-Centelles P, Tomas I, Seoane-Romero JM. Impact of the delay in diagnosis in survival of head and neck carcinomas: a systematic review with meta-analysis. *Clin Otolaryngol*. 2012;37:99-106.
- Bruun JP. Time lapse by diagnosis of oral cancer. *Oral Surg Oral Med Oral Pathol Oral Radiol Endod*. 1976;42:139-149.
- McGurk M, Chan C, Jones J, et al. Delay in diagnosis and its effect on outcome in head and neck cancer. *Br J Oral Maxillofac Surg*. 2005;43:281-284.
- Smith MM. Assessing delays in laryngeal cancer treatment. *Laryngoscope*. 2016;126:1612-1615.
- Brouha XDR, Tromp DM, Koole R, et al. Professional delay in head and neck cancer patients: analysis of the diagnostic pathway. *Oral Oncol*. 2007;43:551-556.
- American Cancer Society. *Cancer Facts & Figures 2016*. Atlanta, GA: American Cancer Society; 2016.
- Chaturvedi AK, Engels EA, Pfeiffer RM, et al. Human papillomavirus and rising oropharyngeal cancer incidence in the United States. *J Clin Oncol*. 2011;29:4294-4301.
- Chaturvedi AK, Anderson WF, Lortet-Tieulent J, et al. Worldwide trends in incidence rates for oral cavity and oropharyngeal cancers. *J Clin Oncol*. 2013;31:4550-4559.
- Gillison ML, Broutian T, Pickard RKL, et al. Prevalence of oral HPV infection in the United States, 2009–2010. *JAMA*. 2012;307:693-703.
- Mallet Y, Lallemand B, Robin YM, et al. Cystic lymph node metastases of head and neck squamous cell carcinoma: pitfalls and controversies. *Oral Oncol*. 2005;41:429-434.
- Goldenberg D, Begum S, Westra WH, et al. Cystic lymph node metastasis in patients with head and neck cancer: an HPV-associated phenomenon. *Head Neck*. 2008;30:898-903.
- Haugen A, Alexander EK, Bible KC, et al. 2015 American Thyroid Association management guidelines for adult patients with thyroid nodules and differentiated thyroid cancer: the American Thyroid Association guidelines task force on thyroid nodules and differentiated thyroid cancer. *Thyroid*. 2016;26:1-133.
- National Comprehensive Cancer Network. *Clinical Practice Guideline in Oncology: Head and Neck Cancers*. Version 1. Fort Washington, PA: National Comprehensive Cancer Network; 2015.
- American Society of Clinical Oncology; Pfister DG, Laurie SA, Weinstein GS, et al. American Society of Clinical Oncology clinical practice guideline for the use of larynx-preservation strategies in the treatment of laryngeal cancer. *J Clin Oncol*. 2006;24:3693-704.
- National Institute for Health and Care Excellence. *Suspected Cancer: Recognition and Referral. Head and Neck Cancers*. London, UK: National Institute for Health and Care Excellence; 2015.
- Gleeson M, Herbert A, Richards A. Management of lateral neck masses in adults. *BMJ*. 2000;320:1521-1524.
- Torre LA, Bray F, Siegel RL, et al. Global cancer statistics, 2012. *CA Cancer J Clin*. 2015;65:87-108.
- Centers for Disease Control and Prevention. Vital signs: current cigarette smoking among adults aged ≥ 18 years—United States, 2009. *MMWR Morb Mortal Wkly Rep*. 2010;59:1135-1140.
- Gillison ML, D'Souza G, Westra W, et al. Distinct risk factor profiles for human papillomavirus type 16-positive and human papillomavirus type 16-negative head and neck cancers. *JNCI*. 2008;100:407-420.

30. Pytynia KB, Dahlstrom KR, Sturgis EM. Epidemiology of HPV-associated oropharyngeal cancer. *Oral Oncol.* 2014;50:380-386.
31. McIlwain WR, Sood AJ, Nguyen SA, et al. Initial symptoms in patients with HPV-positive and HPV-negative oropharyngeal cancer. *JAMA Otolaryngol.* 2014;140:441-447.
32. Garden AS, Kies MS, Morrison WH, et al. Outcomes and patterns of care of patients with locally advanced oropharyngeal carcinoma treated in the early 21st century. *Radiat Oncol.* 2013;8:21.
33. Lewis A, Kang R, Levine A, et al. The new face of head and neck cancer: the HPV epidemic. <http://www.cancernetwork.com>. Accessed June 11, 2017.
34. Hutcheson KA, Holsinger FC, Kupferman ME, et al. Functional outcomes after TORS for oropharyngeal cancer: a systematic review. *Eur Arch Otorhinolaryngol.* 2015;272:463-471.
35. Gallagher KK, Sacco AG, Lee JS-J, et al. Association between multimodality neck treatment and work and leisure impairment: a disease-specific measure to assess both impairment and rehabilitation after neck dissection. *JAMA Otolaryngol.* 2015;141:888-893.
36. Wopken K, Bijl HP, van der Schaaf A, et al. Development and validation of a prediction model for tube feeding dependence after curative (chemo-) radiation in head and neck cancer. *PLoS One.* 2014;9:e94879.
37. Hammerlid E, Silander E, Hörnemann L, et al. Health-related quality of life three years after diagnosis of head and neck cancer—a longitudinal study. *Head Neck.* 2001;23:113-125.
38. Allison PJ, Locker D, Wood-Dauphinee S, et al. Correlates of health-related quality of life in upper aerodigestive tract cancer patients. *Qual Life Res.* 1998;7:713-722.
39. Kugaya A, Akechi T, Okuyama T, et al. Prevalence, predictive factors, and screening for psychologic distress in patients with newly diagnosed head and neck cancer. *Cancer.* 2000;88:2817-2823.
40. Aarstad HJ, Aarstad AKH, Heimdal J-H, et al. Mood, anxiety and sense of humor in head and neck cancer patients in relation to disease stage, prognosis and quality of life. *Acta Otolaryngol.* 2005;125:557-565.
41. Aarstad AKH, Beisland E, Aarstad HJ. Personality, choice of coping and T stage predict level of distress in head and neck cancer patients during follow-up. *Eur Arch Otorhinolaryngol.* 2012;269:2121-2128.
42. Kam D, Salib A, Gorgy G, et al. Incidence of suicide in patients with head and neck cancer. *JAMA Otolaryngol.* 2015;141:1075-1081.
43. Koivunen P, Rantala N, Hyrynkanas K, et al. The impact of patient and professional diagnostic delays on survival in pharyngeal cancer. *Cancer.* 2001;92:2885-2891.
44. Teppo H, Koivunen P, Hyrynkanas K, et al. Diagnostic delays in laryngeal carcinoma: professional diagnostic delay is a strong independent predictor of survival. *Head Neck.* 2003;25:389-394.
45. Huang J, Barbera L, Brouwers M, et al. Does delay in starting treatment affect the outcomes of radiotherapy? A systematic review. *J Clin Oncol.* 2003;21:555-563.
46. Baishya N, Das AK, Krishnatreya M, et al. A pilot study on factors associated with presentation delay in patients affected with head and neck cancers. *Asian Pac J Cancer Prev.* 2015;16:4715-4718.
47. Tan JY, Otty ZA, Vangaveti VN, et al. A prospective comparison of times to presentation and treatment of regional and remote head and neck patients in North Queensland, Australia. *Intern Med J.* 2016;46:917-924.
48. Franco J, Elghouche AN, Harris MS, Kokoska MS. Diagnostic delays and errors in head and neck cancer patients: opportunities for improvement. *Am J Med Qual.* 2017;32:330-335.
49. Lee JJ, Dhepnorrarat C, Nyhof-Young J, Witterick I. Investigating patient and physician delays in the diagnosis of head and neck cancers: a Canadian perspective. *J Cancer Educ.* 2016;31:8-14.
50. Robbins KT, Cole R, Marvel J, et al. The violated neck: cervical node biopsy prior to definitive treatment. *Otolaryngol Head Neck Surg.* 1986;94:605-610.
51. Gourin CG, Johnson JT. Incidence of unsuspected metastases in lateral cervical cysts. *Laryngoscope.* 2000;110:1637-1641.
52. Zenga J, Graboyes EM, Haughey BH, et al. Definitive surgical therapy after open neck biopsy for HPV-related oropharyngeal cancer. *Otolaryngol Head Neck Surg.* 2016;154:657-666.
53. Loyo M, Johnson JT, Westra WH, et al. Management of the “violated neck” in the era of chemoradiation. *Laryngoscope.* 2011;121:2349-2358.
54. Goldenberg D, Sciubba J, Koch WM. Cystic metastasis from head and neck squamous cell cancer: a distinct disease variant? *Head Neck.* 2006;28:633-638.
55. Sira J, Makura ZGG. Differential diagnosis of cystic neck lesions. *Ann Otol Rhinol Laryngol.* 2011;120:409-413.
56. Rosenfeld RM, Shiffman RN, Robertson P, et al. Clinical practice guideline development manual, third edition: a quality-driven approach for translating evidence into action. *Otolaryngol Head Neck Surg.* 2013;148(1):S1-S55.
57. Shiffman RN, Michel G, Rosenfeld RM, Davidson C. Building better guidelines with BRIDGE-Wiz: development and evaluation of a software assistant to promote clarity, transparency, and implementability. *J Am Med Inform Assoc.* 2012;19:94-101.
58. Shiffman RN, Shekelle P, Overhage JM, et al. Standardized reporting of clinical practice guidelines: a proposal from the Conference on Guideline Standardization. *Ann Intern Med.* 2003;139:493-498.
59. Shiffman RN, Dixon J, Brandt C, et al. The GuideLine Implementability Appraisal (GLIA): development of an instrument to identify obstacles to guideline implementation. *BMC Med Inform Decis.* 2005;5:23.
60. Eddy DM. Clinical decision making: from theory to practice. Cost-effectiveness analysis: will it be accepted? *JAMA.* 1992;268:132-136.
61. American Academy of Pediatrics Steering Committee on Quality Improvement and Management. Classifying recommendations for clinical practice guidelines. *Pediatrics.* 2004;114:874-877.
62. Choudhry NK, Stelfox HT, Detsky AS. Relationships between authors of clinical practice guidelines and the pharmaceutical industry. *JAMA.* 2002;287:612-617.
63. Detsky AS. Sources of bias for authors of clinical practice guidelines. *Can Med Assoc J.* 2006;175:1033, 1035.
64. Fried MP. Neck mass. In: *Merck Manuals*. Kenilworth, NJ: Merck & Co Inc; 2016.
65. Schwetschenau E, Kelley DJ. The adult neck mass. *Am Fam Physician.* 2002;66:831-838.

66. Thandar MA, Jonas NE. An approach to the neck mass. *CME*. 2004;22:266-272.
67. Goffart Y, Hamoir M, Deron P, et al. Management of neck masses in adults. *B-ENT*. 2005;(suppl 1):133-140.
68. Gosche JR. Acute, subacute, and chronic cervical lymphadenitis in children. *Semin Pediatr Surg*. 2006;15:99-106.
69. Al-Dajani N, Wootton SH. Cervical lymphadenitis, suppurative parotitis, thyroiditis, and infected cysts. *Infect Dis Clin North Am*. 2007;21:523-541.
70. John DG, Anaes FC, Williams SR, et al. Palpation compared with ultrasound in the assessment of malignant cervical lymph nodes. *J Laryngol Otol*. 1993;107:821-823.
71. Sarvanan K, Bapuraj JR, Sharma SC, et al. Computed tomography and ultrasonographic evaluation of metastatic cervical lymph nodes with surgicoclinicopathologic correlation. *J Laryngol Otol*. 2002;116:194-199.
72. Thakur JS, Sharma ML, Mohan C, et al. Clinicopathological and radiological evaluation of cervical lymph node metastasis in head and neck malignancies. *Indian J Otolaryngol Head Neck Surg*. 2007;59:327-331.
73. Barakat M, Flood LM, Oswal VH, Ruckley RW. The management of a neck mass: presenting feature of an asymptomatic head and neck primary malignancy? *Ann R Coll Surg Engl*. 1987;69:181-184.
74. Wasson J, Amonoo-Kuofi K, Scrivens J, et al. Caliper measurement to improve clinical assessment of palpable neck lumps. *Ann R Coll Surg Engl*. 2012;94:256-260.
75. Epstein JB, Gorsky M, Cabay RJ, et al. Screening for and diagnosis of oral premalignant lesions and oropharyngeal squamous cell carcinoma: role of primary care physicians. *Can Fam Physician*. 2008;54:870-875.
76. Crozier E, Sumer BD. Head and neck cancer. *Med Clin North Am*. 2010;94:1031-1046.
77. Agrawal A, deSilva BW, Buckley BM, et al. Role of the physician versus the patient in the detection of recurrent disease following treatment for head and neck cancer. *Laryngoscope*. 2004;114:232-235.
78. Spiro RH. Cervical node metastasis from epidermoid carcinoma of the oral cavity and oropharynx: a critical assessment of current staging. *Am J Surg*. 1974;128:562.
79. Wang C-P, Ko J-Y, Lou P-J. Deep neck infection as the main initial presentation of primary head and neck cancer. *J Laryngol Otol*. 2006;120:305-309.
80. Soon SR, Kanagalingam J, Johari S, et al. Head and neck cancers masquerading as deep neck abscesses. *Singapore Med J*. 2012;53:840-842.
81. Coulter A, Ellins J. Effectiveness of strategies for informing, educating, and involving patients. *BMJ*. 2007;335:24-27.
82. Institute of Medicine. *Health Literacy: A Prescription to End Confusion*. Washington, DC: National Academies Press; 2004.
83. O'Connor AM, Stacey D, Entwistle V, et al. Decision aids for people facing health treatment or screening decisions. *Cochrane Database Syst Rev*. 2003;(2):CD001431.
84. Brook I. A piece of my mind: rediscovering my voice. *JAMA*. 2009;302:236.
85. Cianchetti M, Mancuso AA, Amdur RJ, et al. Diagnostic evaluation of squamous cell carcinoma metastatic to cervical lymph nodes from an unknown head and neck primary site. *Laryngoscope*. 2009;119:2348-2354.
86. Sham JS, Choy D, Wei WI, et al. Value of clinical follow-up for local nasopharyngeal carcinoma relapse. *Head Neck*. 1992;14:208-217.
87. Chisholm EJ, Lew-Gor S, Hajioff D, et al. Adenoid size assessment: a comparison of palpation, nasendoscopy and mirror examination. *Clin Otolaryngol*. 2005;30:39-41.
88. Strogan P, Ferlito A, Medina JE, et al. Contemporary management of lymph node metastases from an unknown primary to the neck: I. A review of diagnostic approaches. *Head Neck*. 2013;35:123-132.
89. Werner JA, Dünne AA, Myers JN. Functional anatomy of the lymphatic drainage system of the upper aerodigestive tract and its role in metastasis of squamous cell carcinoma. *Head Neck*. 2003;25:322-332.
90. Shaha AR, Rinaldo A, Ferlito A. Metastatic squamous carcinoma in the neck from an occult primary. In: Ferlito A, Robbins KT, Silver CE, eds. *Neck Dissection, Management of Regional Disease in Head and Neck Cancer*. San Diego, CA: Plural Publishing; 2010:307-317.
91. Wippold FJ II, Cornelius RS, Berger KL, et al; Expert Panel on Neurologic Imaging. *ACR Appropriateness Criteria: Neck Mass/Adenopathy*. Reston, VA: American College of Radiology; 2012.
92. Mettler FA, Huda W, Yoshizumi TT, et al. Effective doses in radiology and diagnostic nuclear medicine: a catalog. *Radiology*. 2008;248:254-263.
93. King AD, Vlantis AC, Bhatia KSS, et al. Primary nasopharyngeal carcinoma: diagnostic accuracy of MR imaging versus that of endoscopy and endoscopic biopsy. *Radiology*. 2011;258:531-537.
94. Kaewlai R, Abujudeh H. Nephrogenic systemic fibrosis. *AJR Am J Roentgenol*. 2012;199:W17-W23.
95. Robitschek J, Straub M, Wirtz E, et al. Diagnostic efficacy of surgeon-performed ultrasound-guided fine needle aspiration: a randomized controlled trial. *Otolaryngol Head Neck Surg*. 2010;142:306-309.
96. McGuirt WF, McCabe BF. Significance of node biopsy before definitive treatment of cervical metastatic carcinoma. *Laryngoscope*. 1978;88:594-597.
97. Tandon S, Shahab R, Benton JI, et al. Fine-needle aspiration cytology in a regional head and neck cancer center: comparison with a systematic review and meta-analysis. *Head Neck*. 2008;30:1246-1252.
98. Shah KSV, Ethunandan M. Tumour seeding after fine-needle aspiration and core biopsy of the head and neck—a systematic review. *Br J Oral Maxillofac Surg*. 2016;54:260-265.
99. Fleming MV, Oertel YC, Rodríguez ER, et al. Fine-needle aspiration of six carotid body paragangliomas. *Diagn Cytopathol*. 1993;9:510-515.
100. Abu-Yousef MM, Larson JH, Kuehn DM, et al. Safety of ultrasound-guided fine needle aspiration biopsy of neck lesions in patients taking antithrombotic/anticoagulant medications. *Ultrasound Q*. 2011;27:157-159.
101. Holmes BJ, Westra WH. The expanding role of cytopathology in the diagnosis of HPV-related squamous cell carcinoma of the head and neck. *Diagn Cytopathol*. 2014;42:85-93.
102. Hakima L, Adler E, Prystowsky M, et al. Hybrid Capture 2 human papillomavirus testing of fine needle aspiration

- cytology of head and neck squamous cell carcinomas. *Diagn Cytopathol*. 2015;43:683-687.
103. Sheahan P, Fitzgibbon J, O'Leary G, et al. Efficacy and pitfalls of fine needle aspiration in the diagnosis of neck masses. *J R Coll Surg Edinb*. 2004;2:152-156.
 104. Robinson IA, Cozens NJ. Does a joint ultrasound guided cytology clinic optimize the cytological evaluation of head and neck masses? *Clin Radiol*. 1999;54:312-316.
 105. Ganguly A, Burnside G, Nixon P. A systematic review of ultrasound-guided FNA of lesions in the head and neck—focusing on operator, sample inadequacy and presence of on-spot cytology service. *BJR*. 2014;87:20130571.
 106. Novoa E, Gürtler N, Arnoux A, et al. Role of ultrasound-guided core-needle biopsy in the assessment of head and neck lesions: a meta-analysis and systematic review of the literature. *Head Neck*. 2012;34:1497-1503.
 107. Seven H, Gurkan A, Cinar U, Vural C, Turgut S. Incidence of occult thyroid carcinoma metastases in lateral cervical cysts. *Am J Otolaryngol*. 2004;25:11-17.
 108. Kadhim AL, Sheahan P, Colreavy MP, et al. Pearls and pitfalls in the management of branchial cyst. *J Laryngol Otol*. 2004;118:946-950.
 109. Andrews PJ, Giddings CEB, Su AP. Management of lateral cystic swellings of the neck, in the over 40s' age group. *J Laryngol Otol*. 2003;117:318-320.
 110. Gooder P, Palmer M. Cervical lymph node biopsy—a study of its morbidity. *J Laryngol Otol*. 1984;98:1031-1040.
 111. Ellis ER, Mendenhall WM, Rao PV, et al. Incisional or excisional neck-node biopsy before definitive radiotherapy, alone or followed by neck dissection. *Head Neck*. 1991;13:177-183.
 112. Colletier PJ, Garden AS, Morrison WH, et al. Postoperative radiation for squamous cell carcinoma metastatic to cervical lymph nodes from an unknown primary site: outcomes and patterns of failure. *Head Neck*. 1998;20:674-681.
 113. Austin JR, Byers RM, Brown WD, et al. Influence of biopsy on the prognosis of cutaneous melanoma of the head and neck. *Head Neck*. 1996;18:107-117.
 114. Parsons JT, Million RR, Cassisi NJ. The influence of excisional or incisional biopsy of metastatic neck nodes on the management of head and neck cancer. *Int J Radiat Oncol Biol Phys*. 1985;11:1447-1454.
 115. Waller A, Forshaw K, Bryant J, et al. Preparatory education for cancer patients undergoing surgery: a systemic review of volume and quality or research output over time. *Patient Educ Couns*. 2015;98:1540-1549.
 116. Johansson K, Nuutila L, Virtanen H, et al. Preoperative education for orthopaedic patients: systematic review. *J Adv Nurs*. 2005;50:212-223.
 117. Howick J, Chalmers I, Glasziou, and the OCEBM Levels of Evidence Working Group. The Oxford 2011 levels of evidence. <http://www.cebm.net/index.aspx?o=5653>. Accessed July 23, 2012.